

7-1-2016

The Effect of Aloe Vera and Eucalyptol Oil on the Development of Tooth Germs in Albino Rats: A Histological and Histochemical Study

Noura Bakr

Demonstrator of Oral and Dental Biology, AL-Azhar University for Girls.

Heba Adawy

Associate Professor of Oral and Dental Biology Faculty of Dental Medicine, AL-Azhar University for Girls.

Marwa El sheikh

Lecturer of Oral and Dental Biology Faculty of Dental Medicine AL-Azhar University for Girls.

Follow this and additional works at: <https://azjd.researchcommons.org/journal>



Part of the [Other Dentistry Commons](#)

How to Cite This Article

Bakr, Noura; Adawy, Heba; and El sheikh, Marwa (2016) "The Effect of Aloe Vera and Eucalyptol Oil on the Development of Tooth Germs in Albino Rats: A Histological and Histochemical Study," *Al-Azhar Journal of Dentistry*. Vol. 3: Iss. 3, Article 5.

DOI: <https://doi.org/10.21608/adjg.2016.5087>

This Original Study is brought to you for free and open access by Al-Azhar Journal of Dentistry. It has been accepted for inclusion in Al-Azhar Journal of Dentistry by an authorized editor of Al-Azhar Journal of Dentistry. For more information, please contact yasmeenmahdy@yahoo.com.



The Effect of Aloe Vera and Eucalyptol Oil on the Development of Tooth Germs in Albino Rats: A Histological and Histochemical Study

Noura Mohammed Bakr⁽¹⁾, Heba Ahmed Adawy⁽²⁾ and Marwa Abdel Mohsen El sheikh⁽³⁾

Codex : 05/1607

dentaljournal.forgirls@yahoo.com

ABSTRACT

Tooth development or odontogenesis is a very complex process involving many growth factors and transcription factors of genes to ensure an ordered and controlled development of tooth germs. Increasing use of herbal remedies by mothers during pregnancy to avoid side effects of medical drugs may cause systemic and local effects on tooth development. In this study 50 pregnant rats were used, G1 control, GII eucalyptol oil vapour, GIII aloe vera. Offsprings were sacrificed at 1st day and 5th day, the specimens were obtained by serial sagittal sections and stained with (H&E) and Mercuric Bromophenol Blue (special stain). Administration of these herbal medicine during pregnancy result in adverse effects on tooth germ development of the offspring, delay tooth formation, change the thickness of the constituent layers of the teeth and disturbance and altered minerlization of enamel and dentin layers.

INTRODUCTION

Odontogenesis is a very complex process result from sequential and reciprocal interactions between the oral epithelium and neural crest-derived ectomesenchymal cells which promotes cellular differentiation, resulting in histogenesis and organogenesis.^[1,2] The continuous epithelial/mesenchymal interaction occurs during tooth development, making this organ one of the best models for differentiation and is an excellent subject for evolutionary studies.^[3] Herbs have been widely used in pregnancy and post-partum period to reduce the discomfort and to restore the body condition after delivery. In contrast to prescribed medications, most herbal products are marketed without going through

KEYWORDS

*Tooth Germ,
Development,
Eucalyptol Oil,
Aloe Vera,
Offspring Albino Rats.*

1. Demonstrator of Oral and Dental Biology, AL-Azhar University for Girls.
2. Associate Professor of Oral and Dental Biology Faculty of Dental Medicine, AL-Azhar University for Girls.
3. Lecturer of Oral and Dental Biology Faculty of Dental Medicine AL-Azhar University for Girls.

clinical trials to demonstrate either their efficacy or safety. ^[4]The effects of them may be transient, grave, or fatal. The fetus is in particular risk with herbs that may be teratogenic, carcinogenic or have toxic effect. ^[5]

Aloe vera and eucalyptol oil are widely used as a herbal medicine. Aloe vera has been used many years for its curative and therapeutic properties, It contains enzymes, vitamins, amino acids, fatty acids, Anthraquinones, minerals and hormones. ^[6,7] Pharmacological actions of aloe vera; Improve wound healing, Anti-inflammatory action^[8] Antioxidant & Anti-diabetic effects^[9] immunomodulatory effect,^[10] it also used in treatment of gingivitis,^[11] periodontitis^[12] beside the improvement of oral ulcers ^[13] and oral lichen ^[14]planus. It was reported that fractions prepared from fresh leaf and commercial Aloe vera gel extracts contained high levels of lectin-like substances as anthraquinones which is ascribed to be cytotoxic for human and animals. ^[15]There are numerous reports about stimulatory and inhibitory effects of Aloe vera lectin-like substances on cell proliferation reduced growth, diarrhea, and interference with nutrient absorption are caused by this class of toxicants. ^[16] Some cytogenetic studies showed that AV caused chromosomal damage which was expressed by mitotic index and chromosome aberrations. Many types of structural rearrangement of chromosomes have been identified in neoplastic cells, such as deletion duplication, inversion, insertion and translocation. Such rearrangement gives rise to loss, gain and relocation of genetic material. ^[17]

No previous researches evaluated the effect of aloe vera on tooth germs. Eucalyptol is widely distributed in plants spices mugwort, sweet basil, rosemary, sage, cardamom and their essential oils. ^[18] The main food sources are eucalyptus oil (up to 80% -95% eucalyptol) oil. It is related to the family of (2,3,7,8- tetrachlorodibenzo-para-dioxin). ^[19] Eucalyptol has been used to treat bronchitis, sinusitis, chronic rhinitis and also for the treatment of asthma. ^[20] These actions seem to be related to an

anti-inflammatory action,^[21] inhibiting the production of tumor necrosis factor alpha. ^[22] The oil also inhibits the production of cytokines and prostaglandins by stimulated monocytes *in vitro*, explaining its bronchodilator effect.^[23] (*Jehad M and Al-Hijazi A, 2011*) were done the study to evaluate the effect of the eucalyptol oil vapour on the palate and tooth germ development of rats embryos for the periods of (16th day ,18th day intrauterine life and one day old rats). Sagittal sections through the upper and lower jaws showed thickened of the oral epithelium. Rat embryo of 18 days intrauterine life subjected to the vapour synthetic eucalyptol oil as shown horseshoe-shaped dental arch with presences of primodium of tooth germ along the arch. Rat embryo of one day old subjected to the vapour synthetic eucalyptol oil showed apposition of hard tissue. Odontoblast cells showed to be not well be polarized and not well be arranged faced the developing dentin. The predentin showed to be wide, calcospherite can be detected. ^[19]

MATERIALS AND METHODS

Materials

- 1- Eucalyptol oil used in the form of ready-made preparation commercially known as (FlukaChemika, Sigma-Aldrich).
- 2- Aloe vera plant: Preparation according to Sasi-Kurmar, et al, 2013. ^[24]

Methods:

50 albino wistar female rats giving no birth previously and 20 albino wistar male rats. All animals were caged, and maintained under relative humidity 55± 0.5 and thermostatically regulated room temperature at 23±2°C to maintain cage hygiene and good ventilation. During the experimental period, the animals were fed solid rat chow and tap water ad libitum. First, the fertile period of the rats (also known as estrous cycle) was determined by the smear was taken from the vagina on a glass slide for microscopic examination.^[25] Once the fertile period

(estrus phase) was detected, the rats were isolated in individual cages; every two female were housed together with one male for mating during the night period. In the morning, the first day of pregnancy was determined by the presence of the vaginal plug.

After this, the pregnant rats were randomly divided into:

- 1- Ten pregnant rats were used as a control mother, which received normal ordinary diet.
- 2- The other forty pregnant rats were considered as experimental mothers, which were divided in two groups:
 - 1st group: consisted of twenty pregnant rats which received Eucalyptol oil inhalation vapour (120 MI oil in 250 ml boiling water) ^[19] for half an hour from one week of gestation till the delivery
 - 2nd group: consisted of the other twenty pregnant rats that received Aloe vera drink 200mg/kg. once daily^[26] by intraoral gavage from one week of gestation till the delivery. The offsprings which were delivered from the mothers, were classified as follows:

- **Control group:**

Group I (G I); consists of the offsprings which were delivered from the control mothers.

- **Experimental groups:**

Group II (G II); consists of ten offsprings which were delivered from the experimental mothers which received *Eucalyptol oil*. Group III (GIII); consists of ten offsprings which were delivered from the experimental mothers which received *Aloe vera*.

Each group (I, II and III) will be sub-divided into sub-groups according to the time of scarification as follows: ^[27]

- Subgroup A (D1); rats which were scarified at 1st day of delivery.

- Subgroup B (D2); rats which were scarified at 5th day of delivery.

The heads separated from the body taking sagittal planes in serial 5Mm thick histological section. The specimens were stained with Hematoxylin and Eosin stain and special stain (Mercuric Bromophenol Blue) stain to evaluate the total protein content.

RESULTS

Histological results

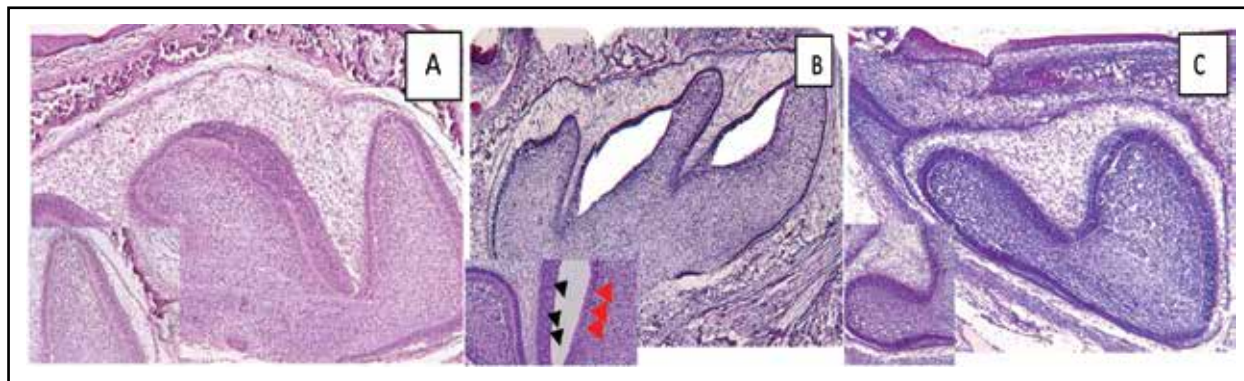
The tooth germ of the lower first molar at 1st day of GI appeared with the normal structure of development at the early bell stage, the outer enamel epithelium (OEE) appeared as continuous layer of cuboidal cells. The inner enamel epithelium (IEE) appeared as a single layer of tall columnar cells. The stellate reticulum appeared as several layers of widely scattered star shaped cells with long processes joining the cells together and they are separated by wide intercellular spaces. These layers of cells appear filling in the space between the (OEE) and (IEE). The stratum intermedium appeared as few layers of flattened cells, intervened between the inner enamel epithelium and stellate reticulum. Cervical loop is appeared in its developmental stage. Thin bone trabeculae are deposited in the fundus of bony crypt and extended to overlies the coronal portion of the tooth germ Fig(1 A), while in GII appeared in late bell stage but with variable morphological changes with separation of ameloblast from the underlying pre-dentin by the presence of cleft (sub-ameloblastic cyst), also loss of polarity and there were vacuolation between ameloblast and odontoblast cells, few and thin bone trabeculae. Stratum intermedium appeared clearly continuous in some areas and in other areas they showed reduction in number of cells or even being missed. The dental papilla revealed increased vascularity Fig (1 B). In GIII appeared in early bell stage showing delay in the normal developmental stages than control, all enamel organ cell layers showing delay in differentiation and organization there's dilation of blood vessels in dental papilla. Very thin loss of normal morphology of bony trabeculae Fig (1 C). At 5th day the tooth germ of GI

appeared in the advanced (late) bell stage. The pre-dentin, enamel matrix, dentin matrix was deposited along the crown and extended downward with obvious areas of enamel minerlization, development of epithelial root sheath of Hertwig. Well-developed bony trabaculæ. While in GII The enamel and dentin showed massive distortion in formation where there was uneven thickness of enamel and dentin layers all over the tooth, beside there was complete absence in certain areas. Arrest in root development. Irregular, thin and scattered bone trabeculæ. Increasing vascularity of dental papilla. In GIII the enamel matrix show increased thickness with no evidence of enamel maturation. The odontoblasts appeared normally arranged in pallisading manner, while in other areas showing thin dentin and enamel matrix, the odontoblasts revealed also some disturbance in its normal arrangement with even

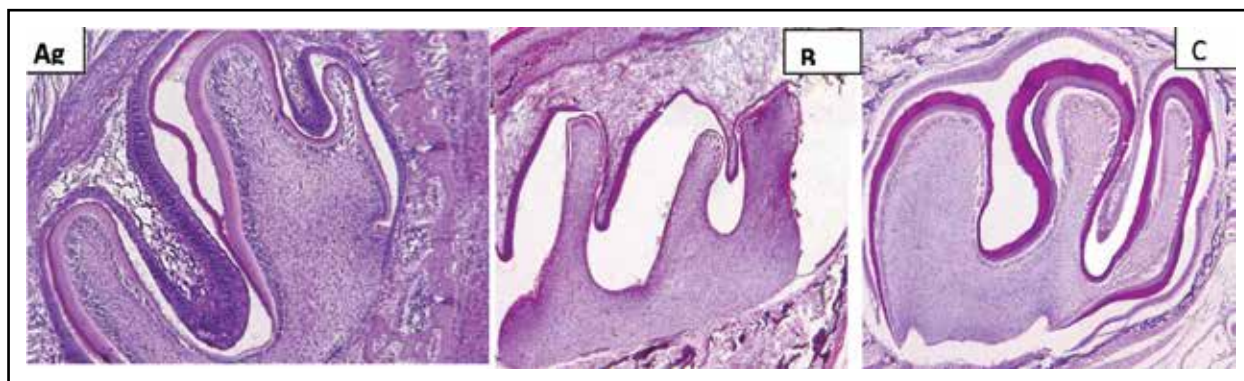
certain areas of odontoblast degeneration were seen. There is increased number of blood vessels in dental papilla, also the dental sac showed very thin bony trabeculæ surrounding the tooth germ Fig(1)

Histochemical result

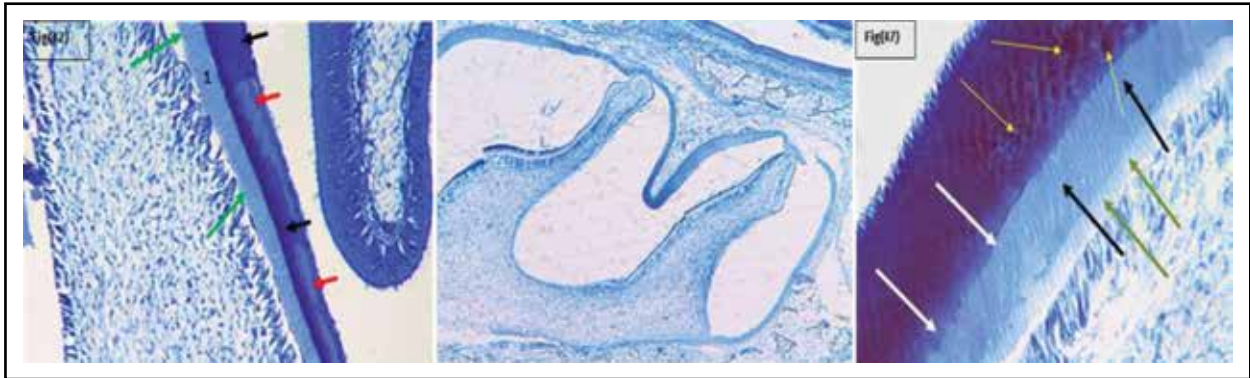
At 5th day the tooth germ of GI showed Strong reaction for total protein content in enamel matrix layer in some areas and moderate reaction in others. Moderate reaction in dentin layer, weak reaction in predentin layer. In GII D5 showing strong reaction for total protein content in enamel matrix layer. Moderate reaction in dentin layer, weak reaction in predentin layer. In GIII D5 strong reaction for total protein content in enamel matrix in spotted areas and less color density in other areas. Mild reaction in dentin. Week in predentin (fig 3)



Fig(1); A photomicrograph showing GI appeared at normal early bell stage(A) while in GII appeared in late bell stage but with variable morphological changes(B), in GIII in early bell stage showing delay in the normal developmental stage (C) (H&E, Orig. Mag x40)



Fig(2); A photomicrograph showing GI appeared at normal late bell stage(A) while in GII appeared in late bell stage but with variable morphological changes(B), in GIII in late bell stage with delay in mineralization)(H&E, Orig. Mag x100)



Fig(3); A photomicrograph showing GI showing strong reaction in enamel matrix in some areas (black arrow), moderate reaction in others (red arrow) moderate reaction for total protein content in dentin (1). Weak reaction in pre dentin (green arrow) (A) while in GII strong reaction for total protein content in enamel matrix. Moderate reaction in dentin. B), in GIII strong reaction for total protein content in enamel matrix in spotted areas (yellow arrow) and less color density in other areas (white arrow) . mild reaction in dentin(black arrow). Weak in pre dentin(green arrow) (C) (mercuric bromophenol blue, Orig. Mag x100)

DISCUSSION

As the dental hard tissues are not replaced once they have been formed, tooth is considered an informative organ model for studying abnormal mineralized tissue formation. Tooth development is genetically controlled but also susceptible to environmental disturbances. The effects not only depend on the chemical concerned and the dose/concentration but also the stage of tooth development at the time of exposure.^[28] As the eucalyptol belongs to the family of dioxin (2,3,7,8-tetrachlorodibenzo-para dioxin) (TCDD),^[19] Eucalyptol oil (as a chemical agent is ubiquitous environmental contaminants) has many adverse biological effects. Retardation in the tooth development suggested arrest of cell differentiation which may be related to poor interaction between mesenchymal cells and epithelial cells. Dioxin induce developmental defects that may be irreversible, and they are raising due to high exposure and possible greater sensitivity to infants.^[29] Vacuolation also appear in some areas at ameloblast and in odontoblast cells. Levenson G; 1976 suggested that, the vacuolation is responsible for the occurrence of some disturbance, possibly metabolic, in newly differentiated odontoblasts.^[30] prolonged exposure to eucalyptol (inhalation);

increases cerebral blood flow correlated with eucalyptol concentration in blood, suggesting a vasodilator action. This might explains the dilation of the blood vessels of dental papilla.^[19]

Subameloblastic cysts is caused by detachment of the ameloblasts from the underlying odontoblast cells.^[31,32,33] The detachment of the ameloblasts from the underlying surface seen in the present study was also seen in a study done by Larsson, 1974 where it was found that using diphosphonates causing cell disorganization and ultra- structurally there was fragmentation of the Tomes' processes of the ameloblasts. This may be one factor responsible for the exfoliation of the ameloblasts from the underlying surface and the formation of cyst like cavities.^[34] (GIII D1) causing delaying in tooth germ development compared with control group. This may be due to the cytotoxic effects of commercially prepared Aloe vera, this agree with a study done by Winters et al., 1981 to see the effect of commercially prepared Aloe vera gel on human normal and tumor cells in culture, it was suggested that these commercial preparations contain substances introduced during commercial processing which can alter the levels of lectin-like activities and can markedly disrupt the in vitro attachment and growth

of human cells. ^[15] The increase of vascularity and blood vessels of the dental papilla of tooth germ in both one and five postnatal days was due to the effect of aloe vera causing increase and re-establishing of blood vessels and angiogenesis (formation of new blood capillaries).^[8]

Some cytogenetic studies showed that AV caused chromosomal damage which was expressed by mitotic index and chromosome aberrations. ^[17] Many types of structural rearrangement of chromosomes have been identified in neoplastic cells, such as deletion, duplication, inversion, insertion and translocation. Such rearrangement gives rise to loss, gain and relocation of genetic material. In addition, numerical aberrations, giving rise to loss or gain of entire chromosomes, are common ^[35] this may be the cause of the enlargement of tooth germ at 5 day (GIII D5) more than that in control group as that increase which occurs in trisomy 21 causing tongue enlargement.^[43] In the aloe vera group at 5 day a delay in mineralization of enamel was found at the area of the cusp tip which agrees with the finding of Eisenmann et al 1984, who found that the Ca level were significantly reduced near the distal ends of the ameloblast following cobalt or fluoride injection (both of which temporarily inhibit enamel mineralization as compared with control ^[36]).

The histochemical examination showed, there was a noticeable increase in total protein content in the enamel matrix in some areas and there was a decrease in others areas in control group, so the staining of enamel matrix for total protein content was not homogenous, Bosky 1996 reported that the elimination of proteins from the calcified matrix denotes that there is an advanced event in mineralization. She found that proteins could inhibit de novo hydroxyapatite precipitation and conversion of calcium phosphate to hydroxyl apatite crystals.^[37] In aloe vera group the spotting found inside enamel matrix not obvious areas as in control denoting that delay in mineralization in this group compare to that

at the control group which agrees with the histological result of (H & E). The difference in the degree of protein content in the experimental groups may be explained by (Robinson, 2014) who found that, the maturation stage of enamel development comprises a secondary stage of mineral deposition during which apatite crystals, stage grow in width and thickness to replace fluid which had replaced the degraded protein matrix.

The time scale for the maturation process is hugely variable dependent on species, from 2 weeks to several years. 90–95% of the tissue volume is finally occupied by apatite crystals. As a result of changes in the enamel organ and the porosity of maturing enamel, extraneous materials can enter the tissue at this stage. Depending on the materials themselves and the duration of exposure, this can lead to delayed maturation and the eruption of white opaque dysplastic tissue. Enamel maturation is not only an important stage with regard to tissue development but also a very sensitive one in terms of hypomineralised enamel dysplasias.^[38]

REFERENCES

1. Zhang Y, Wang S, Song Y, Han J, Chai Y, Chen Y. Timing of odontogenic neural crest cell migration and tooth-forming capability in mice. *Dev Dyn* 2003;4:713-8.
2. Li Xiao. Human Stem Cells and Tooth Regeneration . *J Stem Cell Res Ther* 2012;2:1-2
3. Cobourne M, Sharp P. Making up the numbers: The molecular control of mammalian dental formula. *Semi Cell Dev Biol* 2010;21:314.
4. Shehata H. Drugs to avoid in pregnancy. *Current Obstetrics and Gynaecology*. 2000;10:44-52.
5. Little J. Complementary and alternative medicine: Impact on dentistry. *Oral Surg Oral Pathol Oral Radiol Endod*. 2004;98: 137-45.
6. Effect of Centrifuge Speed on Gel Extraction from Aloe Vera Leaves Chandegara VK and Varshney AK. *J Food Process Technol*. 2014, 5:1-6.
7. Balasubramanian J and Narayanan N .Aloe Vera: nature's gift, species of the month .2013, 2: 11-3.

8. Ahmad Oryan, Aboutorab T, Naeini Behrooz, Nikahval and Effa. Effect of aqueous extract of Aloe vera on experimental cutaneous wound healing in rat. *Vet. arhiv.* 2010; 80 :509-22.
9. Radha M Laxmipriya N/ Evaluation of biological properties and clinical effectiveness of Aloe vera: A systematic review. *Traditional J Complementary Med.* 2015; 5: 21-26.
10. Im S, Lee R, Lee H, Lee K, Park I, Lee S, et al. In vivo immunomodulatory activity of orally administered aloe vera gel. *Arch pharm res* 2010;33:451-6.
11. Ajmera n, Chatterjee A, Goyal V. Aloe vera - It's effect on gingivitis. *J Indian Soc Perio.* 2013, 17: 453-8.
12. Viridi H, Jain S, Sharma S. Effect of locally delivered aloe vera gel as an adjunct to scaling and root planing in the treatment of chronic periodontitis: A clinical study. *Indian J Oral Sci.* 2012, 3: 84-9.
13. Bhalang K, Thunyakitpisal P, and Rungsirisatean N. Acemannan, a Polysaccharide Extracted from Aloe vera, Is Effective in the Treatment of Oral Aphthous Ulceration. *Alter Complem J Medi.* 2013, 19: 429-34.
14. Amanat D, Najafi R, Tazaesh L. Effect of Aloe vera Gel Versus Local triamcinolone in Treatment of Oral Lichen Planus. *J Dent, Shiraz of Univ Med Sci.* 2011, 12:1-5.
15. Winters W, Benavides R, Clouse W. Effects of Aloe Extracts on Human Normal and Tumor Cells in Vitro. *Economic Botany.* 1981: 35; 89-95.
16. Abdelrawaf S, Al-Saady S1 and Attitalla I. Cytogenic Effects of Aloe vera (L.) Leaves Gel Extract on Mice Bone Marrow Cells. *World Appl. Sci. J.* , 2013;24 : 879-84.
17. Kayraldiz, A., Yavuzkocaman, E. Rencüzoullari, S. stifi H. Topakta M and Daliolu Y. The genotoxic and antigenotoxic effects of Aloe vera leaf extract in vivo and in vitro. *Turk J. Biol.* 2010 ;34: 235-46.
18. Angela S, and Davis L. Immune-Modifying and Antimicrobial Effects of Eucalyptus Oil and simple Inhalation Devices. *Altern. Med. Rev.* 2010,15:33-47.
19. Jehad M, Al- Hijazi A. Histological study of the effect of eucalyptol oil vapours on the development of the palate and tooth germ (experimental study on rats). *J Bagh College Dentistry.* 2011; 23: 61-6.
20. Juergens UR, Stöber M, Schmidt-Schilling L, Kleuver T, Vetter. Anti-inflammatory effects of eucalyptol (1,8-cineole) in bronchial asthma: inhibition of arachidonic acid metabolism in human blood monocytes ex vivo. *European J Med Res.* 1998;3: 407-12.
21. Santos FA & Rao VSN (2000). Anti-inflammatory and antinociceptive effects of 1,8-cineole a terpenoid oxide present in many plant essential oils. *Phytotherapy Res,* 14: 240-244.
22. Juergens UR, Stöber M & Vetter H. Inhibition of cytokine production and arachidonic acid metabolism by eucalyptol (1,8 cineole) in human blood monocytes in vitro. *European J Med Res.* 1998;3: 508-10.
23. Juergens U. Anti-inflammatory activity of 1,8-cineol (eucalyptol) in bronchial asthma: a double-blind placebo-controlled trial. *Respiratory Med.* 2003; 97:250- 6.
24. Sasi Kumar R, Ray R, Paul P, Suresh C. Development and Storage Studies of Therapeutic Ready to Serve (RTS) Made from Blend of Aloe vera, Aonla and Ginger Juice. *J Food Process Technol.* 2013, 4:1-5.
25. Goldman J, Murr A, and Cooper R. The Rodent Estrous Cycle: Characterization of Vaginal Cytology and Its Utility in Toxicological Studies. *Birth Defects Research (Part B)* 80:84-97 (2007)
26. Ghosha A, Banerjee M, Mandal B T, Mishra B, Bhowmik M. A Study on Analgesic Efficacy and Adverse Effects of Aloe Vera in Wistar Rats. *Pharmacology online.* 2011;1: 1098-108 .
27. Silva I, Leao J, Evêncio L, Porter S, de Castro R. Morphological analysis of the enamel organ in rats treated with fluoxetine. *CLINICS.* 2010;65:61-6 .
28. Salmela EA, Alaluusua S, Sahlberg C and Lukinmaa P. Tributyltin Impairs Dentin Mineralization and Enamel Formation in Cultured Mouse Embryonic Molar Teeth. *Toxicosci.* 2008;106: 214-22
29. Alaluusua S, Calderara P, Gerthoux P. Developmental Dental Aberrations After the Dioxin Accident in Seveso. *Environmental Health Perspectives.* 2004;112:1313-8.
30. Levenson G. Effect of ascorbic acid deficiency on mouse second molar tooth germs cultivated in vitro. *J. Embryol. exp. Morph.* 1976; 36: 73-85
31. Fouda N, Caracatsanis M and Hammarstrom L. Developmental disturbances of the rat molar induced by two diphosphonates. *Adv Dent Res.* 1989; 3:234-40.
32. Simmelink J and Lange A. Ultrastructure of altered rat enamel beneath fluoride-induced cysts. *Oral Pathol.* 1986, 15:155-61.
33. Lyaru D, Vermeulen L, Stienen N, Bervoets T, Den Besten P, and Bronckers A. Enamel pits in hamster molars, formed by a single high fluoride dose, are associated with a perturbation of transitional stage ameloblasts. *Caries Res.* 2012; 46: 575-80.

34. Larsson A. The short-term effects of high doses of ethylene-1-hydroxy-1, 1-diphosphonate upon early dentin formation. *Calc Tissue Res* .1974 ; 16, 109-27.
35. Boudreau, M.D.; Beland, F.A. An evaluation of the biological and toxicological properties of Aloe Barbadensis (Miller), Aloe vera. *J. Environ. Sci. Health C*. 2006, 24, 103-54
36. Köken R, Bükülmez A, Köken G, Eser B, Samlı H, Demir T, Solak M. Double Aneuploidy: A Case of Trisomy 21 with XYY. *Eur J Gen Med* 2011;8:338-4144- Eisenmann d, Ashrafi s, Zaki A. Calcium distribution in freeze-dried enamel organ tissue during normal and altered enamel mineralization. *Calcif tissue int* 1984 , 36 : 596-603
37. Boskey AL. Matrix proteins and mineralization. *Connect Tissue Res* 1996; 35: 357–63.
38. Robinson C. Enamel maturation: a brief background with implications for some enamel dysplasias. *Frontiers in Physiology*. 2014;5:388.