

1-1-2017

Guided Bone Regeneration Around Titanium Implants With Various Hydroxyapatite Particles In Surgically Created Defect. An Experimental Study

Hend Mohamed

Dentist at Ministry of Health

Eatemad Shoreibah

Professor and Head of Oral Medicine, Periodontology, Diagnosis and Radiology Department, Faculty of Dental Medicine for girls Al-Azhar University.

Mohamed Abd El Hamid

Professor of Surgery, Anesthesia and Radiology, Faculty of Veterinary Medicine, Cairo University

Mai Mansour

Associate professor of Oral Medicine, Periodontology, Diagnosis and Radiology, Faculty of Dental Medicine for girls Al- Azhar University.

Follow this and additional works at: <https://azjd.researchcommons.org/journal>



Part of the [Other Dentistry Commons](#)

How to Cite This Article

Mohamed, Hend; Shoreibah, Eatemad; Abd El Hamid, Mohamed; and Mansour, Mai (2017) "Guided Bone Regeneration Around Titanium Implants With Various Hydroxyapatite Particles In Surgically Created Defect. An Experimental Study," *Al-Azhar Journal of Dentistry*. Vol. 4: Iss. 1, Article 6.

DOI: <https://doi.org/10.21608/adjg.2017.5194>

This Original Study is brought to you for free and open access by Al-Azhar Journal of Dentistry. It has been accepted for inclusion in Al-Azhar Journal of Dentistry by an authorized editor of Al-Azhar Journal of Dentistry. For more information, please contact yasmeenmahdy@yahoo.com.



Guided Bone Regeneration Around Titanium Implants With Various Hydroxyapatite Particles In Surgically Created Defect. An Experimental Study

Hend M. Mohamed ⁽¹⁾, Eatemad A. Shoreibah⁽²⁾, Mohamed A. Abd El Hamid ⁽³⁾ and Mai S. Mansour⁽⁴⁾

Codex : 06/1701

dentaljournal.forgirls@yahoo.com

ABSTRACT

Objective: This study was designed to evaluate the effect of various types of Hydroxyapatite, Nano- hydroxyapatite, Micro-hydroxyapatite and mixed hydroxyapatite particles as a bone substitute in the treatment of experimental induced surgical defects around dental implants. **Materials and methods:** Eight healthy adult male experimental dogs were subjected to surgical removal of the third mandibular premolar (P3) bilaterally then received immediate implants in the fresh sockets where surgical defects were created distal to each implants and filled randomly with Nano-Hydroxyapatite, Micro-Hydroxyapatite and Mixed Hydroxyapatite particles. The defects were randomly divided into four groups according to the received type of Hydroxyapatite particles as follows: **Group I (GI):** eight surgically created defects without any adding bone grafts. **Groups II (GII):** eight surgically created defects which treated with Hydroxyapatite of Nano-sized particles. **Group III (GIII):** eight surgically created defects which treated with Hydroxyapatite of Micro-sized particles. **Group IV (GIV):** eight surgically created defects which treated with mixture of Nano-sized and Micro-sized Hydroxyapatite particles. **Result:** Histomorphometric analysis using H&E stains revealed that, the greatest mean value of area percent was recorded in Group II (Nano hydroxyapatite bone graft) (31.39 ± 1.6), whereas the lowest mean value was recorded in group I (No bone graft was added) (3.78 ± 0.62). ANOVA test revealed a significant difference between all groups at 2 months ($P < 0.0001$). Masson Trichrome stain showed that The greatest value of mean area percent of collagen fibers was recorded in Group IV (Mixture of Nano hydroxyapatite and Micro hydroxyapatite bone graft) (23.5 ± 6.08), while the lowest value of mean area percent of collagen fibers was recorded in group I (in which there was no bone graft added) was (10.965 ± 3.348). ANOVA test, revealed statistically significant difference in mean value of area percent of collagen fibers upon compar-

KEYWORDS

Implants, Osseointegration, Hydroxyapatite, surgically created defects

1. Dentist at Ministry of Health.
2. Professor and Head of Oral Medicine, Periodontology, Diagnosis and Radiology Department, Faculty of Dental Medicine for girls Al-Azhar University.
3. Professor of Surgery, Anesthesia and Radiology, Faculty of Veterinary Medicine, Cairo University.
4. Associate professor of Oral Medicine, Periodontology, Diagnosis and Radiology, Faculty of Dental Medicine for girls Al-Azhar University.

ing all groups at 2 months ($P < 0.0001$). However Orcein stain in Group I (in which there was no bone graft added) recorded the highest value of mean area percent of elastic fibers (10.515 ± 1.428) and Group II (Nano hydroxyapatite) which recorded the minimum value of mean area percent (3.922 ± 1.293). ANOVA test, revealed that the difference between all groups was statistically significant regarding mean value of area percent of elastic fibers at 2 months. **Conclusion:** Various types of hydroxyapatite used, promoted comparable newly formed tissues over the entire extension of the surgically created defects, independently of their granular size, thus confirming their biological osteoconductive property.

INTRODUCTION

The ultimate goal of modern dentistry is to restore the stomatognathic system to normal function, comfort, esthetics, speech and health regardless of the atrophy, disease or injury. However, the more the number of teeth is missing in a patient, the more difficult this goal becomes with traditional dentistry. As a result of continued research in dental implant designs, materials and techniques, predictable success is now a reality for the rehabilitation of many challenging clinical situations^(1,2).

Dental implants are inert, alloplastic materials made from titanium embedded in the maxilla and/or mandible for the management of tooth loss and to aid in replacement of lost orofacial structures as a result of trauma, neoplasia and congenital defects. The most common type of dental implant is endosseous comprising a discrete, single implant unit (screw- or cylinder-shaped are the most typical forms) placed within a drilled space within dentoalveolar or basal bone. The implants have become an important therapeutic modality in the last decade, mainly after the studies, in which the direct contact between the bone functional tissues and the biomaterial titanium was termed osseointegration^(3,4).

Placement of bone grafts or other biomaterials in surgical defects adjacent to oral implants should promote osseointegration and improve adjacent soft tissue esthetics. Autologous bone has a long history of use and is considered the gold standard for graft materials⁽⁵⁾.

Several treatment modalities have been recommended for the management of surgically created defects. Although the clinical outcomes of nonsurgical therapy have been reported, there is no reliable evidence suggesting its effectiveness in treating deep surgically created defects. Therefore, surgical intervention may provide better access and may allow further therapies to change the peri-implant tissue morphology, to establish the site during the healing phase, or to promote the regeneration of bone⁽⁶⁾.

Regenerative treatment modalities have been extensively investigated using bone grafts for regeneration in surgically created defects around dental implants^(7,8). Therefore, synthetic biomaterials are being developed⁽⁹⁾. Of the synthetic biomaterials, amorphous calcium phosphate and Micro Macroporous biphasic calcium phosphate show promise as bone substitutes in bone regeneration^(10,11).

Hydroxyapatites (HAs) represent a family of bone grafting materials with a high degree of biocompatibility, which is largely attributable to its presence in natural calcified tissue. HA, $\text{Ca}_{10}(\text{PO}_4)_6(\text{OH})_2$, is a calcium phosphate-based bioceramic material that makes up the majority of the inorganic components of human bones and teeth. The HA bone-grafting materials exhibited decreased osteoconductivity and poor degradation characteristics⁽¹²⁾.

The healing after treatments with these graft materials evidenced a long junctional epithelium with only a limited regenerative potential^(13,14). In pursuit of improving these shortcomings, a novel fully synthetic nanocrystalline hydroxyapatite (NHA) has been introduced for augmentation procedures in osseous defects⁽¹⁵⁾. NHA, containing about 65% water and nanoscopic apatite particles (35%) in aqueous dispersion, has been recommended for augmentation procedures in osseous defects⁽¹⁶⁾. In particular, experimental animal studies have pointed to an undisturbed osseointegration and complete resorption

of the material within 12 weeks. Owing to its specific physicochemical properties, NHA is intended to be used without the additional application of a barrier membrane⁽¹⁷⁾.

MATERIALS AND METHODS

Eight healthy adult male experimental dogs. Each dog received two mandibular implants bilaterally and defects were created distal to each implant and treated with various hydroxyapatite particles.

Experimental design

All the experimental dogs were subjected to surgical removal of the third mandibular premolar (P3) bilaterally then received immediate implants in the fresh sockets where surgical defects were created distal to each implants and filled randomly with various hydroxyapatite particles.

The defects were divided randomly into four groups according to the received type of Hydroxyapatite particles as follows:

Group I (GI): Eight surgically created defects without any adding bone grafts.

Groups II (GII): Eight surgically created defects which treated with Hydroxyapatite of Nano-sized particles.

Group III (GIII): Eight surgically created defects which treated with Hydroxyapatite of Micro-sized particles.

Group IV (GIV): Eight surgically created defects which treated with mixture of Nano-sized and Micro-sized Hydroxyapatite particles.

Steps of operative procedure:

Surgical procedure

After anesthesia disinfecting the surgical site of the animal was done using sterile cotton pellet wet with povidine-iodine (Betadine) 7.5%, buccal and lingual intra-sulcular incisions were performed

from the mesial of third premolar P3 to the mesial of the fourth mandibular premolar P4 then Mucoperiosteal full thickness flaps were reflected just to disclose the marginal aspect of the ridge in order to facilitate the tooth extraction.

Based on the amount of available bone measured with a periodontal probe on the extracted root, the implant osteotomies were drilled. The drilling sequence used was the 2.0 and 2.5mm twist drills to the expected depth of the osteotomy and a final 3.0mm diameter drill through only the coronal half of the osteotomy. Surgical cavities were irrigated with normal saline solution to wash away any debris.

Once the implants (11mm length and 3.4mm diameter) were inserted and primary stability was attained, surgical defects were made using a 5 mm trephine bur with a profuse irrigation and cleaning were performed to eliminate debris from the preparation, the defects were 5 mm in width and 7 mm in length, measured with a periodontal probe, then bone graft was applied. Finally, mucoperiosteal flaps were replaced and secured with resorbable interrupted sutures (Vicryls 4.0).

RESULTS

1. Descriptive histology

Group I (surgically created defects without any adding bone graft) (Control group)

H &E stain, revealed a relatively wide space surrounded by areas of fibrous as well as bony tissues especially at the base and periphery of the defects. The central area was devoid of any newly formed tissues either fibrous or bony fig (1). While Masson trichrome stain revealed that the collagen in some areas was closely condensing which have been seen by a deep blue color throughout the bony trabeculae which have been seen by a deep red color. Orcein stain showed orceinophilic (dark brownish–purple) foci dispersed in small linear and round dots.

Group II (surgically created defects treated with Nano-hydroxyapatite)

H &E stain, showed multiple spaces that have been subdivided by fibrillar and bony structures. Irregular pattern of bony trabeculae as well as connective tissue fibers with varying degree of density were seen fig (1). However Masson trichrome stain revealed that collagen in some areas was closely intertwining showing condensing fibrils which have been seen by a deep blue color throughout irregular bony trabeculae which have been seen by a deep red color. Orcein stain showed orceinophilic (dark brownish –purple) foci scattered diffusely in small dots with haphazard distribution, particularly around the vascular spaces.

Group III (surgically created defects treated with Micro-hydroxyapatite)

H&E stain revealed the persistence of extensively wide spaces in the partially healed defect.

These spaces were seen to be surrounded with fibrous tissue formation and newly formed bone fig (1). Masson trichrome stain revealed that collagen in some areas was closely condensing which have been seen by a deep blue color throughout the fused bony trabeculae which have been seen by a deep red color. Orcein stain showed orceinophilic (dark brownish –purple) foci scattered diffusely in small dots with haphazard distribution, particularly around the vascular spaces.

Group VI (surgically created defects treated with mixture of Nano- and Micro-hydroxyapatite)

H &E stain revealed that almost all defect had been filled with zones of new bone and condensing fibrillar connective tissues which enveloped the periphery of defects fig(1). Masson trichrome stain revealed that collagen in some areas was closely condensing which have been seen by a deep blue color surrounding the fused bony trabeculae which

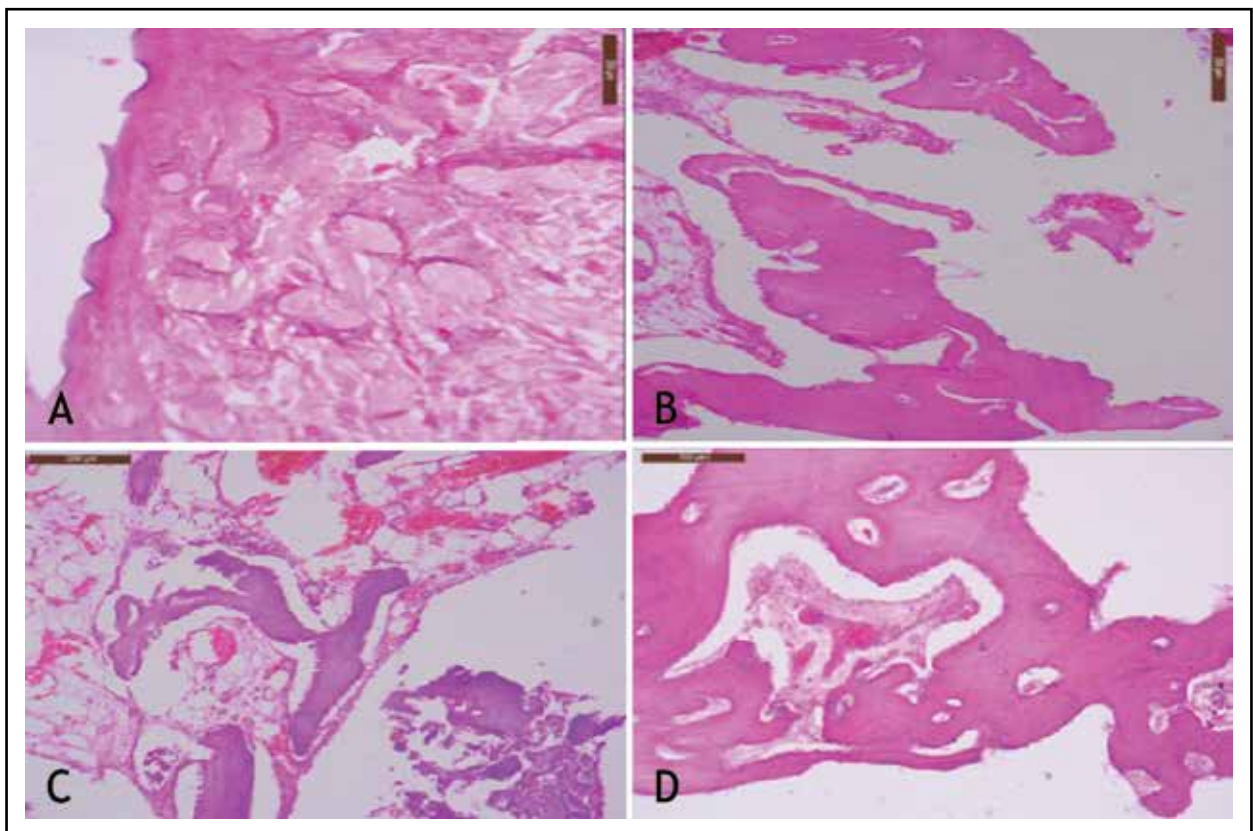


Fig.(1) showed H&E stain in: A) Group I, B) Group II, C) Group III & D) Group VI (x100).

have been seen by a deep red color. Orcein stain showed orceinophilic (dark brownish –purple) foci dispersed in small dots throughout the fibrous tissues and around the vascular spaces.

2. Histomorphometric analysis

Histomorphometric analysis using H&E stains revealed that The greatest mean value of area percent was recorded in Group II (Nano hydroxyapatite bone graft) (31.39 ± 1.6), whereas the lowest mean value was recorded in group I (No bone graft was added) (3.78 ± 0.62). One way analysis of variance (ANOVA) test, revealed a significant difference between all groups at 2 months ($P < 0.0001$). While Masson Trichrome stain showed that The greatest value of mean area percent of collagen fibers was recorded in Group IV (Mixture of Nano hydroxyapatite and Micro hydroxyapatite bone graft) (23.5 ± 6.08). While the lowest value of mean area percent of collagen fibers was recorded in group I (in which there was no bone graft added) was (10.965 ± 3.348). One way analysis of variance (ANOVA) test, revealed statistically significant difference in mean value of area percent of collagen fibers upon comparing all groups at 2 months ($P < 0.0001$). However Orcein stain in Group I (in which there was no bone graft added) recorded the highest value of mean area percent of elastic fibers (10.515 ± 1.428) and Group II (Nano hydroxyapatite) which recorded the minimum value of mean area percent (3.922 ± 1.293). One way analysis of variance (ANOVA) test, revealed that the difference between all groups was statistically significant regarding mean value of area percent of elastic fibers at 2 months.

Overall Correlation in all groups

A weak negative overall correlation between mean value of area percent of collagen fibers in Masson Trichrome stain and mean value of area percent of elastic fibers in Orcein stain in all groups together ($R = -0.0978$, $R^2 = 0.0096$), was revealed by Pearson correlation test.

DISCUSSION

Nano-hydroxyapatite is bioactive materials that can integrate well with living bone tissues by spontaneously forming a biologically active bone-like apatite layer on their surface. Hydroxyapatite (HA) is the main mineral constituent of teeth and bones. HA ceramics do not exhibit any cytotoxic effects. They show excellent biocompatibility with hard tissues, skin and muscle tissues⁽¹⁸⁾. HA is a useful alternative to autogenous bone grafts in orthopedic, dental and maxillofacial applications, due to its chemical and structural similarity to the mineral component of bone⁽¹⁹⁾.

In this study, hydroxyapatite had been chosen in treatment of surgically created defects. Hydroxyapatite is the main inorganic mineral composition of animals and human bone; considerable clinical research has shown that HA repairs periodontal bone defect and has a particular clinical effect^(20,21). From the histological perspective, HA only leads mature osteogenesis cell growth, guides cells in lesions on root, forms new bone and osseous adhesion, and causes root surface absorption, however, it does not physically form new teeth attachment, and the long-term outcome is not ideal⁽²²⁾.

Interestingly, Nano-HA may offer a new approach for inducing periodontal cell differentiation. Where the size of HA at the nanometer level shows a series of unique performance, it possesses the characteristics of nanomaterials; Nano-HA has good biocompatibility and wide application prospect in the biomedical field⁽²³⁾. Many studies have shown that Nano-HA increases the protein synthesis of periodontal cells, improves the activity of alkaline phosphatase, induces cell differentiation, effectively promotes periodontal tissue regeneration and formation of new teeth attachments⁽²⁴⁻²⁷⁾.

Owing to its osteoconductive capacity, HA serves as a structural scaffold for the building of new bone tissue. The scaffold itself should be completely degradable, as remnants could affect the mechanical

properties of reconstructed bone negatively and, as non-self, may induce inflammation. It is desirable for scaffold degradation to take place during the regular bone remodeling processes⁽²⁸⁾. The extent and distribution of the remodeling of bone substitutes are influenced by the quality of the host site and the local mechanical environment⁽²⁹⁾.

In addition, the biodegradation of HA scaffolds may take place by dissolution or fragmentation with subsequent phagocytosis by macrophages⁽³⁰⁾, but also by the activity of osteoclasts⁽³¹⁻³⁴⁾. The latter mechanism of biodegradation is favorable⁽³⁵⁾, because mimicry of the physiological bone processes should create optimal surfaces for colonization with osteoblasts and vascular tissue. The degree of osteoclast activity on HA scaffolds depends on material qualities such as crystal size^(36, 37), and surface roughness⁽³⁸⁾. Macro-crystalline HA is not degradable by osteoclasts^(39, 40), but Micro-crystalline HA may also escape resorption, if the biomaterials were sintered during production⁽⁴¹⁾.

In conclusion, the use of hydroxyapatite bone graft in treatment of surgically created defects resulted in favorable histological changes. The histologic and histomorphometric results were parallel and support one another. Group II in which Nano-hydroxyapatite was applied demonstrated superior results than group III in which Micro-hydroxyapatite was applied and group IV in which mixed hydroxyapatite was applied. This could be attributed to the physical and chemical properties of Nano-hydroxyapatite that facilitates the participation of progenitor cells in bone regeneration.

CONCLUSION

1. Various types of hydroxyapatite used, promoted comparable newly formed tissues over the entire extension of the surgically created defects, independently of their granular size, thus confirming their biological osteoconductive property.

2. Defects treated with Nano-hydroxyapatite showed the highest mean area percent of newly formed bone than these treated with Micro-hydroxyapatite or mixed hydroxyapatite
3. Defects treated with mixed hydroxyapatite showed greater amount of mean area percent of newly formed collagen fibers than these treated with Nano-hydroxyapatite or Micro-hydroxyapatite

REFERENCES

1. Misch CE. Contemporary Implant Dentistry. 3rd ed. St. Louis: Mosby Publications; 2007; 1:22-90.
2. Babbush CA. Dental Implants: The Art and Science. 1st ed. Philadelphia: WB Saunders Company; 2001; 2:88-100.
3. Hadi SA, Ashfaq N, and Bey . Biological factors responsible for failure of osseointegration in oral implants. *Biology and Medicine* 2011; 3 : 164-70.
4. Adell R, Lekholm U, Rockler B, and Branemark PI. A 15-year study of osseointegrated implants in the treatment of the edentulous jaw. *Int J Oral Surg* 1981; 10:387-416.
5. Goldberg V, and Stevenson S. Natural history of autografts and allografts. *Clin Orthop Related Res* 1987; 22:7-16.
6. Mombelli A, Moene R, and Decaillet F. Surgical treatments of peri-implantitis. *Eur J Oral Implantol* 2012; 5 (Suppl):S61-S70.
7. Rosen PS, Reynolds MA, and Bowers GM. The treatment of intrabony defects with bone grafts. *J Periodontol* 2000; 22:88-103.
8. Christian T, Safwan S, Michael T, Philipp S, Wilhelm NF, and Emeka N. Bone regeneration in osseous defects – application of particulated human and bovine materials. *Oral Surg Oral Med Oral Pathol Oral Radiol Endod* 2008; 105:430-6.
9. Yukna RA. Synthetic bone grafts in periodontics. *J Periodontolo* 1993; 1:92-9.
10. Gauthier O, Goyenvalle E, Boulter JM, Guicheux J, Pilet P, Weiss P, and Daculsi G. Macroporous biphasic calcium phosphate ceramics versus injectable bone substitute: a comparative study 3 and 8 weeks after implantation in rabbit bone. *J Materials Sci Mater Med* 2001; 12:385-90.

11. Lee IS, Zhao B, Lee GH, Choi SH, and Chung SM. Industrial application of ion beam assisted deposition on medical implants. *Surface and Coatings Technology* 2007; 201:5132–7.
12. Meffert RM, Thomas JR, Hamilton KM, and Brownstein CN. Hydroxylapatite as an alloplastic graft in the treatment of human periodontal osseous defects. *J Periodontol* 1985; 56:63–7.
13. Froum SJ, Kushner L, Scopp IW, and Stahl SS. Human clinical and histologic responses to durapatite implants in intraosseous lesions. Case reports. *J Periodontol* 1982; 53:719–25.
14. Moskowitz BS, and Lubarr A. Histological assessment of human periodontal defect after durapatite ceramic implant. Report of a case. *J Periodontol* 1983; 54:455–62.
15. Bezrukov VM, Grigor'iants LA, Zuev VP, and Pankratov AS. The surgical treatment of jaw cysts using hydroxyapatite with an ultrahigh degree of dispersity. *Stomatologiya (Mosk)* 1998; 77:31–5.
16. Moghadam HG, Sandor GK, Holmes HH, and Clokie CM. Histomorphometric evaluation of bone regeneration using allogeneic and alloplastic bone substitutes. *J Oral Maxillofac Surg* 2004; 62:202–13.
17. Chris AJJ, Verdonschot N, Schreurs BW, and Buma P. The use of a bioresorbable nano-crystalline hydroxyapatite paste in acetabular bone impaction grafting. *Biomaterials* 2006; 27:1110–8.
18. Goldman MJ. Bone regeneration around an failing implant using guided bone regeneration. A case report. *J Periodontol* 1992; 63:473–6.
19. Fathi MH, Mortazavi V, and Esfahani SIR. Bioactivity Evaluation of synthetic Nanocrystalline Hydroxyapatite. *J Dent Res* 2008; 5: 81–7.
20. Golec TS. Clinical use of hydroxyapatite to augment the atrophic maxilla and mandible. *J Oral Implantol* 1984; 11: 487–99.
21. Nawawi A, Alqap SF and Sopyan I. The effects of calcium excess, water amount and mixing time on the injectability of calcium phosphate filling materials. *Recent patents on materials science* 2011; 4:63.
22. Gu SJ, Sohn JY and Lim HC. The effects of hydroxyapatite-Chitosan membrane on bone regeneration in rat calvarial defects. *J Korean Academy Periodontol* 2009; 39: 321–9.
23. Carlo Reis EC, Borges AP and Del Carlo RJ. Guided tissue regeneration using rigid absorbable membranes in the dog model of chronic furcation defect. *Acta Odontol Scand*. 2013; 71: 372.
24. Lee JS, Park WY, and Cha JK. Periodontal tissue reaction to customized nano-hydroxyapatite block scaffold in one-wall intrabony defect: a histologic study in dogs. *J periodontal & implant sci* 2012; 42: 50.
25. Kasaj A, Willershausen B, and Reichert C. Ability of nanocrystalline hydroxyapatite paste to promote human periodontal ligament cell proliferation. *J Oral Sci* 2008; 50: 279.
26. Lu H, Wu Z and Tian Y. A study on the effects of cells and scaffolds tissue engineering on the periodontal regeneration. *Chinese J Conserv Dent* 2005; 1:3.
27. Mao Z, Mao X, and Chu C. Effects of Hydroxyapatite-Containing Composite Nanofibers on Osteogenesis of Mesenchymal Stem Cells In vitro and Bone Regeneration In vivo. *Military Med J Sou China* 2013; 5:319–30.
28. Sun WB, Wu YF, and Ding Y. The expression and activity of alkaline phosphatase in human periodontal ligament cells with nanometer hydroxyapatite. *Chinese J stomatol* 2006; 41: 348.
29. Kasaj A, Klein MO, and Dupont J. Early root surface colonization by human periodontal ligament fibroblasts following treatment with different biomaterials. *Acta Odontologica Scandinavica* 2013; 71:579–602.
30. Sailer HF, and Weber FE. Bone substitutes. *Knochenersatzmaterialien. Mund Kiefer Gesichts Chir* 2000; 4: 384–91.
31. Bauer TW, and Muschler GF. Bone graft materials. An overview of the basic science. *Clin Orthop Relat Res* 2000; 371: 10–27.
32. De Groot K. Clinical usefulness of calcium phosphate ceramics. *Zahnärztl Mitt* 1985; 75: 1938–40.
33. Constantz BR, Ison IC, Fulmer MT, Poser RD, Smith ST, VanWagoner M, Ross J, Goldstein SA, Jupiter JB, and Rosenthal DI. Skeletal repair by in situ formation of the mineral phase of bone. *Science* 1995; 267: 1796–9.
34. Müller-Mai CM, Stupp SI, Voigt C, and Gross U. Nanoapatite and organoapatite implants in bone: Histology and ultrastructure of the interface. *J Biomed Mater Res* 2010; 29: 9–18.

35. Wenisch S, Stahl JP, Horas U, Heis C, Kilian O, Trinkaus K, Hild A, and Schnettler R. In vivo mechanisms of hydroxyapatite ceramic degradation by osteoclasts: fine structural microscopy. *J Biomed Res A* 2013; 67: 713–8.
36. Schenk RK. Zur Problematik der Knochenersatzstoffe: Histophysiologie des Knochenumbaus und der Substitution von Knochenersatzstoffen. In: Huggler AH, Kuner EH (eds.) *Hefte Unfallheilkd* 1991; 216: 23–5.
37. Müller-Mai CM, Voigt C, and Gross U. Incorporation and degradation of hydroxyapatite implants of different surface roughness and surface structure in bone. *Scan Microsc* 1990; 4: 613–24.
38. Gomi K, Lowenberg B, Shapiro G, and Davies JE. Resorption of sintered synthetic hydroxyapatite by osteoclasts in vitro. *Biomater* 1993; 14: 91–6.
39. Müller-Mai C, Voigt C, Hering A, Rahmzadeh R, and Gross U. Madreporic hydroxyapatite granulates for filling bone defects. *Unfallchirurg* 2001; 104: 221–9.
40. Shimizu H, Sakamoto S, Sakamoto M, and Lee DD. The effect of substrate composition and condition on resorption by isolated osteoclasts. *Bone Mineral* 1989; 6: 261–75.
41. Rueger JM. Bone substitution materials. Current status and prospects. *Orthopäde* 1998; 27: 72–9.