

Restorative Dentistry Issue (Removable Prosthodontics, Fixed Prosthodontics, Endodontics, Dental Biomaterials, Operative Dentistry)

7-1-2018

A Clinical Comparison between Mini and Short Dental Implants in Completely Edentulous Patients with Atrophic Ridges

Nancy Saad

Dentist at Matarya Teaching hospital , General Organization For Teaching Hospitals

Shereen Kabeel

Lecturer of Removable Prosthodontics, Faculty of Dental Medicine for Girls, Al-Azhar University

Hala Abbas

Professor of Removable Prosthodontics, Faculty of Dental Medicine for Girls, Al-Azhar University.

Nahed Abd El-Moniem

Lecturer of Oral & Maxillofacial Surgery, Faculty of Dental Medicine for Girls, Al-Azhar University.

Follow this and additional works at: <https://azjd.researchcommons.org/journal>



Part of the [Other Dentistry Commons](#)

How to Cite This Article

Saad, Nancy; Kabeel, Shereen; Abbas, Hala; and Abd El-Moniem, Nahed (2018) "A Clinical Comparison between Mini and Short Dental Implants in Completely Edentulous Patients with Atrophic Ridges," *Al-Azhar Journal of Dentistry*. Vol. 5: Iss. 3, Article 10.

DOI: <https://doi.org/10.21608/adjg.2018.17197>

This Original Study is brought to you for free and open access by Al-Azhar Journal of Dentistry. It has been accepted for inclusion in Al-Azhar Journal of Dentistry by an authorized editor of Al-Azhar Journal of Dentistry. For more information, please contact yasmeenmahdy@yahoo.com.



A Clinical Comparison between Mini and Short Dental Implants in Completely Edentulous Patients with Atrophic Ridges

Nancy Gomaa Aly Mohamed Saad⁽¹⁾, Shereen Mohamed Mohamed Kabeel⁽²⁾,
Hala Mohammed Gamal El Deen Abbas⁽³⁾ and Nahed Mohamed Adly Abd El Moniem⁽⁴⁾

Codex : 35/1807

azhardentj@azhar.edu.eg

http://adjg.journals.ekb.eg

ABSTRACT

Aim: This study aimed to compare between mini implants and short implants supported overdentures in completely edentulous patients with atrophic ridges not suitable for conventional implants. **Materials and methods:** Ten completely edentulous patients with severely resorbed mandible and age ranged between 55 and 60 years were selected for this study. Complete heat cured acrylic resin dentures were constructed for all patients. Patients were divided into two groups, each group had five edentulous patients. In Group I, each patient received two mandibular mini-implants at the canine site with a standard diameter 2.5 mm and standard length 10 mm, while in Group II, each patient received two mandibular short implants at the canine site with standard diameter 3.4 mm and standard length 10 mm. All implants in both groups were placed following immediate loading protocol. Patients were recalled for a follow-up period of 1 year, evaluating implants clinically for pocket depth and gingival index at baseline, then 3, 6 and 9 months intervals, and evaluating bone height loss radiographically at baseline, then 6, 9 and 12 months intervals. **Results:** Pocket depth and crestal bone height loss increased in patients using short implants than patients using mini implants, while gingival index parameter in all patients was not affected by using the two types of implants. **Conclusion:** Mini dental implants have a favorable effect on the supporting structure than short dental implants in both clinical and radiographic evaluation.

INTRODUCTION

Complete maxillary denture wearers tolerate better the complete dentures, given the better conditions for support, retention and stability, the tolerance of mandibular prosthesis is generally lower due to more bone resorption. It has been shown that implants significantly reduce the amount of bone loss, denture instability, pain and sore spots, leading to improved masticatory efficiency⁽¹⁾.

KEYWORDS

*Mini, Short, Implants,
Overdenture, Flapless,
Immediate loading.*

- Extracted from Master Thesis Entitled A Clinical Comparison Between Mini and Short Dental Implants in Complete Edentulous Patients with Atrophic Ridges.
- 1. Dentist at Matarya Teaching hospital , General Organization For Teaching Hospitals.
- 2. Lecturer of Removable Prosthodontics, Faculty of Dental Medicine for Girls, Al-Azhar University.
- 3. Professor of Removable Prosthodontics, Faculty of Dental Medicine for Girls, Al-Azhar University.
- 4. Lecturer of Oral & Maxillofacial Surgery, Faculty of Dental Medicine for Girls, Al-Azhar University.

The relatively frequent instability of the mandibular denture, poor retention and associated discomfort were the starting point for the idea of setting the overdenture on 2 implants as first treatment alternative for the mandibular complete edentulism. Also inadequate bone volume makes it difficult for denture to be stabilized by conventional standard diameter implants (3.5mm & wider) without ridge augmentation, with multiple surgical procedures, increased time and high cost factors ⁽²⁾.

Mini-implants may be considered alternative-treatment in patients with severely atrophic thin ridges that does not allow conventional implant placement without additional surgical interventions, decreasing surgical steps by switching from two-stage surgical protocols to single-stage surgical protocols, and shortened treatment time, less invasive with increasing patients level of satisfaction ⁽³⁾.

Short implants are another alternative treatment for rehabilitation of severe atrophied ridge with low bone height not suitable for long implants placement and patients who can not afford expensive surgical interventions like, bone grafting and sinus lifting which also increase surgical time and not satisfying to the patient ⁽⁴⁾.

The aim of the study was to compare between mini implants and short implants supported overdentures in completely edentulous patients with atrophic ridges not suitable for conventional implants.

MATERIAL AND METHODS

Ten completely edentulous patients with age ranged between 55 and 60 years were selected for this study. Patients were free from any systemic diseases, oral pathologies, TMJ disorders or bone diseases. All patients had Angle's class I jaw relationship and enough inter-arch space. Their ridges were severely resorbed covered with firm and healthy mucosa. A period of at least six months was elapsed from the last extraction. All patients accepted the treatment and provided written

accepted consent. All patients received heat cured acrylic resin complete maxillary and mandibular dentures before surgery, following the conventional clinical and laboratory techniques. For each patient, cone beam computerized tomography (CBCT) with radiographic stent in place was taken to evaluate alveolar bone quality and quantity and exact implant dimensions at the proposed implants positions (canine sites).

All patients were divided into two groups, each group had 5 edentulous patients, In Group I, each patient received 2 mandibular mini-implants (2.5 × 10 mm), while in Group II, and each patient received 2 mandibular short implants (3.4 × 10 mm). All implants installed following immediate loading protocol using flapless surgical technique. For Group I, one-body mini-implants were finally placed with the ball abutment attached to it (Fig.1), while for Group II, after final placement of the short implant, the ball-shaped abutments were screwed to the implant using the hex screw driver (Fig.2).

For both groups, following the immediate loading protocol (within one week from surgery), the metal housings (female sockets) which was the same for all implants in both groups, were seated over the male ball abutment of each implant, all undercuts below the attachments were blocked using softened wax. The fitting surface of the lower denture at the implants sites was relieved to create sufficient room for metallic housing, the relieved holes were filled with self cure acrylic resin, the lower overdenture was then seated in the patient mouth under normal occlusal pressure, with the female socket covering the ball part of the implant. After setting of the self-cure acrylic resin, the overdenture was removed with the female socket embedded in it, excess material was removed and occlusion was rechecked. All patients in both groups were followed up at baseline (during loading visit), then 3, 6, and 9 months of loading clinically and 6, 9 and 12 months of loading radiographically.

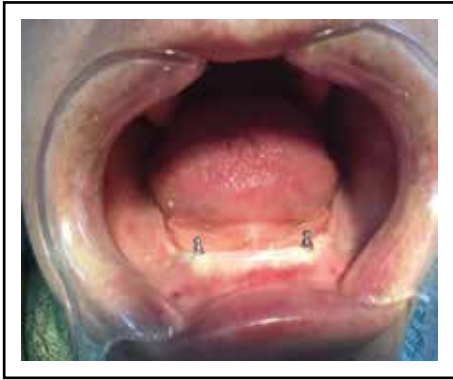

Fig. (1) Final placement of one-body Mini-implants with ball abutment attached to it.

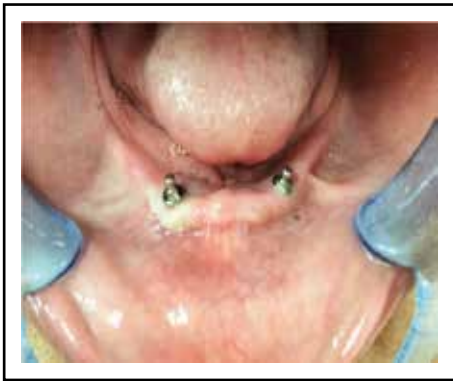

Fig. (2) Final placement of Short implants after the ball abutments screwed to it.

I. Clinical Evaluation:

A. Pocket depth (PD):

The depth of the pockets around each implant was measured using plastic color coded probe. The periodontal probe was inserted between the abutment and the peri-implant gingival sulcular epithelium with minimal pressure. The distance from the marginal border of the gingiva to the plastic periodontal probe tip, recorded as pocket depth (PD). PD measurements recorded at 4 specific sites of each implant, middle of buccal, middle of mesial, middle of lingual, middle of distal, recorded to the nearest millimeter, the average of right and left implant measurements per patient were calculated and the results were statistically analyzed.

B. Gingival index (GI):

To assess potential peri-implant inflammation, the gingival index was used according to the modified Loe and Silness index. It was performed by careful isolation and drying the area around the implants. Each surface was scored individually according to the modified Leo gingival index scores:

Grade (0): Normal peri-implant mucosa.

Grade (1): Mild inflammation, slight change in color and slight edema.

Grade (2): Moderate inflammation, redness and edema.

Grade (3): Severe inflammation, marked redness and edema and ulceration), and the mean value for the scored surfaces for each implant was calculated.

II. Radiographic Evaluation:

1-Construction of radiographic template:

Radiographic template was constructed to use for radiographic assessment of bone height changes.

Assessments of the alveolar bone height around the implants were performed utilizing the Vista Scan (VS) system. Also a periapical film holder (RINN XCP), a reusable imaging plate, x-ray machine, and two individually constructed radiographic acrylic templates (right & left) were used for making standardized digital images for the implants following the long cone paralleling technique. The film holder instrument consists of a removable plastic plate, a plastic ring and a metallic indicator arm. The imaging plate was exposed by the x-ray machine at 50 kilovolt, 10 milliamperere for 0.10 second for canine imaging. The image was displayed on the computer monitor, and stored in patient's file. These procedures were repeated for the implants on the left side of the patient. (Fig.3&4)




Fig. (3) Bone height loss follow-up around Mini-Implants.




Fig. (4) Bone height loss follow-up around Short-Implants.

Data analysis was performed in several steps. Initially, descriptive statistics for each group results. One-way ANOVA followed by pair-wise Tukey’s post-hoc tests were performed if it showed significance between subgroups. Two-way analysis of variance ANOVA test of significance was done for comparing variables (group and time) affecting mean values. Student t-test was performed to detect interaction between main groups with each time. Statistical analysis was performed using Graph-Pad Instate statistics software for Windows. P values ≤ 0.05 are statistically significant in all tests.

RESULTS

From the calculated data and its statistical analysis, the following results could be achieved and shown in tables (1, 2 & 3): It was found that Group I recorded lower mean values for pocket depth than Group II and this was statistically significant $P < 0.0001$, also Group I recorded lower mean values for bone height loss than Group II and this was statistically significant $P < 0.0001$, while the gingival index parameters showed non significant differences between the 2 groups $P = 0.9638$, $P = 0.9860$.

Table (1) Descriptive statistics of pocket depth results for both groups as function of evaluation time.

Variable		Mean	SD	SE	Median	Minimum	Maximum	P value
Group I	Baseline	0.75	0.111803	0.1	0.75	0.625	0.875	$< 0.0001^*$
	3 months	1.46875	0.299739	0.225	1.46875	1.125	2	
	6 months	2.09375	0.092702	0.075	2.09375	2	2.25	
	9 months	2.40625	0.199609	0.1375	2.375	2.125	2.75	
Group II	Baseline	0.90625	0.165359	0.125	0.90625	0.625	1.125	$< 0.0001^*$
	3 months	1.90625	0.121835	0.0875	1.875	1.75	2.125	
	6 months	2.15625	0.121835	0.0875	2.125	2	2.375	
	9 months	2.59375	0.121835	0.0875	2.625	2.375	2.75	

*; significant ($P < 0.05$).

Table (2) Descriptive statistics of gingival index results for both groups as function of evaluation time.

Variable		Mean	SD	SE	Median	Minimum	Maximum	P value
Group I	Baseline	1.3125	0.201556	0.15	1.3125	1	1.625	0.9638 ns
	3 months	1.28125	0.165359	0.125	1.28125	1	1.5	
	6 months	1.28125	0.165359	0.125	1.28125	1	1.5	
	9 months	1.25	0.136931	0.1	1.25	1	1.375	
Group II	Baseline	1.3125	0.201556	0.15	1.3125	1	1.625	0.9860 ns
	3 months	1.28125	0.145237	0.1125	1.375	1	1.375	
	6 months	1.3125	0.167705	0.125	1.375	1	1.5	
	9 months	1.28125	0.145237	0.1125	1.375	1	1.375	

ns; non- significant ($P>0.05$)

Table (3) Descriptive statistics of bone height loss results for both groups as function of evaluation time.

Variable		Mean	SD	SE	Median	Minimum	Maximum	P value
Group I	6 months	0.825	0.057009	0.04	0.825	0.725	0.9	<0.0001*
	9 months	1.05	0.041833	0.03	1.05	1	1.125	
	12 months	1.29375	0.073101	0.055	1.29375	1.225	1.425	
Group II	6 months	1.05625	0.094041	0.075	1.05625	0.9	1.175	<0.0001*
	9 months	1.48125	0.156025	0.115	1.48125	1.275	1.75	
	12 months	1.84375	0.140868	0.115	1.84375	1.675	2.075	

*, Significant ($P<0.05$).

DISCUSSION

Nowadays, the use of mini-implant overdenture becomes a rapid and technically easier replacement of the conventional implant overdenture, due to being one piece system and the surgery being less aggressive with less number of drills, small osteotomy prepared, less healing time, and also it doesn't need screws or space for abutment placement. Short implants can be considered as a viable treatment option in atrophic ridge cases in order to avoid complex surgical procedures associated with higher cost and increased time ^(5,6).

In this study, two implants per patient were used to support mandibular overdentures for both groups, several studies stated that mandibular implant overdenture on two implants is a well-established and effective option. Different numbers of implants have been proposed for implant overdentures, but two anterior implants are sufficient ⁽⁷⁾.

In this study, implants were placed with the flapless technique in all cases as this technique is suitable for immediate loading protocol which gained popularity as it causes less tissue trauma, reduces overall treatment time, decreases patient's

anxiety and discomfort, high patient acceptance and better function and esthetics⁽⁸⁾ The patients were followed up for one year, as the maximum bone changes occur mostly during the first year after loading⁽⁹⁾.

In this study, ball and socket was the attachment of choice, the clinical process for the ball attachment is quick and easy, the ball and O-ring attachment transfers less stress to the implant than compared to other attachments and also it decrease denture displacements⁽¹⁰⁾.

Direct technique for incorporating attachments to the overdenture (pick up) was preferred to be used in this study than indirect technique. The direct technique has several advantages including simplicity, less expenses, requires less prosthetic elements and allows the patient to retain the prosthesis⁽¹¹⁾.

The radiographic assessment of crestal bone loss was done by the use of imaging plate. Intraoral digital periapical radiographs were taken with specially constructed radiographic stents and Rinnxcp film holder, producing standardized intraoral radiographs using the long-cone paralleling technique. This technique is still the recommended method for visualizing minute marginal bone changes, despite the continual improvements of extraoral radiographic systems. It was concluded that, this technique is reproducible and provided reliable results⁽¹²⁾. Immediate loading protocol provides patients with immediate function, improved esthetics, and consequently patient satisfaction following implant placement⁽¹³⁾.

It was found that pocket depth in group I (Mini implants) recorded lower mean value than that in group II (Short Implants) and this was statistically significant, This may be due to that the single piece mini-implant provides a gap free connection (bacteria proof) and therefore getting the optimal effect of the barrier and protection functions of the peri-implant soft tissue. The micro-gap/joint between the implant and abutment in two-piece

implant (short implant) permits micro-leakage of fluids that contain bacterial byproducts or nutrients required for bacterial growth⁽¹⁴⁾. This increase in probing depth is considered as a common change relative to other similar studies and is considered within the permissible range of the criteria for implant success as stated by Hermann et al. 2001⁽¹⁵⁾.

In the present study, gingival index parameters throughout the study period was not affected by the type of implants, which may reflect the easiness in oral hygiene maintenance of the ball attachments due to facilitated denture insertion and removal⁽¹⁶⁾. Consequently, this study in agreement with other authors who considered the ball attachments as highly hygienic and reported that ball attachments have superb hygiene maintenance capabilities⁽¹⁷⁾.

The bone level recorded just after the surgical insertion of the implant and overdenture loading was the basal value to compare with subsequent measurements over time. As a result there was no bone height changes appear during evaluation at baseline (time of loading), since the implant neck appear to be flushing with bone, and this will be the reference point for all measurements during the evaluation period.

The bone height loss in Group I (Mini implants) recorded lower mean value than group II (Short implants), this may be due to micro-gap found between the implant and abutment junction in two-piece short implant. The micro-gap-crestal bone level relationship was studied radiographically by Hermann et al. 2001, who demonstrated that the micro-gap between the implant/abutment has a direct effect on crestal bone loss, independent of surgical approaches⁽¹⁸⁾. This is in agreement with the previous study which explained that one-piece implant systems were designed to minimize crestal bone loss based on the theory that contamination of the implant-abutment junction (the microgap) and violation of the biological width are the causes of the initial bone loss in two piece implants⁽¹⁹⁾.

Regardless of experimental groups, it was found that the bone height loss increased significantly with time, this amount of bone loss might be due to placement of the rigid metal sockets immediately after implant insertion, which produce excessive retention and possibly put excessive tensile forces on the implants⁽²⁰⁾.

The results of this study confirmed the success of both groups since, At the Toronto Conference, the consensus with respect to peri-implant bone loss of up to approximately 2 mm during the first year of implant function is acceptable, and at this level the implant is regarded as successful. Also average alveolar ridge resorptions adjacent to implants of approximately 1.2 mm to 2.0 mm at the end of the first-year were reported in longitudinal studies^(21,22).

CONCLUSION

Mini dental implants have a favorable effect on the supporting structure than short dental implants in both clinical and radiographic evaluation. Also Mini and Short dental implants are acceptable alternative treatment modalities to conventional dental implants for patients not suitable for conventional implants, with high success rate.

REFERENCES

- Rathika R, Menaga V, Prabhu R, Geetha KR, Suprabha R: A Prosthodontic management of severely resorbed anterior ridge defect. A Case Report. *J ClinDiagn Res.* 2014; 8:15-7.
- Karnam S: Severely Resorbed Edentulous Ridges: A Preventive Prosthodontic Approach. A Case Report. *J ClinDiagn Res.* 2015; 9:17-9. 2
- Kumari P, Verma M, Sainia V, Gupta R, Gill S: Rehabilitation of resorbed mandibular ridges using mini implant retained overdentures: A case series with 3 year follow-up. *J Indian Prosthodont Soc.* 2016; 16:221-6.
- Al-Johany SS, AlAmri MD, Alsaeed S, Alalola B: Dental Implant Length and Diameter: A Proposed Classification Scheme. *J Prosthodont.* 2017; 26;:247-52.
- Tomasi C, Idmyr BO, Wenssröm JL: Patient satisfaction with two mini-implant stabilised full dentures. A 1-year prospective study. *J Oral Rehabil* 2013; 40:526-34.
- Esposito M, Cannizarro G, Soardi E, Pellegrino G, Pistilli R, Felice P: A 3-year post-loading report of a randomized controlled trial on the rehabilitation of posterior atrophic mandibles: Short implants or longer implants in vertically augmented bone? *Eur J Oral Implantol.* 2011; 4:301-11.
- Zygiannakis K, Aartman IH, Wismeijer D: Implant Mandibular Overdentures Retained by Immediately Loaded Implants: A 1-Year Randomized Trial Comparing Patient-Based Outcomes Between Mini Dental Implants and Standard-Sized Implants. *Int J Oral Maxillofac Implants.* 2018; 33:197-205.
- Fortin T, Bosson JL, Isidori M, Blanchet E: Effect of flapless surgery on pain experienced in implant placement using an image-guided system. *Int J Oral Maxillofac Implants* 2006; 21:298-304.
- Fortin T, Bosson JL, Isidori M, Blanchet E: Effect of flapless surgery on pain experienced in implant placement using an image-guided system. *Int J Oral Maxillofac Implants* 2006;21:298-304.
- Manju V, Sreelal T: Mandibular Implant-Supported Overdenture: An In Vitro Comparison of Ball, Bar, and Magnetic Attachments, *J Oral Implant.* 2013; 39:302-07.
- Abdelhamid AM, Asaad AH, Weheda AH: Evaluation of mucosal displacement and denture settlement for direct Vs Indirect Attachment incorporation in implant assisted overdentures. *J Dent Health Oral Disord.* 2016;5:1-8.
- Bilhan H, Geckili O, Bilhan SA: The comparison of the precision of different dental radiographic methods in mandibular peri-implant measurements. *J Istanbul UnivFac Dent.* 2015; 49:1-9.
- Tealdo T, Bevilacqua M, Menini M, et al: Immediate versus delayed loading of dental implants in edentulous maxillae: A 36-month prospective study. *Int J Prosthodont* 2011; 24:294-302.
- Hermann J, Buser D, Schenk RK, Schoolfield JD: Influence of the size of the microgap on crestal bone changes around titanium implants. A histometric evaluation of unloaded non-submerged implants in canine mandible. *J Periodontol* 2001; 72:372-83.
- Jofre J, Hamada T, Nishimura M, Klattenhoff C: The effect of maximum bite force on marginal bone loss of mini-implants supporting a mandibular overdenture: a randomized controlled trial. *J Clin Oral Implants Res.* 2010; 21:243-9.
- Stilwell C: Mandibular Implant Overdentures: Treatment and Medico-Legal Considerations. *Prim Dent J.* 2017; 6:28-35.

17. Misch CE: Contemporary Implant Dentistry, Third Edition St. Louis: Mosby, Inc.; 2008. 950-69.
18. Adell R, Eriksson B, Lekholm U, Brånemark P.I, Jemt T: A long-term follow-up study of osseointegrated implants in the treatment of totally edentulous jaws. *Int J Oral Maxillofac Implants* 1990; 5:347-59.
19. Muhamed A, Adis H, Sead R, Alma K, Lejla K, Selma T: Radiographic Evaluation of Crestal Bone Loss Around Dental Implants in Maxilla and Mandible: One Year Prospective Clinical Study. *J ActaStomatol Croat.* 2015; 49:128-36.
20. Ormianer Z, Garg AK, Palti A: Immediate loading of implant overdentures using modified loading protocol. *Implant dentistry.* 2006; 15:35-40.
21. Azzaldeen A, Musa B, Muhamad AH: Atrophied edentulous mandible with implant-supported overdenture: A 10-year follow-up. *J Den Med Sci.* 2015; 14:1-8.
22. Zarb GA, Albrektsson T: Consensus report: towards optimized treatment outcomes for dental implants *Int J Prosthodont,* 1998;80:641-5.