

Oral Medicine and Surgical Sciences Issue (Oral Medicine, Oral and Maxillofacial Surgery, Oral Pathology, Oral Biology)

4-1-2019

The Efficacy Of Computer Guided Surgery In Preserving Ramal Height And Skull Base During Gap-Arthroplasty In Patients With TMJ Bony Ankylosis

Hanan Reda

Assistant Lecturer of Oral and Maxillofacial Surgery, Faculty of Dental Medicine for Girls, Al-Azhar University, hanan_mezo47@yahoo.com

Susan Abd El Hakim

Professor and Chairman Of Oral and Maxillofacial Surgery Department, Faculty of Dental Medicine for Girls, Al-Azhar University

Ghada Khalifa

Professor of Oral and Maxillofacial Surgery, Faculty of Dental Medicine for Girls, AL-Azhar University, ghaamin@ymail.com

Follow this and additional works at: <https://azjd.researchcommons.org/journal>



Part of the [Other Dentistry Commons](#)

How to Cite This Article

Reda, Hanan; Abd El Hakim, Susan; and Khalifa, Ghada (2019) "The Efficacy Of Computer Guided Surgery In Preserving Ramal Height And Skull Base During Gap-Arthroplasty In Patients With TMJ Bony Ankylosis," *Al-Azhar Journal of Dentistry*. Vol. 6: Iss. 2, Article 13.

DOI: <https://doi.org/10.21608/adjg.2019.42310>

This Original Study is brought to you for free and open access by Al-Azhar Journal of Dentistry. It has been accepted for inclusion in Al-Azhar Journal of Dentistry by an authorized editor of Al-Azhar Journal of Dentistry. For more information, please contact yasmeenmahdy@yahoo.com.



The Efficacy Of Computer Guided Surgery In Preserving Ramal Height And Skull Base During Gap-Arthroplasty In Patients With TMJ Bony Ankylosis

Hanan Reda¹, Susan Abd El Hakim², Ghada Khalifa³

Codex : 28/1904

azhardentj@azhar.edu.eg

http://adjg.journals.ekb.eg

DOI: 10.21608/adjg.2019.5438.1007

ABSTRACT

Purpose: The aim of the study was to compare between computer guided surgery and the traditional method in preserving vertical ramus height (VRH) and the skull base thickness during gap arthroplasty in patients with the TMJ bony ankylosis. **Material and methods:** Twelve patients with 15 joints suffering from true bony TMJ ankylosis were included in this study. The patients were divided into 2 groups: Group A (8 joints); The ankylosis was released by computer-assisted 1cm gap arthroplasty. Group B (7 joints); The ankylosis was released by traditional 1cm gap arthroplasty. Pre and postoperative clinical examinations included: measurements of maximum interincisal opening, midline deviations or deflections during mouth opening or closing, presence of open bite, recording any sign/symptoms of infection, facial nerve function evaluation. Preoperative radiograph were measure the preoperative VRH, and aid in construction of the surgical guide for group A, while, postoperative radiograph performed for measure the VRH and skull base thickness. **Result:** Clinically improvement in the midline shift and occlusion during physiotherapy period postoperatively for all cases in group A except in one patient. While, clinical result in group B revealed increase in the midline shift, and change in occlusion postoperatively. Radiographically: there was no statistical significant difference between the 2 groups in postoperative VRH loss measurements. There was statistical significant difference between the 2 groups in postoperative skull base thickness. **Conclusion:** Computer assisted surgical simulation could help the surgeon to preserve the VRH and the skull base that reflects positively on the postoperative clinical outcomes.

KEYWORDS

*Temporomandibular joint,
Ankylosis, Surgical guide*

- Paper extracted from Doctor thesis titled: The Efficacy Of Computer Guided Surgery In Preserving Ramal Height And Skull Base During Gap-Arthroplasty In Patients With TMJ Bony Ankylosis
1. Assistant Lecturer of Oral and Maxillofacial Surgery, Faculty of Dental Medicine for Girls, Al-Azhar University
 2. Professor and Chairman Of Oral and Maxillofacial Surgery Department, Faculty of Dental Medicine for Girls, Al-Azhar University
 3. Professor of Oral and Maxillofacial Surgery, Faculty of Dental Medicine for Girls, AL-Azhar University.

INTRODUCTION

Temporomandibular joint (TMJ) ankylosis is defined as an osseous or a fibrous fusion of the mandibular condyle to the fossa of the temporal bone⁽¹⁾. It is the most common complication associated with trauma (13-100%), local or systemic infection (10-49%), or systemic diseases (10%)⁽²⁾. Local infections which are commonly associated with TMJ ankylosis as otitis media and mastoiditis, while the systemic infections include tuberculosis, scarlet fever, and gonorrhoea. Additionally, there are systemic diseases which are known to cause TMJ ankylosis such as ankylosing spondylitis, rheumatoid arthritis, sickle cell anemia, psoriasis, and fibrous dysplasia ossificans progressive,etc⁽³⁻⁵⁾.

The surgical release of TMJ ankylosis is aimed to creating a pseudo-joint which will improve function and movement of the mandible, preventing relapse, relieving airway obstruction if present, achieving normal growth and correction of deformity, restoring appearance and occlusion, and facilitating maintenance of good oral hygiene⁽¹⁾. Different surgical techniques have been reported that include condylectomy, gap arthroplasty, interpositional arthroplasty, or joint reconstruction using autogenous or alloplastic graft. The problem with gap arthroplasty that pseudo joint was created at low level to avoid injury of skull base which lead to increase in the thickness of the glenoid fossa with subsequent loss of vertical ramus height⁽⁶⁻⁸⁾.

Many surgical complications which face the surgeons during TMJ ankylosis surgeries have been reported such as injury of the vital structures at the base of the skull and adverse reduction of VRH with subsequent occlusal disharmony and facial deformities⁽⁹⁾. The computer-assisted surgical simulation (CASS) which has been introduced in craniomaxillofacial surgeries solves many of those difficulties. The idea is relying on the three dimensional CT images (3DCT) and fabrication of the computer-generated stereolithographic physical models (STL) which improves the representation and understanding of the expected anatomy, this allowing accurate

preoperative diagnosis and precise pre-surgical planning⁽¹⁰⁾.

The aim of this study was to compare between computer guided surgery and the traditional method in preserving vertical ramus height (VRH) and the skull base thickness during gap arthroplasty in patients with the TMJ bony ankylosis.

MATERIAL AND METHODS

Study Design

This study included 12 patients who suffered from true bony TMJ ankylosis. They were selected from the Outpatient Clinic of the Oral and Maxillofacial Surgery Department, Faculty of Oral and Dental Medicine for Girls, Al-Azhar University and from El Zahraa University Hospital between May 2015 and July 2017. This study was approved by the ethical committee of the Faculty of Oral and Dental Medicine for Girls, Al-Azhar University. The indications, the goals of treatment, the risks and benefits associated with the treatment, the factors that may affect the risk, the treatment options, and the favorable outcomes were explained for all the patients, and a written informed consent was obtained from all the patients or their parents (if they were younger than 21 years). All the patients agreed to be treated according to a multistage management protocol for TMJ ankylosis, in which the release of the ankylotic mass was performed first.

The patients were divided into 2 groups: Group A; in which, the patients were treated by computer-assisted 1cm gap arthroplasty. Group B; in which, the ankylosis was released by traditional 1cm gap arthroplasty.

Inclusion And Exclusion Criteria

Inclusion criteria include: Limitation of mouth opening less than 20 mm which lasted for more than one year; absence of systemic diseases; presence of TMJ bony ankylosis; indication for the gap arthroplasty; and, available CT data before operation and 1 week after operation.

Exclusion criteria include: Medically compromised patients; patients had history of psychiatric disorders or mental retardation that were not able to do physiotherapy; and, patients were refused to enroll in the study.

Study Variables

Primary Predictable Variables: were the patient’s demographic data that included:

Age, sex, etiology, extent and duration of ankylosis; the surgical data (Sawhney types of ankylosis, Topazian stages of ankylosis, and presence or absence of cleavage lines); history of previous surgery; recurrence; and, affected side (uni or bilateral).

Secondary Predictable Variable:

Preoperative VRH which was measured from the preoperative lateral side of 3DCT cuts (Figure 1 A).

The Outcome Variables Were:

- (1) Postoperative VRH was measured from the postoperative lateral side of 3DCT cuts (Figure 1 B).
- (2) Thickness of the base of the skull after osteotomy was measured from postoperative 2D coronal CT scans (Figure 2). The measuring tool of the software was used to measure the VRH and the thickness of the base of skull in millimeters.

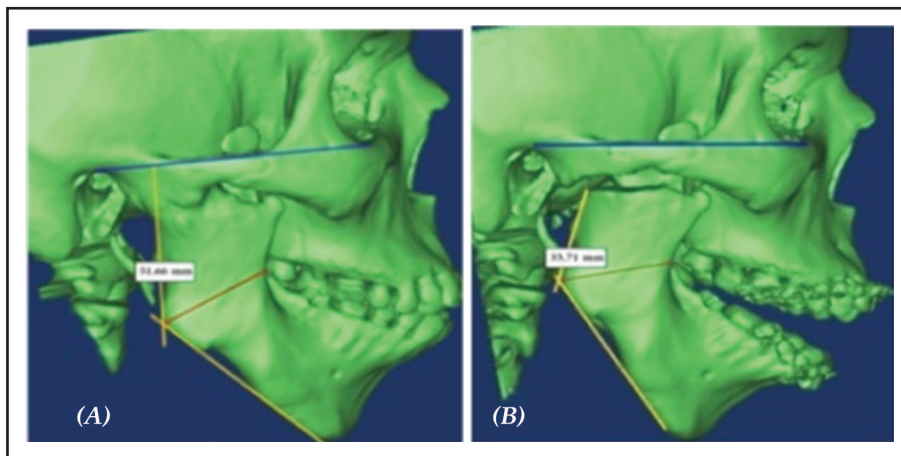


Figure (1): Pre and post 3DCT cuts demonstrating measuring of the VRH.

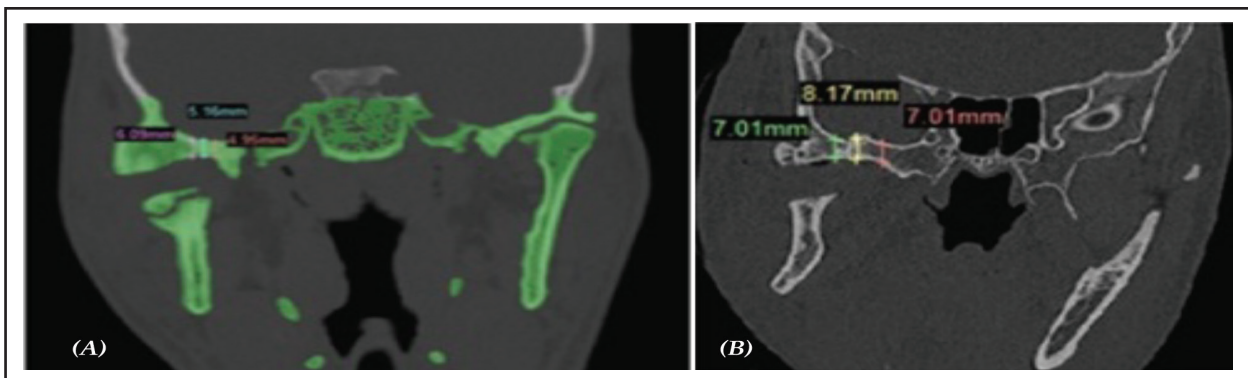


Figure (2): Coronal cuts demonstrating measuring of the postoperative skull base thickness.

Patient Management Protocol

All the patients, in both groups, were subjected to:

1. Pre and postoperative intra and extraoral clinical examinations which included: Measurements of MIO; midline deviations or deflections during mouth opening or closing; presence of open bite; recording any sign/symptoms of infection; and, facial nerve function evaluation.
2. Preoperative OPGs and multislice CT scans were taken for all the patients in both groups.
3. The immediate postoperative multislice CT scans (within the 1st postoperative week) were also performed for all the patients in both groups to measure the study variables.

Preoperative Planning And Simulation For Computer Assisted Gap Arthroplasty Group (Group A)

All the patients in this group underwent the preoperative cranial-maxillofacial CT scans with the slice thickness 0.625 mm which were performed using a slice multi-detector CT scanner (Aquillion Prime 160 Slice; Toshiba, Tokyo, Japan). The data were stored in DICOM format and imported into the 3 Diagnosys software (Version 4.2, 3Diemme, Italy) which enables virtual diagnosis, surgical planning, preoperative segmentation, and digital resection of the ankylosis. The patient's individual anatomy was assessed in multiplanar (axial, coronal, sagittal, and 3D views). By using the software tools, a virtual 3D implant with 1cm diameter (which is equal to the width of gap arthroplasty) was placed 5 mm below the base of skull to avoid its injury. The amount of ankylotic bone to be resected was determined in the coronal, preformatted OPG, and 3D reconstructions. After segmentations, visualization of the 2D reformatted CT images to ensure that the upper osteotomy was placed at site away from the base of skull in all the slices, and the lower osteotomy was located away from the upper one by 1cm (Figure 3).

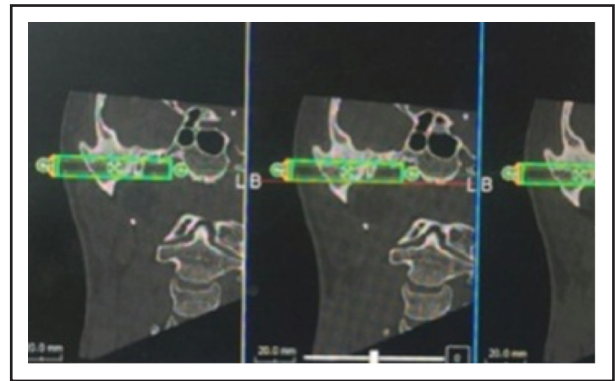


Figure (3): A coronal CT representing virtual surgical planning stage for patients in group A. By using software tools, the 3D implant with diameter 1cm was chosen, and safely placed 5 mm away from the base of the skull.

After planning, the simulation data were introduced into Plastycad software (Version 4.2, 3Diemme, Italy) to design the surgical guide which directs the osteotomies and transfers the virtual plan to the operating room. The surgical guide was designed to resemble U shape. Then, the design was saved and converted into STL format for printing the model by using 3D printer.

The printing material is polyamide material (whitish fine powder PA 2200) which has excellent material properties such as high strength and stiffness, good chemical resistance, excellent long-term constant behavior, high selectivity and detail resolution, various finishing possibilities, and biocompatible according to EN ISO 10993-1 and USP/level VI/121°C. The physical model was manufactured using PLA (polylactic acid) material in RP machine with a precision of 0.8 mm. After printing the guide, sleeves were put in the holes to receive the pins for intraoperative fixation, and subsequently it was sterilized according to the manufacturer's recommendations to be ready for surgical using.

Surgical Procedure

All the patients enrolled in the present study were treated according to the following protocol: (1) Cutting of 1cm gap in the ankylotic mass, (2) Ipsilateral extraoral coronoidectomy followed by intraoral contralateral

coronoidectomy (if required), (3) Pterygomasseteric sling release (if required) when the passive MIO less than 35mm, (4) Immediate continuous aggressive physiotherapy and mouth-opening exercises for 6 months were applied, (5) Regular follow-up to 1 year.

Access To Ankylotic Mass

The surgical sites were accessed through preauricular incisions for recurrent cases and endaural incisions for cases which had no previous operations. Both incisions were made with temporal extension to facilitate the access to the surgical site without tension on the soft tissues.

Surgical Removal Of The Ankylotic Mass

Computer assisted gap arthroplasty group (Group A):

The prefabricated surgical guide was placed on the lateral surface of ascending ramus on the ankylotic mass according to the preoperative planning to guide the upper and lower osteotomies, and they were held in position by using 2 pins. The inferior osteotomy was cut first just below the inferior border of the lower arm of the guide with a saw to the full depth of the bone. After that, the superior cut was done just above the upper border of the lower arm of the guide and then all the osteotomies were completed by using chisels to release the ankylotic mass. The glenoid fossa was then shaped and smoothed by using round burs. If the disk was identified, it was sutured to tissues and the area was irrigated copiously for debridement.

The patient's mouth was dilated by placing and activation of the mouth-gag at the molar region. If the passive MIO < 35mm, the ipsilateral coronoidectomy was performed through the same incision. The coronoid was held by using the Kocher forceps, and the osteotomy was performed that extended from the depth of the sigmoid notch to the anterior border of the ramus. Then, the tendon of temporalis muscle was released to facilitate removal of the coronoid process. Subsequently, ipsilateral pterygomasseteric sling release was also performed (if needed) through intraoral

incision by using "J" stripper to release the attachment of the masseter muscle from the lateral surface of the mandible and from the attachment with the medial pterygoid muscle at the inferior border of the mandible. A trial mouth opening was attempted; if resistance was still present, the contralateral coronoidectomy with contralateral pterygomasseteric sling release were also performed to achieve the passive normal MIO through an intraoral posterior mandibular vestibular incision on the contralateral side.

Traditional gap arthroplasty group (Group B):

The removal of ankylotic mass depended on the surgeon's experience to determine the sites of osteotomies. The extension of the ankylosed bone was identified via the preoperative CT scans. If there was an obvious cleavage line, it was followed to determine the upper osteotomy and the lower one was below it with 1cm. If it was identified in the preoperative CT scans, but it did not appear intraoperatively, the uni-bevel chisels were used to remove the bone on the lateral surface of the ankylotic mass in flaks until the cleavage line was exposed to determine the upper osteotomy. If there was no cleavage line either in CT scan or intraoperatively, the sigmoid notch was used as guide to determine the level of the lower osteotomy, then 1cm above it the upper osteotomy was done.

The incisions were closed in layers, and the pressure dressing was applied for the first 24 hours. During the surgical procedure the intraoperative MIO measurements were recorded. Postoperatively, the jaw was maintained dilated for 24 hours by placement of the suitable size mouth prop.

Follow Up

Cold compresses over the sites of surgery were described 10 minutes every hour during the first 24 hours postoperative. Vital signs were monitored every 6 hours during the first 24 hours. All the patients were instructed to maintain proper oral hygiene. The lips were kept lubricated with petroleum

jelly. The patients were discharged from the hospital within the first week postoperatively, and they were advised to start liquid diet on the first postoperative day, followed by eating soft diet during the next 4 weeks. The skin sutures were removed after 7 days. Immediate postoperative multislice CT scans were taken for all the patients in both groups to measure the study variables within the 1st postoperative week.

The postoperative follow-up included assessment of the postoperative MIO, mandibular movement, occlusion, recurrence, presence of facial nerve paralysis, any other relevant findings, measurement of postoperative VRH, and postoperative thickness of the skull base.

Physiotherapy

The passive mouth opening exercises and professional physiotherapy started from the second day after surgery 5 times per day initially for 6 months to allow normal muscle function and prevent hypomobility secondary to fibrous adhesions, followed by 3 times per day for another 6 months in all the cases.

Statistical Analysis

The means \pm SDs, ranges, and percentages were calculated to summarize the demographic postoperative measurement data. The changes in MIO, VRH, and the postoperative thickness of the skull base in both groups were also analyzed by using Pearson's Chi-Square and Mann Whitney tests to compare between groups. A *P*-value of < 0.05 was considered statistically significant. All statistical calculations were performed by using SPSS software package version 25 (SPSS Inc., Chicago, IL, USA).

RESULTS

Patients Demographic Results

Twelve patients with bony ankylotic TMJ were enrolled in this study. Group A included 8 ankylotic joints, which were surgically released by 1cm gap

arthroplasty that was guided by using computer assisted template. While, group B included 7 ankylotic joints, where the ankylosis was released by using the traditional 1cm gap arthroplasty. Seven patients (with 8 joints) were males and 5 patients (with 7 joints) were females. The ankylosis on the right side constituted 11 joints, while the left side constituted 4 joints. The mean age of all patients was 23.07 ± 6.12 years with a range between 10-30 years. Two patients were less than 16 years old. The longest duration was 24 years, and the shortest one was 2 years. The main cause of the TMJ ankylosis, in all the cases, was traumas due to falls (13 joints), followed by road traffic accidents (RTA) with an improperly treated condylar fracture (2 joints).

The unilateral cases constituted 9 patients(75%), while the bilateral cases constituted 3 patients (25%). The mean of the preoperative MIO measurements in group A was 6.87 ± 4.64 mm with a minimum value of 0 mm and with a maximum value of 11 mm. while, in group B, the mean of the preoperative MIO measurements was 9.85 ± 5.95 mm with a minimum value of 0 mm and with a maximum value of 20 mm. The history of recurrence was present in 8 patients (with 11 joints). Three patients suffered from permanent temporal nerve affection. Two cases of them had unilateral ankylosis, and the nerve affection was on the right side. One of the bilateral cases suffered from temporal nerve affection but it was only on the right side. All the primary predictable variables were equally distributed between the two groups with no statistical significance, where all *P*- values were more than 0.05.

Preoperative Radiographic Results

The results of the preoperative VRH measurements showed that, the VRH was ranged from 45.5mm to 59.8mm with the mean 52.67 ± 5.46 mm in group A. While in group B, it was ranged from 50.7mm to 59mm with mean 52.78 ± 2.83 mm. There were no statistical significant differences between the 2 groups, where all *P*- values were greater than 0.05.

Radiographic Outcome Variables

The mean preoperative VRH, in group A, was 52.67 ± 5.46 mm which ranged from 45.5 to 59.8 mm, and the mean postoperative VRH was 36.71 ± 5.18 mm which ranged from 30 to 43.5 mm. While, in group B, the mean preoperative VRH was 52.78 ± 2.83 mm which ranged from 50.7 to 59 mm, and the mean postoperative VRH was 33.71 ± 2.75 mm which ranged from 30.8 to 38.5 mm. The value of the VRH loss in group A was 16 mm, and it was 19 mm in group B. Therefore, group A was superior to group B in preserving the VRH with 3mm gained length. There was no statistical significant difference between the 2 groups, whereas the *P*-value was equal to 0.245.

Regarding to the mean of the postoperative skull base thickness, for all the cases of group A, was 5 mm as it was planned preoperatively. While for group B, skull base thickness was 8.1 ± 2.44 mm

which ranged from 2.9 to 10 mm. The result of group B demonstrating that, all osteotomies were performed on the expense of VRH, except 1 case the cut was done on the expense of the skull base that had postoperative thickness equal to 2.9 mm. The difference between the 2 groups was statistically significant regarding this variable, whereas the *P*-value was equal to 0.011(Figure 4, 5).

Follow Up

The mean MIO values were increased from 6.87 ± 4.64 mm to 42.37 ± 3.62 mm in group A, and from 9.85 ± 5.95 mm to 42.42 ± 1.90 mm in group B at the first month postoperative, this increase was statistically significant. The measurements slightly increased 6 months postoperatively and up to one year postoperative. At 12 months the mean value started to have stable measurement in all the cases in both groups without any statistical significance (Figure 6).

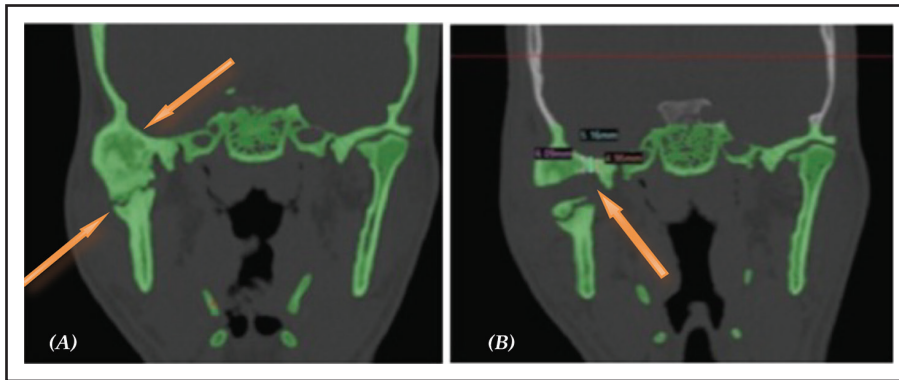


Figure (4): Radiographic CT cuts of 24 year-old male patient with the right side TMJ bony ankylosis who was included in group A. (A) Preoperative coronal CT cut representing the ankylotic bony mass and the level of previous surgical release; (B) Postoperative coronal CT cut representing the postoperative skull base thickness 5mm.

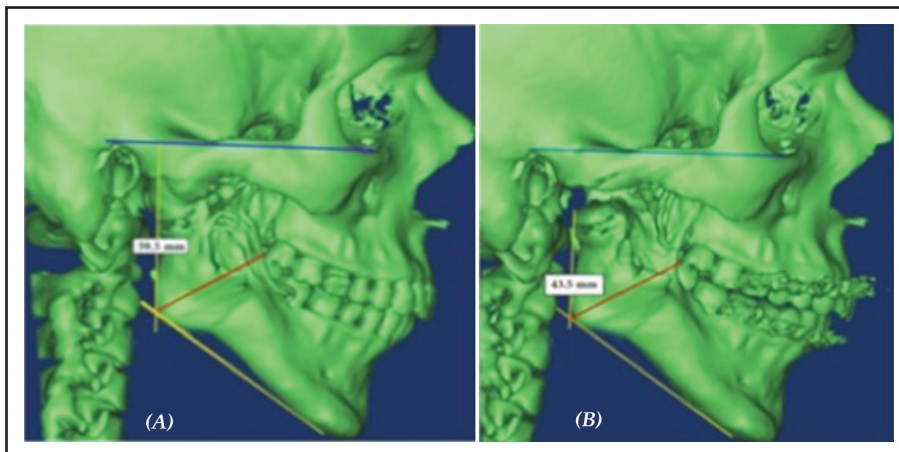


Figure (5): Radiographic CT cuts of 24 year-old male patient with the right side TMJ bony ankylosis who was included in group A. (A) 3DCT representing preoperative VRH= 59.5mm; (B) 3DCT representing postoperative VRH measurement = 43.5mm. There is loss of 16mm in the VRH postoperatively.

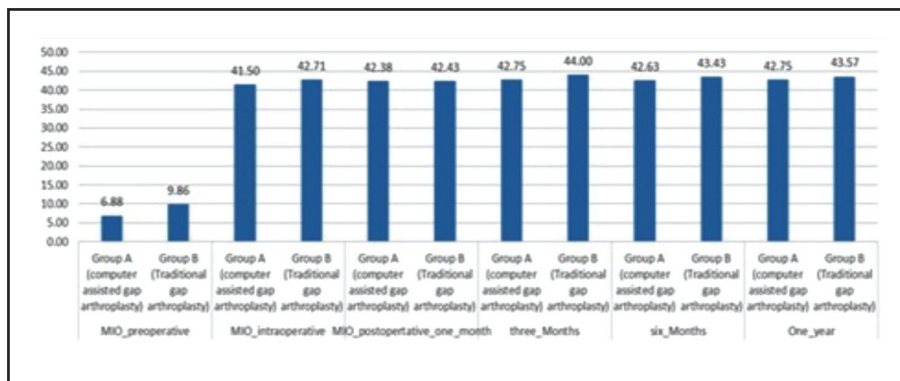


Figure (6): A bar chart representing change in MIO during the follow up period (up to 12 months postoperatively).

DISCUSSION

This prospective study was directed to evaluating the role of computer assisted gap arthroplasty in preserving the VRH and thickness of the glenoid fossa. It was reported that the TMJ is located in a complex anatomical region within the head and neck. It is bounded posteriorly by the external auditory canal and superiorly by the middle cranial fossa. Consequently, these structures are at risk during open surgery with the potential for serious complications, and the adverse reduction of the VRH⁽¹¹⁾.

In this study the computer assisted gap arthroplasty was used to evaluate the efficacy of computer assisted template in overcoming these problems in TMJ ankylosis surgeries. The results revealed that the CASS helped in preoperative planning of the osteotomies sites and determination of the skull base thickness. In group A, CASS helped in locating the upper osteotomy of the gap arthroplasty at distance of 5mm away from the middle cranial fossa to avoid its injury. The lower cut was also located at 1cm below the upper osteotomy. By using the STL file and RP technologies, this planning was transferred to the operating room with the aid of previously constructed templates. This was very helpful in preserving the VRH and saving the skull base. Regarding the accuracy of the surgical guides, the results showed that all guides were easily placed in their sites, they were stable with adequate retention on the bony surfaces, and they safely guided all the osteotomies. Many authors supported these findings, where they found that CASS significantly improved the safety

of the TMJ ankylosis operations and reduced the incidence of complications^(12- 16).

These findings are contrary to the results that were reported from another study⁽¹⁷⁾ which reported some drawbacks such as it is difficult to probably place the surgical guides, especially in cases with large irregular ankylotic mass. Also, wide surgical exposure is needed to facilitate the placement of these surgical guides. In our opinion, these problems could be avoided by proper taking of CT scans which should have good resolution with minimal slice thickness as the accuracy of the template depends mainly on the accuracy of the CT scan. This is in agreement with another study⁽¹⁸⁾.

Regarding the postoperative VRH measurements, the results found that the group A was superior to group B in preservation of the VRH. The mean of VRH, in group A, ranged from 52.67± 5.46mm to 36.71± 5.18mm, while the range of group B was 52.78± 2.83mm to 33.71± 2.75mm. Therefore, in group A, about 3mm of bone was gained and added to the VRH, while in group B, this amount of bone was added to the thickness of the skull base. This is because the upper osteotomy, in group A, was placed at a fixed distance from the skull base, and the level of the ankylotic mass release was higher than that in group B which led to preservation of the VRH in group A. This is in agreement with the findings of another study⁽¹⁹⁾, While, in group B, there was a risk of injury to the skull base. So, the surgeon carries out the osteotomy at the expense of VRH.

The clinical outcome results also revealed that the preserving VRH had advantage of preventing the development of collapse under the influence of elevator muscle that pulls the mandibular stump cranially which may predispose the patients to re-ankylosis. It also simplified the secondary reconstruction surgeries with the attendant morbidity, expense, and long hospital stay, this is in agreement the result of another study⁽²⁰⁾.

The postoperative measurements of skull base thickness, in group A, had a fixed value which was 5mm. This indicates that the template was accurate and it precisely saved the skull base while performing osteotomies. In the preoperative planning, a distance of 5mm was chosen because it was reported by many authors that 5mm is the least distance which should be left between any osteotomy and the vital structures⁽²¹⁾. However, other studies reported a distance of 3mm away from the vital structures, is enough to preserve their vitality^(11,21,22). Furthermore, another study reported that a distance of 0.7 to 1.22mm was enough as it resembles the normal thickness of the glenoid fossa in the normal TMJ⁽²³⁾.

In group B, the skull base thickness differed among the patients. It ranged from 2.9 to 10mm with a mean of 8.12 ± 2.44 mm. The difference between the two groups was statistically significant (P -value= 0.011). The results also demonstrated that the gap was performed on the expense of the VRH in all the patients who were included in group B, except 1 case, in which the gap was performed without control on the expense of the skull base, as the postoperative thickness was 2.9mm.

There was no statistical significance difference between both groups regarding the postoperative VRH and the subsequent clinical outcomes. There was only 3mm of gained bone in group A. The reason for this insignificance could be due to the experience gained by surgeons after the use of the surgical guides, as the cases of group A were treated first,

followed by the cases of the group B. So, the surgeons became familiar with the average distance between the skull base and ankylotic mass. Regarding to the insignificant clinical outcomes, this may be because the cases were managed as joints, and the bilateral cases were treated by both techniques. Thus, all the patients had a preserved VRH either by guide or authors experience.

The key finding of this study is that the use of CASS in TMJ ankylosis surgeries and the surgical guides enable the surgeons to perform preoperative planning; identify the safety margins between the middle cranial fossa and the osteotomy thus saving the vital structures and improving surgical outcomes; and the safe removal of bone on the expense of the skull base to preserve VRH. The clinical significance of the surgical template is that it eliminates the fear of doing injury to the skull base during surgery; it also allows precise transfer of the virtual planning to the surgical field that minimizes intraoperative complications. Also, it is easily fabricated, and there is no need for a technician. However, it is economically expensive, so that it adds more costs to the operation, and it also delays the date of operation because of the time needed for preoperative planning, fabrication, and printing of the surgical guides.

CONCLUSION

The results of this study, suggest the CASS could help the surgeon to preserve the VRH and the skull base that reflects positively on the postoperative clinical outcomes. Additionally, the virtual planning is able to produce accurate templates that help in removal of the ankylotic mass. Also, the conservative gap arthroplasty is a successful technique that could be used for management of the TMJ bony ankylosis, and it helps also in preserving the VRH without fear of recurrence and without the need for navigation which is not available in all hospitals.

REFERENCES

1. Lone P. A clinical case Series of 20 patients with TMJ ankylosis treated by two different approaches. *Indian J applied* 2014; 4: 492-495.
2. Andrade Freitas Oliveira L, Oliveira-Santos C, Melo D, Gomes Torres M, Flores Campos P. Unilateral bony ankylosis of the temporomandibular joint in a case of ankylosing spondylitis. *Oral Maxillofac Surg* 2013; 17:213-217.
3. Yan Y, Liang S, Shen J, Zhang J, Zhang Y. Current concepts in the pathogenesis of traumatic temporomandibular joint ankylosis. *Head Face Med* 2014; 10: 35-46.
4. Gerbino G, Zavattero E, Berrone S, Ramieri G. One stage treatment of temporomandibular joint complete bony ankylosis using total joint replacement. *J Craniomaxillofac Surg* 2016; 44: 487-492.
5. Raheel S, Ara S, Kishore N, Vikram V, Abdulrahman L, Elfaki S. 3D Virtual planning of temporomandibular joint ankylosis using computed tomography a case report in a 4-year-old female patient. *In J ClinDent Sci* 2015; 6: 11-14.
6. Xiao E, Zhang Y, An J, Li J, Yan Y. Long-term evaluation of the stability of reconstructed condyles by transport distraction osteogenesis. *Int J Oral Maxillofac Surg* 2012; 41: 1490-1494.
7. Movahed R, Mercuri L. Management of temporomandibular joint ankylosis. *Oral Maxillofac Surg Clin North Am* 2015; 27: 27-35.
8. Zhu S, Wang D, Yin Q, Hu J. Treatment guidelines for temporomandibular joint ankylosis with secondary dentofacial deformities in adults. *J Craniomaxillofac Surg* 2013; 41: 117-127.
9. Hoffman D, Puig L. Complications of TMJ surgery. *Oral Maxillofac Surg Clin North Am* 2015; 27: 109-124.
10. Lu C, He D, Yang C, Huang D, Ellis E. Computer-assisted surgical planning and simulation for unilateral condylar benign lesions causing facial asymmetry. *Oral Surg Oral Med Oral Pathol Oral Radiol* 2017; 123: 453-458.
11. Warburton G, Aslam-Pervez N. Perforation of the external auditory canal or middle cranial fossa. In: Bouloux G. (eds) *Complications of temporomandibular joint surgery*. Springer, Cham 2017: 41-55.
12. Schmelzeisen R, Gellrich N, Schramm A, Schön R, Otten J. Navigation-guided resection of temporomandibular joint ankylosis promotes safety in skull base surgery. *J Oral Maxillofac Surg* 2002; 60: 1275-1283.
13. Zheng J, Fan B, Zhong Q, Liu P, Guo K, Zhao H, Wang Y, Jin Z, Zhang S, Yang C. Application of computer-assisted surgical simulation for temporomandibular joint reconstruction with costochondral graft. *Int J Clin Exp Med* 2016; 9: 17650-17656.
14. Zhang S, Liu X, Xu Y, Yang C, Undt G, Chen M, Haddad M, Yun B. Application of rapid prototyping for temporomandibular joint reconstruction. *J Oral Maxillofac Surg* 2011; 69: 432-438.
15. Haq J, Patel N, Weimer K, Matthews N. Single stage treatment of ankylosis of the temporomandibular joint using patient-specific total joint replacement and virtual surgical planning. *Br J Oral Maxillofac Surg* 2014; 52: 350-355.
16. Aagaard E, Thygesen T. A prospective, single-centre study on patient outcomes following temporomandibular joint replacement using a custom-made Biomet TMJ prosthesis. *Int J Oral Maxillofac Surg* 2014; 43: 1229-1235.
17. Lu C, He D, Yang C, Wilson J. Use of computer-assisted templates for placement of osteotomies in lateral gap arthroplasty. *J Oral Maxillofac Surg* 2015; 73: 30-38.
18. Edwards S. Computer-assisted craniomaxillofacial surgery. *Oral Maxillofac Surg Clin North Am* 2010; 22: 117-134.
19. He Y, Huang T, Zhang Y, An J, He L. Application of a computer-assisted surgical navigation system in temporomandibular joint ankylosis surgery: a retrospective study. *Int J Oral Maxillofac Surg* 2017; 46: 189-197.
20. Nitzan D, Palla S. Closed reduction principles can manage diverse conditions of temporomandibular joint vertical height loss: from displaced condylar fractures to idiopathic condylar resorption. *J Oral Maxillofac Surg* 2017; 75: 1163. e1-1163.e20.
21. Kashani H, Rasmusson L. Osteotomies in Orthognathic Surgery. *A Textbook of Advanced Oral and Maxillofacial Surgery Volume 3* 2016; In Tech, DOI: 10.5772/61140.
22. Sun G, Lu M, Hu Q. The application of surgical navigation in the treatment of temporomandibular joint ankylosis. *J Craniofac Surg* 2015; 26: 776-780.
23. Ejima K, Schulze D, Stippig A, Matsumoto K, Rottke D, Honda K. Relationship between the thickness of the roof of glenoid fossa, condyle morphology and remaining teeth in asymptomatic European patients based on cone beam CT data sets. *Dentomaxillofac Radiol* 2013; 42: 410-417.