

Oral Medicine and Surgical Sciences Issue (Oral Medicine, Oral and Maxillofacial Surgery, Oral Pathology, Oral Biology)

1-1-2020

## Flapless Ridge Splitting Technique with Platelet Rich Fibrin for Immediate Implant Placement in Atrophic Alveolar Ridge

Reham Abdelsalam

*Dentist at Ministry of Health, Cairo, Egypt, reham.abdelrahman@yahoo.com*

Susan Hassan

*Professor of Oral and Maxillofacial surgery, Faculty of Dental Medicine for Girls, Al-Azhar University, Cairo, Egypt, sabdelhakim2003@yahoo.com*

Nahed Abdelmoniem

*Lecturer of Oral and Maxillofacial surgery, Faculty of Dental Medicine for Girls, Al-Azhar University, Cairo, Egypt, nahedadly@gmail.com*

Follow this and additional works at: <https://azjd.researchcommons.org/journal>



Part of the [Other Dentistry Commons](#)

---

### How to Cite This Article

Abdelsalam, Reham; Hassan, Susan; and Abdelmoniem, Nahed (2020) "Flapless Ridge Splitting Technique with Platelet Rich Fibrin for Immediate Implant Placement in Atrophic Alveolar Ridge," *Al-Azhar Journal of Dentistry*. Vol. 7: Iss. 1, Article 15.

DOI: <https://doi.org/10.21608/adjg.2019.7846.1107>

This Case Report is brought to you for free and open access by Al-Azhar Journal of Dentistry. It has been accepted for inclusion in Al-Azhar Journal of Dentistry by an authorized editor of Al-Azhar Journal of Dentistry. For more information, please contact [yasmeenmahdy@yahoo.com](mailto:yasmeenmahdy@yahoo.com).



## Flapless Ridge Splitting Technique with Platelet Rich Fibrin for Immediate Implant Placement in Atrophic Alveolar Ridge

Reham A. Abdelsalam<sup>1\*</sup>, Susan A. Hassan<sup>2</sup>, Nahed A. Abdelmoniem<sup>3</sup>

Codex : 15/2001

azhardentj@azhar.edu.eg

http://adjg.journals.ekb.eg

DOI: 10.21608/adjg.2019.7846.1107

### ABSTRACT

**Purpose:** this study was conducted between 2017 and 2019 at the Faculty of Dental Medicine for Girls, Al-Azhar University. It aimed to improve alveolar ridge dimensions for immediate implant placement in cases with atrophic alveolar ridge. **Subjects and methods:** Six patients fulfilling the inclusion criteria were recruited from the outpatient clinic of Oral and Maxillofacial Surgery Department. Two computer guided surgical stents were used to guide flapless ridge splitting using piezoelectric device and simultaneous implant placement with PRF, a clinical and radiographic follow up was performed for 6 months. **Results:** There was a significant increase in buccolingual ridge dimensions with successfully osseointegrated dental implants, whereas guide accuracy was at an accepted level. **Conclusion:** Computer guided Flapless ridge splitting with PRF and immediate implant placement is an innovative, less invasive, atraumatic and predictable technique.

### INTRODUCTION

Nowadays teeth substitution is evoking toward implant therapy<sup>(1)</sup>. Several studies confirmed that tooth extraction results in a statistically significant collapse of the alveolar ridge dimensions, as a part of the remodeling<sup>(2)</sup>. However horizontal shrinkage is more prevalent<sup>(3)</sup>.

Various techniques were suggested for augmentation of the thin alveolar ridge such as guided bone regeneration (GBR), onlay bone grafting (OBG), alveolar distraction osteogenesis (ADO), and alveolar ridge-split (ARS) techniques. Considering different techniques

### KEYWORDS

*Splitting, Flapless,  
Piezoelectric, PRF, Implant.*

1. Dentist at Ministry of Health
2. Professor of Oral and Maxillofacial surgery, Faculty of Dental Medicine for Girls, Al-Azhar University
3. Lecturer of Oral and Maxillofacial surgery, Faculty of Dental Medicine for Girls, Al-Azhar University

\* Corresponding author Email: reham.abdelrahman@yahoo.com

for alveolar bone augmentation, relevant and better results for implant survival and stability were reported in the literature for ridge splitting technique<sup>(4-8)</sup>.

Using piezosurgery in flapless implant surgeries has better outcomes, owing to high power, selectivity, safety, reduced tissue trauma and high patient acceptance<sup>(9)</sup>. PRF membranes can be applied to protect and seal the gap. It is considered a bio active membrane as it releases growth factors which positively augment healing process<sup>(10)</sup>. The recent introduction of cone beam computed tomography (CBCT) in oral health care has allowed accurate diagnosis and treatment planning for dental implant placement<sup>(11)</sup>.

## SUBJECTS AND METHODS

Our study was carried out on six patients; all patients were informed about procedure details and signed a consent form that they accepted to be involved.

## Pre-surgical Preparation:

Patients data, medical and dental history were collected, clinical and radiographic examinations were done including CBCT for assessment of bone dimensions and planning for splitting and implant placement.

The Dicom files from the CBCT were imported to the planning software, the stone model of the patient was obtained digitally using a laboratory optical scanner and saved as an STL file. The optical scan of the cast was registered to the CBCT using the teeth as common landmarks in both images.

Virtual wax up was done on the software, the center of the ridge was detected and projections were placed marking the position and direction of the splitting. Another plan was performed on the software by placing virtual implants in the future proposed center of the ridge after splitting (prosthetic driven implant placement) (figure1).

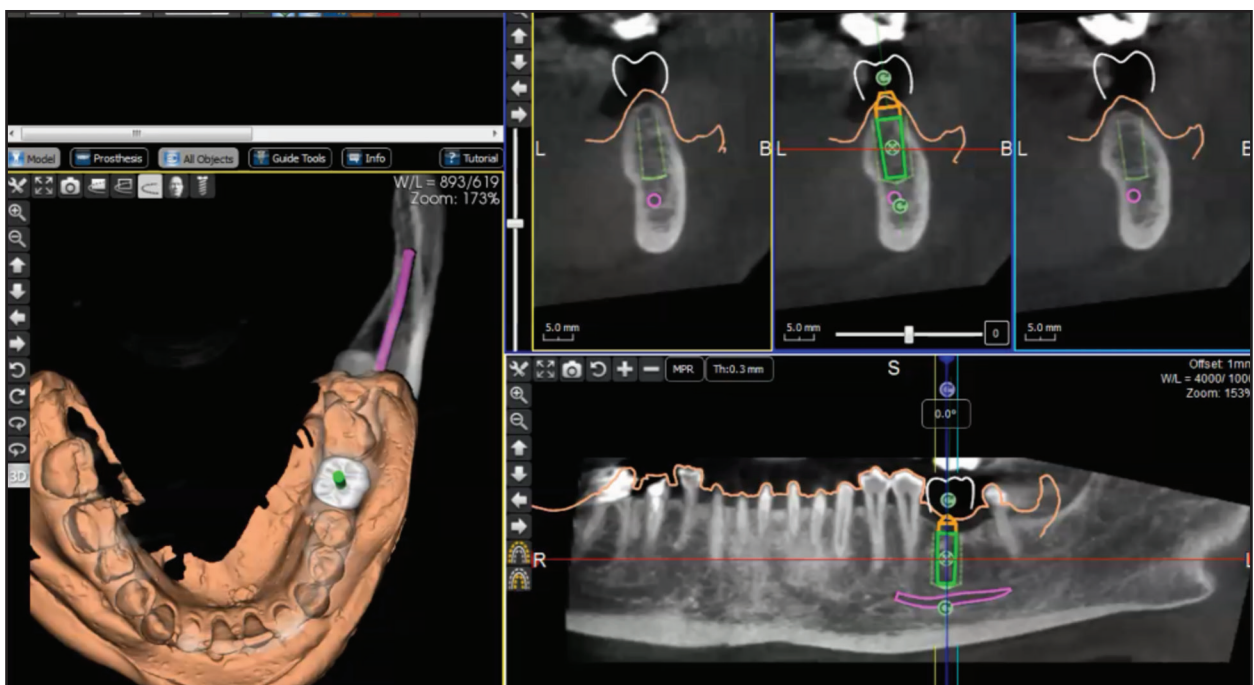


Figure (1) Virtual prosthetic driven implant placement.

Using CAD software, the splitting guide was designed taking into consideration the height of the piezo-surgery tip. Implant guide was designed with no buccal flange to accommodate the splitted ridge expansion in buccal direction and have a good seating on the modified ridge (figure 2). Then both guides were 3D printed.

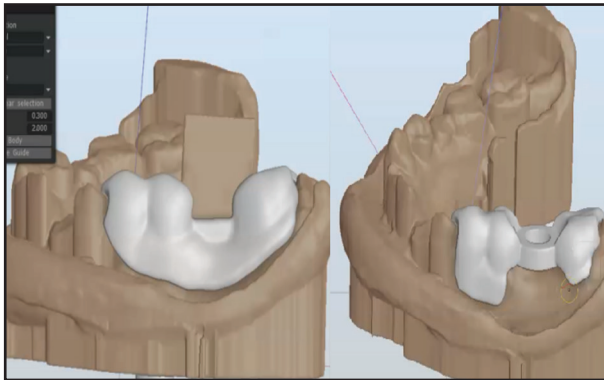


Figure (2) Splitting and implant guides designed at CAD software.

**Surgical Steps:** Platelet-rich fibrin (PRF) preparation is done by centrifugation of 10 ml of patient's blood at 3000 revolutions per minute (rpm) for 10 minutes. PRF was then separated from other layers, to be applied in the splitted area.

After local anesthesia, the first surgical stent designed for splitting was placed, drilling and insertion of retention pin was done in cases with free end saddle. While in bounded cases, the guide

was totally teeth supported.

Crestal incision and crestal corticotomy using piezosurgery was performed through the surgical guide, also vertical osteotomies on the buccal plate at proximal ends of the crestal corticotomy was done 2 mm proximal to neighboring teeth under copious sterile saline irrigation.

The second surgical Guide designed for drilling was placed. The buccolingual bony walls were expanded using expanders with successive sizes according to the planned implant diameter. Successive Osteotomy was done through the second surgical guide (figure 3). Implants were placed immediately in the osteotomy site while maintaining a primary stability greater than 35 N.

The remaining bone gap was filled and covered with PRF particles and membrane respectively. Then tension free suturing was done to allow secondary healing.

**Postsurgical phase:** All patients were examined for any complications or pain using visual analogue scale (VAS) and edema scale. Implant stability was measured 6 months postoperatively with the Osstell device.

Fusion was performed between preoperative and immediate postoperative CBCT to compare buccolingual dimensions and to assess deviation from virtual plan. After six months postoperative CBCT scans were done to assess marginal bone around the implant.

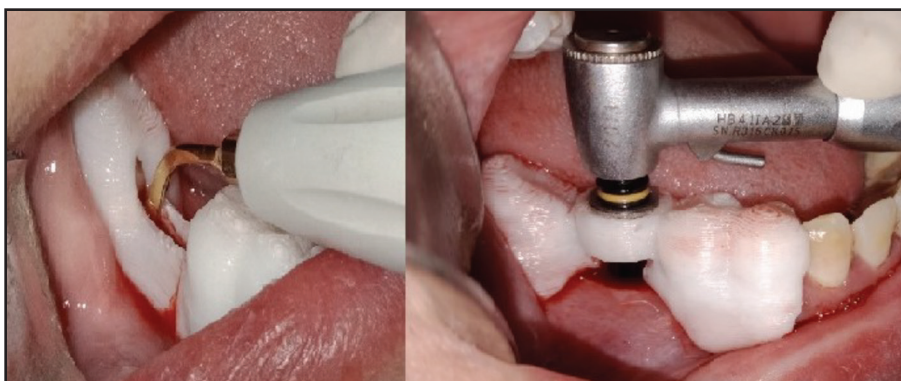


Figure (3) Corticotomy using piezosurgery and sequential drilling.

### RESULTS

6 Female patients completed this study. The age ranged between 36-50 (mean  $43\pm6$ ) years old. Ten dental implants were placed simultaneously with split procedure (2 in the maxilla, 8 in the mandible). Implant dimensions ranged from (3.5 to 5) mm for width and (9.5 to 11.5) mm. for length.

All the surgical sites healed with minimal patient discomfort; there were moderate to mild pain and edema which significantly subsided within first few days postoperatively, no persistent numbness, paresthesia, infection or other complications were reported.

B-L dimensions significantly increased postoperatively. Mean B-L width gain range was 2.1-3.8mm (mean  $3\pm0.6$  mm) (figure 4). While marginal bone loss at buccal and lingual aspects after 6 months range was 0.5-2.5mm, mean ( $1.3\pm0.76$ ) (figure 5).

Regarding surgical guide accuracy, mean coronal deviation from virtual planned implant position was  $1.6\pm1.2$  mm, mean apical deviation was  $2.2\pm1.6$ mm and mean angle deviation was  $5.3\pm2.4$  degrees. Regarding implant stability after 6 months postoperative follow up it ranged between 66.5-75 mean ( $70.7\pm2.3$ ).

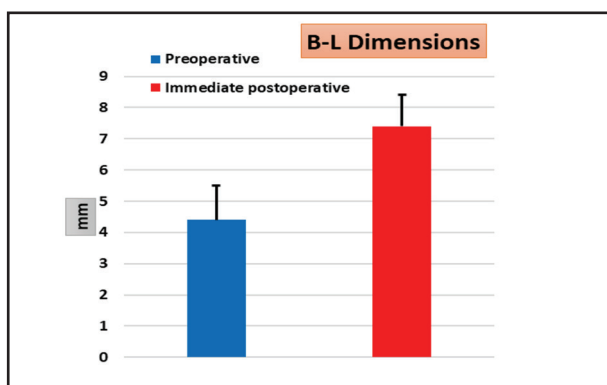


Figure (4) Difference between preoperative and postoperative B-L dimensions.

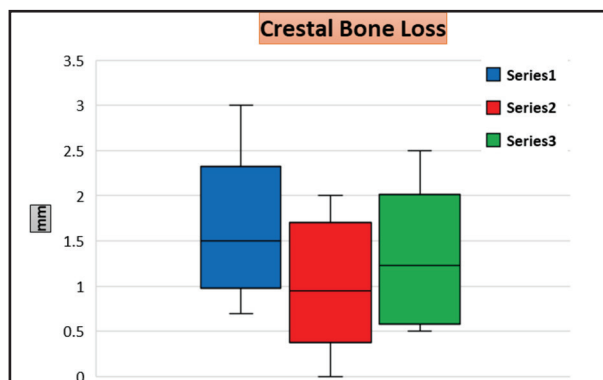


Figure (5) Postoperative crestal bone loss after 6 months at buccal and lingual aspects and mean crestal bone loss.

### DISCUSSION

Endo-osseous dental implant therapy is nowadays a regular and widely accepted treatment modality for replacement of missing teeth<sup>(12)</sup>. In case of insufficient horizontal bony housing, hard tissue augmentation techniques have been suggested. In this study a trial to treat horizontally deficient alveolar ridge was attempted by performing guided flapless ridge splitting to treat the horizontal defect, with simultaneous implant placement in addition to PRF placement.

Clinical and radiographic CBCT evaluation was performed for diagnosis and planning, the position and direction of splitting and drilling were planned on the CBCT software and subtracted from the 3D volume to facilitate transferring the exact computer assisted treatment plan to the fabricated surgical guides. This was performed in all three dimensions; bucco-lingual, mesio-distal and apico-coronal directions to enable optimization of splitting site, implant position, angle, diameter and length<sup>(13)</sup>.

Mid crestal incision was performed without flap reflection, only slight elevation of incision edges. This provided better vascularity, preservation of buccal bone plates and better bone healing, as periosteum remains attached to bone<sup>(14)</sup>.

Corticotomy was performed through splitting guide, this allowed optimization of split site and



direction to be ideally positioned at mid-crest providing adequate buccal plate thickness to avoid its fracture. Using piezoelectric device aided in performing the corticotomy in a rapid atraumatic way and less bleeding providing better visibility and improving patient comfort and acceptance<sup>(15)</sup>. Owing to flapless technique no buccal plate fracture or loss occurred which is a common complication in ridge splitting technique<sup>(16)</sup>.

Initial osteotomy was performed through the implant guide followed by root form expanders, and sequential drilling through the guide after expansion. This could be achieved owing to the open buccal flang in the guide design.

Proper healing was noticed after 2 weeks, no infection, or wound dehiscence or any other complications. This may be due to PRF membrane effect on acceleration and enhancement of soft tissue healing as proved by another study<sup>(17)</sup>. Pain and swelling were ranging between Moderate to mild or no pain nor swelling, with significant decrease along the first few days this may be due to the flapless technique using piezo-surgery which allows soft tissue preservation<sup>(18)</sup>.

Comparing preoperative and postoperative bucco-lingual dimensions, the increase of bucco-lingual horizontal dimensions was  $3\pm 0.6$  mm (2.1-3.8)mm. Similar results were proven in a systematic review that was made in 2015 to assess the dimensional changes after ridge splitting, mean horizontal dimensional changes was 3.19 mm ( 2.00 - 4.03) mm this was similar to another study<sup>(19)</sup>. Bucco-lingual marginal bone loss (MBL) after 6 months follow up ranged between 0.5-2.5 (mean  $1.3\pm 0.76$ ) this may be due to flapless technique, as agreed by another research<sup>(20)</sup>.

Regarding surgical guide accuracy, mean coronal deviation from virtual implant was  $1.4\pm 0.6$  average (0.5-2.1) mm. This deviation was nearly similar to that reported by other authors<sup>(20,21)</sup>. Mean apical deviation from virtual implant was  $1.7\pm 0.4$  average (0.8-2.2) mm. This deviation was near

to that reported by other studies<sup>(22-25)</sup>. Mean angle deviation from virtual implant was  $5.3\pm 2.4$  average (2.3-9.4) mm. That was near to that reported by another study<sup>(26)</sup>.

## CONCLUSION

Computer guided flapless ridge splitting with PRF, is a successful technique for augmenting narrow alveolar ridges. Rehabilitation of long standing edentulism and implant placement can be performed with relative ease, precision and accuracy. Flapless ridge split technique is simple and predictable with satisfactory results, minimal morbidity and high patient acceptance.

## REFERENCES

1. Kim JY. The implant positioning guide and the stent: part I. *Dent Implantol Update*. 2009; 20:57-64.
2. Araújo MG, Lindhe J. Ridge alterations following tooth extraction with and without flap elevation: An experimental study in the dog. *Clin Oral Implants Res*. 2009; 20: 545-9.
3. Avila-Ortiz G, Elangovan S, Kramer KWO, Blanchette D, Dawson DV. Effect of alveolar ridge preservation after tooth extraction: A systematic review and meta-analysis. *J Dent Res*. 2014;93:950-8.
4. Van Der Weijden F, Dell'Acqua F, Slot DE. Alveolar bone dimensional changes of post-extraction sockets in humans: A systematic review. *J Clin Periodontol*. 2009; 36: 1048-58.
5. Horváth A, Mardas N, Mezzomo LA, Needleman IG, Donos N. Alveolar ridge preservation. A systematic review. *Clin Oral Investig*. 2013; 17: 341-63.
6. Liu J, Kerns DG. Suppl 1: Mechanisms of Guided Bone Regeneration: A Review. *The open dentistry journal*. 2014; 8: 56-65.
7. Altıparmak N, Akdeniz SS, Bayram B, Gulsever S, Uckan S. Alveolar Ridge Splitting Versus Autogenous Onlay Bone Grafting: Complications and Implant Survival Rates. *Implant Dent*. 2017; 26: 284-7.
8. Laster Z, Rachmiel A, Jensen OT. Alveolar width distraction osteogenesis for early implant placement. *J Oral Maxillofac Surg*. 2005; 63: 1724-30.

9. Hennes P. Piezoelectric Bone Surgery: A Review of the Literature and Potential Applications in Veterinary Oromaxillofacial Surgery. *Front Vet Sci.* 2015; 2:1–7.
10. Materials C, Clinic MS, Luka B. use of platelet rich fibrin in maxillofacial surgery. *Cont. Mater.* 2016; 1:45–50.
11. Bassetti, M. A., Bassetti, R. G., & Bosshardt, D. D. The alveolar ridge splitting/expansion technique: a systematic review. *Clin. Oral Implants Res.* 2016; 27:310-24.
12. Alghamdi H. S. Methods to Improve Osseointegration of Dental Implants in Low Quality (Type-IV) Bone: An Overview. *J func biomat.* 2018; 9: 7-15.
13. Greenstein G, Cavallaro J. The relationship between biological concepts and fabrication of surgical guides for dental implant placement. *Compend Contin Edu Dent.* 2007; 28:196-204.
14. Jensen, O.T., Cullum, D.R. & Baer, D. Marginal bone stability using 3 different flap approaches for alveolar split expansion for dental implants: a 1-year clinical study. *J. Oral Maxillofac. Surg.* 2009; 67: 1921–30.
15. Brugnami, F., Caiazzo, A. & Mehra, P. Piezo- surgery-assisted, flapless split crest surgery for implant site preparation. *J Maxillofac Oral Surg.* 2014; 13:67–72.
16. Holtzclaw, D.J., Toscano, N.J. & Rosen, P.S. Reconstruction of posterior mandibular alveolar ridge deficiencies with the piezoelectric hinge- assisted ridge split technique: a retrospective observational report. *J. Periodontol.* 2010; 81: 1580–6.
17. Kulkarni MR, Thomas BS, Varghese JM, Bhat GS. Platelet- rich fibrin as an adjunct to palatal wound healing after harvesting a free gingival graft: A case series. *J Indian Soc Periodontol* 2014; 18: 399-402
18. Pavlíková G, Foltán R, Horká M, Hanzelka T, Borunská H, Šedý J. Piezosurgery in oral and maxillofacial surgery. *Int. J. Oral Maxillofac Surg.* 2011; 40:451-7.
19. Dohiem MM, Nassar HI, El Charkawi H. Bone changes in ridge split with immediate implant placement: A systematic review. *Future Dent J* 2015; 1:6-12.
20. Mounir M, Beheiri G, El-Beialy W. Assessment of marginal bone loss using full thickness versus partial thickness flaps for alveolar ridge splitting and immediate implant placement in the anterior maxilla. *Int. J. Oral Maxillofac. Surg.* 2014; 43: 1373-80.
21. Di Giacomo GA, Cury PR, de Araujo NS, Sendyk WR, Sendyk CL. Clinical application of stereolithographic surgical guides for implant placement: preliminary results. *J Periodontol.* 2005; 76:503-7.
22. Farley NE, Kennedy K, McGlumphy EA, Clelland NL. Split- mouth comparison of the accuracy of computer-generated and conventional surgical guides. *Int J Oral Maxillofac Implants.* 2013; 28:563-72.
23. Valente F, Schioli G, Sbrenna A. Accuracy of computer-aided oral implant surgery: a clinical and radiographic study. *Int J Oral Maxillofac Implants.* 2009; 24:234-42.
24. Schneider D, Marquardt P, Zwahlen M, Jung RE. A systematic review on the accuracy and the clinical outcome of computer- guided template-based implant dentistry. *Clin Oral Implants Res.* 2009; 20:73-86.
25. D’Haese J, Van De Velde T, Komiyama A, Hultin M, De Bruyn H. Accuracy and complications using computer-designed stereolithographic surgical guides for oral rehabilitation by means of dental implants: a review of the literature. *Clin Implant Dent Relat Res.* 2012; 14:321-35.
26. Mustafa MN, Khalil AF, Melek LN. Evaluation of piezotomed alveolar ridge splitting with stereolithographic surgical guide for implant placement (clinical study). *Futur Dent J.* 2017; 3:47–54.