

Pediatric dentistry and orthodontics Issue (Pediatric Dentistry, Orthodontics)

4-1-2021

Clinical and Radiographic Assessment of Propolis and Propolis Mixed with Chitosan Effect on Pulp of Primary Molars Versus Formocresol: A Randomized Controlled Trial

Rawda Hassan

Teaching Assistant of Pediatric Dentistry, Faculty of Dentistry, Misr International University.,
radwa.waguih@miuegypt.edu.eg

Mohamed Mostafa

Associate Professor of Pedodontics and Oral Health, Faculty of Dental medicine for Girls, AlAzhar University., dr.farouz00@gmail.com

Wael Darwish

Associate Professor, Department of Polymers and Pigments Chemical Industries Research Division, National Research Centre, waeldarwish78@yahoo.com

Noha Metwally

Lecturer of Pedodontics and Oral Health, Faculty of Dental medicine for Girls, AlAzhar University.,
noha_bridan@hotmail.com

Follow this and additional works at: <https://azjd.researchcommons.org/journal>



Part of the [Other Dentistry Commons](#)

How to Cite This Article

Hassan, Rawda; Mostafa, Mohamed; Darwish, Wael; and Metwally, Noha (2021) "Clinical and Radiographic Assessment of Propolis and Propolis Mixed with Chitosan Effect on Pulp of Primary Molars Versus Formocresol: A Randomized Controlled Trial," *Al-Azhar Journal of Dentistry*. Vol. 8: Iss. 2, Article 20.
DOI: <https://doi.org/10.21608/adjg.2021.47854.1314>

This Original Study is brought to you for free and open access by Al-Azhar Journal of Dentistry. It has been accepted for inclusion in Al-Azhar Journal of Dentistry by an authorized editor of Al-Azhar Journal of Dentistry. For more information, please contact yasmeenmahdy@yahoo.com.



Clinical and Radiographic Assessment of Propolis and Propolis Mixed with Chitosan Effect on Pulp of Primary Molars Versus Formocresol: A Randomized Controlled Trial

Rawda W. Hassan ^{1*}, Mohamed H. Mostafa ², Wael M. Darwish³, Noha I. Metwally ⁴

Codex : 20/21.04

azhardentj@azhar.edu.eg

<http://adjg.journals.ekb.eg>

DOI: 10.21608/adjg.2021.47854.1314

Pediatric Dentistry & Orthodontics
(Pediatric Dentistry, Orthodontics)

ABSTRACT

Purpose: To evaluate clinically and radiographically the postoperative success of Propolis, Propolis mixed with Chitosan and Formocresol in pulpotomy procedure for primary molars. **Materials and Methods:** 30 Primary molars in 10 patients were selected according to the inclusion criteria. In this study pulpotomy was carried out on 30 molars and depending on the type of radicular pulp medicament, the molars were divided randomly and equally into three groups: Group I (formocresol group), Group II (Propolis and Chitosan mixture group) and Group III (Propolis group). Clinical follow up was done after 1, 3 and 6 months. Periapical radiographs also were taken at 1, 3 and 6 months follow up visits. **Results:** No statistically significant difference between groups in the overall cumulative clinical or radiographic success at follow up visits P value \leq 0.05 **Conclusion:** Propolis mixed with Chitosan can be considered as a good natural alternative to formocresol in primary molars pulpotomy.

INTRODUCTION

Throughout the years, it has been agreed that the preservation of pulp in primary molars is our aim in order to maintain the space integrity of the dental arches in pediatric patients, in addition to sustaining esthetics prior to the permanent successors' eruption. Pulpotomy has continued to be the best and most common treatment for decayed primary molars with the pulp exposed by removing the inflamed coronal tissue and retaining the tooth ^(1,2).

KEYWORDS

Propolis, Chitosan, Formocresol

- Paper extracted from Master Thesis Titled "Clinical and Radiographic Assessment of Propolis and Propolis Mixed with Chitosan Effect on Pulp of Primary Molars Versus Formocresol: A Randomized Controlled Trial"
- 1. Teaching Assistant of Pediatric Dentistry, Faculty of Dentistry, Misr International University.
- 2. Associate Professor of Pedodontics and Oral Health, Faculty of Dental medicine for Girls, AlAzhar University.
- 3. Associate Professor, Department of Polymers and Pigments Chemical Industries Research Division, National Research Centre
- 4. Lecturer of Pedodontics and Oral Health, Faculty of Dental medicine for Girls, AlAzhar University.

* Corresponding author email: radwa.waguih@miuegypt.edu.eg

The ideal medicament for pulpotomy should be antibacterial, biocompatible, enhances healing of inflamed pulp tissue and does not affect the physiological root resorption of teeth. Formocresol has been long used as the appropriate pulp medicament in pulpotomy of primary molars^(3,4). Possible carcinogenic and mutagenic properties of formocresol steered its restricted usage as a pulpotomy remedy⁽⁵⁾.

Complications and side effects due to the use of man-made drugs have paved the way for the natural products for pharmacotherapeutic purposes. An alternative to gold standard drugs could be seen in propolis which is easy to use, patient friendly and easily accessible. Propolis, is a natural resinous substance, collected by honey bees that possesses anti-inflammatory, antibacterial, antioxidant, antiaging and aids in wound healing. Hence, propolis can be used as pulpotomy medicaments, plus, a mouth rinse, anti-cariogenic agents, in endodontic therapy as root canal irrigants and intracanal medicaments and also used as storage media for avulsed teeth⁽⁶⁾.

One of the new and promising biomaterials being used in dentistry is chitosan⁽⁷⁾. Chitosan and its derivatives have excellent biocompatibility, non-toxicity to human beings, biodegradability, reactivity of the deacetylated amino groups, selective permeability, polyelectrolyte action, antimicrobial activity, anti-inflammatory and wound healing⁽⁸⁾. A study was conducted targeting the production of propolis into biodegradable chitosan chips and assessment of its efficiency as a pulpotomy medicament after being applied in dogs in comparison with the most commonly used formocresol preparation. It was found that the finest propolis chip design has caused less pulpal inflammation compared to formocresol with the formation of calcified tissue in all specimens⁽⁹⁾.

Previous studies experimenting on chitosan and propolis chips were performed in vitro and in vivo on animals and scarce human clinical trials, that is why we carried out this study on patients to evaluate the clinical and radiographical success of propolis and chitosan on pulp of primary molars.

MATERIALS AND METHODS

Patient selection

This power analysis was based upon the results of a study which reported the clinical success rate of Formocresol and Propolis to be (94.4% and 88.2%, respectively after 6 months⁽¹⁰⁾. However, no literature had reported the success rate of Propolis + Chitosan, so it was assumed that its clinical success is 50%. According to the previous rates; the effect size was found to be (1.28), using alpha (α) level of 0.05 (5%) and Beta (β) level of 0.20 (20%) i.e. power = 80%. The minimum estimated sample size was found to be 8 cases. To compensate for a drop-out rate of 20%, the number was increased to 10 cases comprising 30 teeth. Sample size calculation was performed using IBM® SPSS® SamplePower® Release 3.0.1

In this study 10 participants having 30 teeth were included that fulfilled the following criteria; ranging from 4-6 years old, patient and parent cooperation, absence of any systemic disease that can contraindicate pulp therapy (Diabetes, Autistic, Cerebral Palsy, Mongoloid, Asthma, Allergic reactions to food & drugs, Bleeding diseases), having at least three carious primary molars with nearly equal carious involvement that will possibly require pulpotomy. The selected teeth had the following criteria; asymptomatic with a deep carious lesion, restorable with a stainless steel crown, no tenderness to percussion, no swelling or opening sinus, no pulpal necrosis or infectious exudates after entry into the pulp chamber and attainment of radicular pulp hemostasis after compression with a sterile cotton pellet. In addition, absence of furcal, periapical radiolucency or widened periodontal ligament space, no more than one-third root resorption detected⁽¹¹⁾.

The ethical committee of faculty of dentistry Al Azhar University provided the ethical approval. Informed consent was clarified and discussed before final approval and signature from the parents.

Clinical and radiographic examination:

Before treatment, a detailed medical and dental history was obtained, and then clinical and radiographic examinations were carried out. Periapical radiographs of the teeth considered for treatment in the study were obtained by a standardized paralling technique and an exposure time according to the tooth and quadrant before starting.

Technique of vital pulpotomy

Teeth to be treated were locally anaesthetized using mepecaine, according to weight of each patient. Patients were allowed to wait for 10 min before pulpotomy procedure was carried out; rubber dam was used to isolate the designated tooth. Caries was cleaned and coronal access was extended using a sterile No. 330 high speed bur with water spray for proper deroofting of the pulp chamber. A sharp sterile spoon excavator was used for coronal pulp amputation. Multiple sterile cotton pellets moistened with saline were adapted over the pulp stumps and light pressure was applied for 2 -3 minutes to obtain hemostasis ⁽¹¹⁾. Extreme bleeding during pulp amputation or non-vital teeth were excluded from this study. According to the type of remedy the pulp was treated, then a final restoration of Intermediate Restorative material was placed with good sealing and stainless steel crowns were placed a final restoration ⁽¹¹⁾.

Materials

The teeth were divided into three groups, 10 teeth each; first group with formocresol (Pyrax Polymers, Krishan Kuni, India), second group with Propolis and Chitosan Chip Chitosan (medium molecular weight ~180-200 kDa) was a product from Sigma Co., Germany) and third group with Propolis solution (Bee Propolis Imtenan Pharma Cairo, Egypt). Absolute ethyl alcohol was procured from BDH, UK. Ultra-pure from Milli-Q system was used in all experiments.

Propolis-chitosan nanocomposites were prepared by a modified solvent diffusion method under optimized conditions in the laboratory of National research center. Propolis extract (ethanol) were prepared according to a recent study with same propolis origin ⁽¹²⁾. Intermediate Restorative Material (IRM ® Dentsply Sirona, Australia, New Zealand) was applied as base filling all the cavity, then all teeth were restored with stainless steel crowns (3M ESPE St Paul, USA) using Glass ionomer cement (R&D NOVA GLASS-L, Karatay Konya, Turkey)

Sample Grouping

The teeth were divided randomly and equally into three groups as follows: (Group I, Group II and Group III).

Group I Group I (Formocresol group) (10 primary molars)

Pulp chamber was cleaned with physiologic saline. A cotton pellet dipped in formocresol squeezed and was placed on the pulp tissues for 5 minutes; after hemorrhage control a freshly mixed Intermediate Restorative Material base was applied.

Group II (Propolis and Chitosan mixture group) (10 primary molar)

Pulp chamber was cleaned with physiologic saline. Propolis and Chitosan Chip was placed on the pulp tissue and condensed well then a freshly mixed Intermediate Restorative Material base was applied.

Group III (Propolis group) (10 primary molar)

Pulp chamber was cleaned with physiologic saline. A cotton pellet dipped in Propolis solution squeezed and was placed on the pulp tissues for 2 minutes. The Propolis cotton pellet was removed from the pulp chamber and a freshly mixed Intermediate Restorative Material base was applied.

- Stainless steel crowns were used to restore all teeth, using Glass ionomer cement and post-operative radiograph was taken.

- Children's parents were instructed to contact the investigator if any adverse signs or symptoms occurred between follow up visits.

Follow up:

Recall visits were established with the children for clinical and radiographic examination after 1, 3 and 6 months; for the occurrence of any signs and symptoms in the treated teeth. This clinical assessment was done at each follow up visit; data were recorded in a patient evaluation form. Periapical radiographs also were taken for all treated teeth using the same technique as mentioned before for preoperative radiographs.

Clinical evaluation criteria ⁽¹³⁾: Teeth showing the following criteria were considered as success;

- No pathology
- Normal functioning.
- Mobility ≤ 1 mm

Radiographic evaluation criteria: Teeth showing the following criteria were considered as success;

- Normal tapering of the internal root canal from chamber to the apex.
- No loss of periodontal ligaments or lamina dura.
- No internal or external resorption.
- No radiolucency.

Statistical analysis

Qualitative data were presented as frequencies and percentages. Friedman's test was used to compare between the three groups as well as to study the changes by time within each group. The significance level was set at $P \leq 0.05$. Statistical analysis was performed with IBM SPSS Statistics for Windows, Version 23.0. Armonk, NY: IBM Corp.

RESULTS

There was no statistical significance difference between groups in the overall cumulative clinical success at 1, 3 and 6 months. Also Radiographic evaluation showed no statistically significant difference between groups in the overall cumulative success at 1, 3 and 6 months.

Clinical Evaluation

At first visit; all cases were asymptomatic, so no statistical comparison was performed. After 1, 3 as well as 6 months; clinical evaluation scores of the three groups showed no statistically significant difference (P -value = 0.135, Effect size = 0.2) for each time period, respectively. Figure (1) Table (1)

Table (1): Descriptive statistics and results of Friedman's test for comparison between clinical evaluation at different follow up periods within each group

Time	Propolis (n = 10)		Propolis + Chitosan (n = 10)		Formocresol (n = 10)	
	n	%	n	%	n	%
First visit						
Asymptomatic	10	100	10	100	10	100
Slight discomfort	0	0	0	0	0	0
1 month						
Asymptomatic	10	100	8	80	10	100
Slight discomfort	0	0	2	20	0	0
3 months						
Asymptomatic	10	100	8	80	10	100
Slight discomfort	0	0	2	20	0	0
6 months						
Asymptomatic	10	100	8	80	10	100
Slight discomfort	0	0	2	20	0	0
P-value	Not computed		0.112		Not computed	
Effect size (w)			0.2			

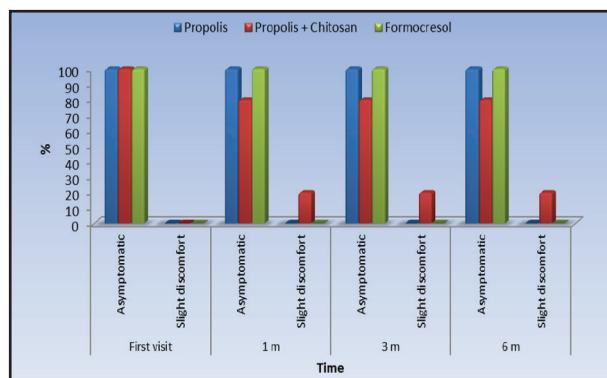


Figure (1): Bar chart representing clinical evaluation in the three groups, group I (formocresol), group II (propolis and chitosan mixture) and group III (propolis) at 1, 3 and 6 months.

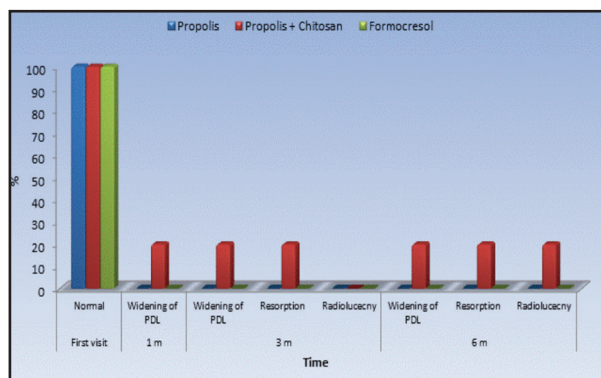


Figure (2): Bar chart representing radiographic findings in the three groups, group I (formocresol), group II (propolis and chitosan mixture) and group III (propolis) at 1, 3 and 6 months.

Radiographical Evaluation

At first visit as well as after 1 month; all cases showed 100% radiographic success, so no statistical comparison was performed. After 3 as well as 6 months; there was no statistically significant difference between the three groups (P -value = 0.135, Effect size = 0.2) for each time period, respectively. Figures (2,3) Table (2)

Table (2): Descriptive statistics and results of Friedman's test for comparison between prevalence of widened PDL or loss of Lamina Dura at different follow up periods within each group

Time	Propolis (n = 10)		Propolis + Chitosan (n = 10)		Formocresol (n = 10)	
	n	%	n	%	n	%
First visit						
Normal	10	100	10	100	10	100
Widening of PDL	0	0	0	0	0	0
1 month						
Normal	10	100	8	80	10	100
Widening of PDL	0	0	2	20	0	0
3 months						
Normal	10	100	8	80	10	100
Widening of PDL	0	0	2	20	0	0
6 months						
Normal	10	100	8	80	10	100
Widening of PDL	0	0	2	20	0	0
P-value	Not computed		0.112		Not computed	
Effect size (w)	Not computed		0.2		Not computed	

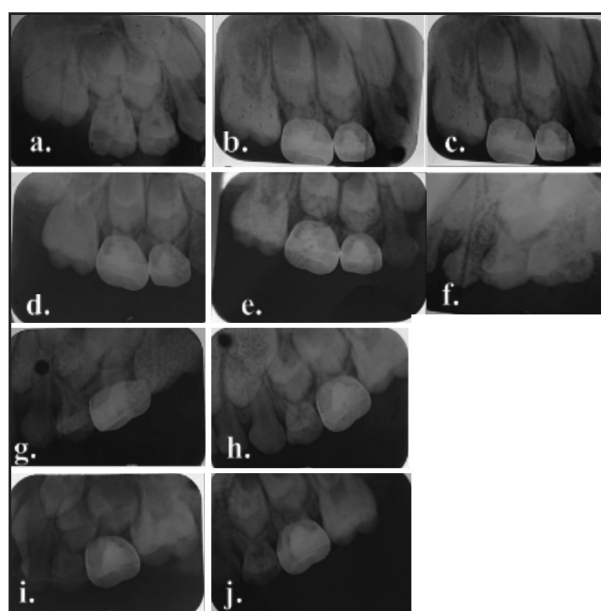


Figure (3): **a.** Preoperative periapical radiograph showing caries present in upper right first and second primary molars. **b.** Postoperative periapical radiograph showing upper right first (formocresol) and second (propolis with chitosan mixture) primary molars. **c.** Periapical radiograph showing upper right first and second primary molars at 1 month follow up. **d.** Periapical radiograph showing upper right first and second primary molars at 3 month follow up. **e.** Periapical radiograph showing upper right first and second primary molars at 6 month follow up. **f.** Preoperative periapical radiograph showing caries in upper Left second primary molar. **g.** Postoperative Periapical radiograph showing upper left second (propolis) primary molar. **h.** Periapical radiograph showing upper left second primary molar at 1 month follow up. **i.** Periapical radiograph showing upper left second primary molar at 3 month follow up. **j.** Periapical radiograph showing upper left second primary molar at 6 month follow up.

DISCUSSION

The usage of natural products in the therapeutic field has experienced remarkable advancement in latest studies across the years; hence, the use of biocompatible materials has become a major area of importance in recent dentistry. They are considered a viable replacement to formocresol but still under research ⁽¹⁴⁾. In a study to investigate the mutagenicity of formocresol in Buckley's formula; there was no statistical significance in both control and treated groups except for one case where Buckley's formula was found mutagenic in one child. This study paved the path for the current clinical researches in the hope of seeking another more biocompatible, natural and harmless material instead of formocresol ⁽⁵⁾.

Formocresol has been used for years as the main pulpotomy medicament in primary molars due to its many advantages; having germicidal ability and its ability to fix the coronal pulp tissue of the root canals in pulpotomy of primary molars ⁽¹⁵⁾. Formocresol has the ability not to induce internal resorption in teeth as well as not affecting the physiological resorption of teeth during eruption of permanent successors ⁽¹⁵⁾. Several reports explained the biological benefits of chitosan effects on wound healing due to it being biocompatible, biodegradable, having a hemostatic activity, anti-infectional activity and property to hasten healing of wounds ⁽¹⁶⁾. This may be attributed to the N-acetyl glucosamine of chitosan, which possesses a positively charged surface that produces thrombosis and blood coagulation.

It was showed that propolis allows pulp regeneration as well as decreasing inflammation and the degenerative process ⁽¹⁷⁾. However, in this study there were two cases that failed radiographically, that could be attributed to some of propolis components breaking down leading to some focal area of inflammation that may cause some root resorption ⁽¹⁸⁾. Also, other studies reveal its ability to increase healing of wounds which may lead to reduction in the inflammation process and acceleration in the

healing of radicular pulp tissue after amputation of coronal pulp and this may explain the asymptomatic clinical findings in the current study ⁽¹⁸⁾.

Propolis showed an inhibitory effect on cocci and gram-positive rods. It was found that propolis has an antimicrobial effect on *S. mutans*, *S. sanguis* ⁽¹⁹⁾. These antimicrobial properties are attributed to the flavonoid content and specially the presence of pinocembrin, galangin and pinobanksin.

In a study it was revealed that the positively charged chitosan interacted with the negative charge of bacterial cell elevating permeability of bacterial cell, resulting in leakage of intercellular components and cell death. In addition, chitosan can attach to DNA and inhibit mRNA synthesis through nucleus of microorganism and interfere with mRNA and synthesis of protein, correlated with capability of wound healing which may explain the results of our study that has shown no statistical significance between all groups ⁽²⁰⁾. In a recent study chitosan was capable of decreasing bacterial and fungal growth; where the presence of normal PDL in this study radiographs could be attributed to explaining as well the absence of any loss of lamina dura and neither internal or external resorption occurring too ⁽²¹⁾.

CONCLUSION

Propolis and chitosan chips were recognized to be an acceptable alternative natural pulpotomy medicament for primary molars.

RECOMMENDATIONS

It is recommended to perform further clinical trials on Propolis chitosan chips with a larger number of participants.

DECLARATION STATEMENT

No funds was received for this study, and there was no conflict of interest during the course of the study.

REFERENCES

1. Ansari G, Morovatic SP, Asgary S. evaluation of four pulpotomy techniques in primary molars: A randomized controlled trial. *IEJ* 2018; 13(1): 7-12
2. Bossù M, Iaculli F, Di Giorgio G, Salucci A, Polimeni A, Di Carlo S. Different Pulp Dressing Materials for the Pulpotomy of Primary Teeth: A Systematic Review of the Literature. *J Clin Med*. 2020;9(3): 838.
3. Vargas KG, Fuks AB, Peretz B. Pediatric Endodontics, Current concepts in pulp therapy for primary and young permanent teeth, 1st. ed. Switzerland, Springer International Publishing 2016; 51-70.
4. Shirvani A, Asgary S. Mineral trioxide aggregate versus formocresol pulpotomy: A systematic review and meta-analysis of randomized clinical trials. *Clinical Oral Investigations*, 2014; 18 (4): 1023-30.
5. Chandrashekhar S, Shashidhar J. Formocresol, still a controversial material for pulpotomy: a critical literature review. *J Rest Dent* 2014; 2: 114-24.
6. Malhotra S, Gupta VK. Use of Propolis in Pediatric Dentistry. *J Dent Allied Sci* 2014; 3:93-8.
7. Kotb, MMA, Ragab, GA, Fathy, MZ, Haggag, U, Nesreen M Safwat. Radiologic, Ultrasonic and pathological assessments of locally applied Chitosan on promotion of experimentally induced tibial fracture healing in rats. *J of Vet Med Res* 2020; 27(1): 23-36.
8. Kravanja G, Primožič M, Knez Ž, Leitgeb M. Chitosan-based (Nano) materials for Novel Biomedical Applications. *Molecules*. 2019; 24(10): 1960.
9. Balata GF, Abdelhady MIS, Mahmoud GM, Matar MA, Abd EL-Latif AN. Formulation of Saudi propolis into biodegradable chitosan chips for vital pulpotomy. *Current Drug Delivery*, 2018; 15: 97-109.
10. Alolofi, H., El-Sayed, M. & Taha, S. Clinical and radiographical evaluation of propolis and thymus vulgaris extracts compared with formocresol pulpotomy in human primary molars. *BDJ* , 2016.
11. Abuelniel G, Eltawil S. Clinical and radiographic assessment of pulpotomy materials in primary molars. *EDJ* 2018; 64: 951- 62.
12. Soufy, Hamdy , El-Beih, Nadia , Nasr, Soad , El-Aziz, Tamer , Khalil, Fathia et al. Effect of Egyptian propolis on cryptosporidiosis in immunosuppressed rats with special emphasis on oocysts shedding, leukogram, protein profile and ileum histopathology. *APJTM*, 2017; 03: 253-62.
13. Zurn D, Seale NS. Light-cured calcium hydroxide vs formocresol in human primary molar pulpotomies: a randomized controlled trial. *Pediatr Dent* 2008; 30: 3441.
14. Saikiran KV, Kamathan R, Sahiti PS, Nuvvula S. Pulpotomy medicaments in primary teeth. A literature review of natural alternatives. *SRM J Res Dent Sci* 2018; 9:181-5.
15. Kirtaniya BC, Gupta KK, Gaur A, Sharma A. Formocresol Pulpotomy: Saviour of primary tooth, *Indian Journal of Dental Sciences*, 2015; 3(7): 111-4.
16. Abbaszadeh A, Rajabzadeh A, Zarei L. Effect of Chitosan/Propolis Biodegradable Film on full thickness wound healing in rats. *IJVS* 2019;14(1): 9-16
17. Przybyłek I, Karpiński TM. Antibacterial Properties of Propolis. *Molecules*. MDPI 2019; 24(11): 2047.
18. Hugar SM, Kukreja P, Hugar SS, Gokhale N, Assudani H. Comparative Evaluation of Clinical and Radiographic Success of Formocresol, Propolis, Turmeric Gel, and Calcium Hydroxide on Pulpotomized Primary Molars: A Preliminary Study. *Int J Clin Pediatr Dent* 2017;10(1):18-23.
19. Anjum SI, Ullah A, Khan KA, et al. Composition and functional properties of propolis (bee glue): A review. *Saudi J Biol Sci*. 2019; 26(7): 1695-703.
20. Faiek AM, Elmalt MA, Ali HAA, Mohamed E AR. Evaluation of antimicrobial efficacy of chitosan as root canal irrigant on *Enterococcus Faecalis*. *ADJ- for Girls*, 2019; 6(4): 437-43.
21. Mousavi SA, Ghotaslou R, Kordi S, Khoramdel A, Aeenfar A, Kahjough ST, et al. Antibacterial and antifungal effects of chitosan nanoparticles on tissue conditioners of complete dentures. *Biomac* 2018; 18: 881- 5.