

Pediatric dentistry and orthodontics Issue (Pediatric Dentistry, Orthodontics)

7-1-2021

Clinical Evaluation of Laser Versus Conventional Cavity Preparation Methods in Primary Teeth Restorations

Alaa El-Dehna

Assistant Lecturer of Pedodontics and Oral Health, Faculty of Dental Medicine for Girls, Al-Azhar University, Cairo, Egypt, alaadentist@gmail.com

Mohamed Alyaski

Professor of Operative Dentistry & Dean of Faculty of Dentistry, Sinai University, Egypt., alyaski@yahoo.com

Mohammed Mostafa

Associate Professor of Pedodontics and Oral Health, Faculty of Dental medicine for Girls, Al-Azhar University, Cairo, Egypt., mohammedhassan70@yahoo.com

Follow this and additional works at: <https://azjd.researchcommons.org/journal>



Part of the [Other Dentistry Commons](#)

How to Cite This Article

El-Dehna, Alaa; Alyaski, Mohamed; and Mostafa, Mohammed (2021) "Clinical Evaluation of Laser Versus Conventional Cavity Preparation Methods in Primary Teeth Restorations," *Al-Azhar Journal of Dentistry*. Vol. 8: Iss. 3, Article 16.

DOI: <https://doi.org/10.21608/adjg.2021.19274.1202>

This Original Study is brought to you for free and open access by Al-Azhar Journal of Dentistry. It has been accepted for inclusion in Al-Azhar Journal of Dentistry by an authorized editor of Al-Azhar Journal of Dentistry. For more information, please contact yasmeenmahdy@yahoo.com.



Clinical Evaluation of Laser Versus Conventional Cavity Preparation Methods in Primary Teeth Restorations

Alaa M. El-Dehna^{1*}, Mohamed A. Alyaski², Mohammed H. Mostafa³

Codex : 16/21.07

azhardentj@azhar.edu.eg

<http://adjg.journals.ekb.eg>

DOI: 10.21608/adjg.2021.19274.1202

Pediatric Dentistry & Orthodontics
(Pediatric Dentistry, Orthodontics)

ABSTRACT

Purpose: To compare between laser and conventional cavity preparation techniques in children, to assess clinical presentation of bulk fill composite and high viscous glass ionomer restoration. **Materials and Method:** In vivo study included 20 children aged from 4-8 years using split mouth technique (a total of 40 teeth was treated). Group I: 20 teeth treated by turbine. Group II: 20 teeth treated with laser. Each group was subdivided into two subgroups. The teeth were filled with Equia forte in groups IA and IIA or filled with REVEAL HD Bulk composite in groups IB and IIB. **Results:** Results of the study showed that conventional technique need less time than Laser. It also showed higher mean pain score than Laser although it was not significant. Tooth materials displayed excellent clinical evaluation. **Conclusion:** laser minimize the onset of pain during caries removal compared with drilling. A longer treatment time was the main disadvantage of this technique. Equia, and bulk fill composite, showed acceptable clinical performance.

INTRODUCTION

Caries is a modern bacterial disease that destroy dental hard tissues as a result of localized dissolution of these tissues. Removing carious tissues almost done by the use of excavators and burs, these methods sometimes removes the excess of sound tissue (over- preparation), or leave carious tissue (under-preparation). Moreover, the pressure and heat on the pulp, make the removal process is uncomfortable. The vibration, noise, and pain make patients apprehensive. Therefore,

KEYWORDS

Erbium,
Primary teeth,
Equia forte.

- Paper extracted from Doctor Thesis Titled "Clinical and Laboratory Evaluation of Laser Versus Conventional Cavity Preparation Methods in Primary Teeth Restorations"

1. Assistant Lecturer of Pedodontics and Oral Health, Faculty of Dental Medicine for Girls, Al-Azhar University, Cairo, Egypt.
2. Professor of Operative Dentistry & Dean of Faculty of Dentistry, Sinai University, Egypt.
3. Associate Professor of Pedodontics and Oral Health, Faculty of Dental medicine for Girls, Al-Azhar University, Cairo, Egypt.

* Corresponding author email: alaadentist@gmail.com

local anesthesia should be employed to overcome the pain and heat especially for children⁽¹⁾.

Currently, minimally invasive treatment concept is gained more acknowledgment by dentists. This concept includes many techniques like chemo-mechanical materials, and lasers. The pedodontist become have effective laser to treat hard and soft tissues of the oral cavity after the entrance of Erbium lasers in the laser family. The Erbium laser characterized by a low pain perception and lack of tissue injury⁽²⁾.

Thermal injury to the pulp caused by mechanical preparation results in neurogenic inflammation, giving rise to pain and a hyperemic increase in pulpal blood flow. Such reactions may be followed by pain and necrosis of the pulp. In contrast, the ablation of tissue by Er,Cr:YSGG reduce that pain perception and conserve the tooth structure. As a result of the numerous advantages of the Erbium lasers especially in decreasing pain, it become safer for children treatment of dental caries⁽³⁾.

On the other hand, the cavities prepared with laser are more appropriate for retention of adhesive materials, as the Scanning Electron Microscope of cavities prepared by laser showed no smear layer, exposure of enamel rods and open dentinal tubules⁽⁴⁾. Consequently, the application of restorative materials in cavities prepared with erbium laser resulted in a better seal and a minimum rate of secondary caries. After thermocycling (TC) less micro-leakage was observed when compared with conventionally prepared cavities⁽⁵⁾.

Furthermore, Cavity preparation is not the only main concern for dentist, choosing the appropriate restoration is also has the same importance for successful result. Silver amalgams are still used but it has several drawbacks especially in primary teeth, because it is dark color and they do not bond to tooth structure. It became non-acceptable to most of parents. An ideal restorative material for primary molars would be biocompatible and with aesthetic color, adhere to tooth structure with no subsequent

marginal leakage, have sufficient physical properties so as not degrade in the mouth and manipulate easily for the practitioner⁽⁵⁾.

The basis of dental technologies progression includes the search for faster and easier restorative procedures while maintaining adhesive efficiency and adequate bond strength. Both of resin-based composites and glass ionomer have been progressed as they considered the backbone of adhesive dentistry for children. Modifications were done in both materials to improve their properties and durability⁽⁶⁾.

MATERIALS AND METHODS

A total of 40 teeth was treated in a group of 20 children aged from 4-7 years using split mouth design. The patients attending outpatient clinic of Pedodontics and Oral Health department, Faculty of Dental medicine for Girls, Al Azhar University. Full detailed treatment plan was explained to the children's parents or caregivers and informed written consents for treatment were obtained prior to treatment. The teeth divided equally into two group (20 teeth for each group) according to caries removal technique. **Group I:** caries removed by conventional mechanical caries removal. **Group II:** teeth were treated with laser.

The main groups were divided into two subgroups according to the filling material used as follow:

Group I

- Subgroup A(n=10) Caries removed by conventional mechanical caries removal & restored by glass ionomer restoration (EQUIA Forte Fill capsules)
- Subgroup B(n=10) Caries removed by conventional mechanical caries removal & restored by bulk fill composite restoration (Reveal HD Bulk Fill Composite)

Group II

- Subgroup A(n=10) Caries removed by laser & restored by glass ionomer restoration
- Subgroup B(n=10) Caries removed laser & restored by bulk fill composite restoration

The materials name, composition, manufacturer and batch number are listed in tab. (1).

Selection criteria

- Children age range from 4-7 years
- Cooperative medically free child
- Each child had two contralateral primary teeth
- Occlusal caries lesions (class I).
- Primary carious teeth with carious enamel or enamel and dentin.
- Teeth were asymptomatic with no clinical evidence of pulp pathosis.

Caries removal procedure:

Cavity preparation was performed in lowers first and second primary molars. Using split mouth design, the caries removed in the lower right molars by laser and then removed from the lower left molars by turbine and excavators. The child was

allowed to settle down for some time before starting the caries removal to minimize its effect on change in the behavior of child during procedure. At the beginning of treatment, no local anesthesia was used to avoid altering pain perception of child. Once the child start annoying from treatment because of pain, anesthesia become mandatory.

Rubber dam was used for adequate isolation, in some case using the rubber dam was not accepted from child, in this situation the restricted isolation should be followed using Super Absorbent Pads and subsequent restoration used in these cases was Equia Fort as it is less sensitive to humidity. In the current study the rubber dam was used with 14 children while anther cases followed restricted isolation.

During preparation the tactile and visual examination with sharp explorer used to assessment removal of caries following the clinical criteria for consistency and texture.

- Group I: the cavities prepared by sharp excavators and dental turbine with water-cooled handpieces.
- Group II: the cavities were prepared with Erbium laser.

Table (1): *The materials used in this study:*

Materials	Composition	Manufacturer	Batch Number
EQUIA® Forte capsules	Powder: Fluoro-aluminosilicate glass, polyacrylic acid powder, surface-treated glass. Liquid: aqueous polyacrylic acid.	GC Corporation Tokyo. Japan	1801263
Dentin Conditioner	Aqueous polyacrylic acid with aluminum chloride	3M™ ketac™	656054
Equia coat.	Nano filled resin matrix combines both conventional & multifunctional MMA photoinitiators. (50% methyl methacrylate and 0.09% camphorquinone).	GC Corporation Tokyo. Japan	1501061
Reveal HD composite	Resins matrix: Bis-GMA, UDMA and Dimethacrylate. Filling: HD inorganic Filler	BISCO, Inc, Schaumburg, IL60193, U.S.A.	1800005251
Select HV Acid Etch	35% high viscosity phosphoric etch with Benzalkonium Chloride (BAC).	BISCO, Inc, 1100W. Irving Park Red. Schaumburg, IL60193, U.S.A.	1800005273
All-Bond Universal	10-Methacryloyloxydecyl dihydrogen phosphate	BISCO, Inc, 1100W. Irving Park Red Schaumburg, IL60193, U.S.A.	1800005212

Restoration of the cavities:

The restoration procedure was performed after removal of caries with either method in two group

- Subgroup IA and IIB: Cavities were prepared by either method, then teeth were filled with Equia Forte packable glass ionomer.
- Subgroup IB and IIB: Cavities were prepared by either method, then teeth were filled with REVEAL HD Bulk composite.

Cavity preparation evaluation:

- Episodes of pain: the degree of pain of each child was assessed, using the universal pain assessment tool.
- Duration of treatment: stopwatch used from the first contact of the drill with the tooth and paused with the last contact.
- Need for anaesthesia: requirement by the participant during or before the treatment to receive local anaesthetic injection in order to avoid feelings of pain caused by dentists used of ablative devices.

Clinical evaluation of restoration

The clinical evaluation of restorations performed using Modified USPHS criteria immediately and after 3 months and 6 months subsequently the restorative procedure.

RESULTS

A. Vivo results

I. Caries removal time

Results of time of caries removal were presented in fig (1).

II. Pain score

Evaluation of pain and patient discomfort was presented in fig (2).

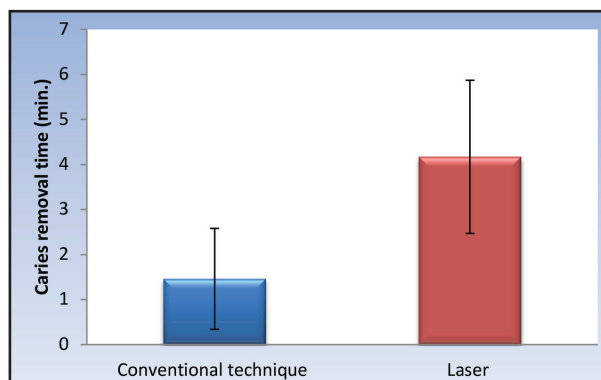


Figure (1): Bar chart representing values for caries removal time in the two groups

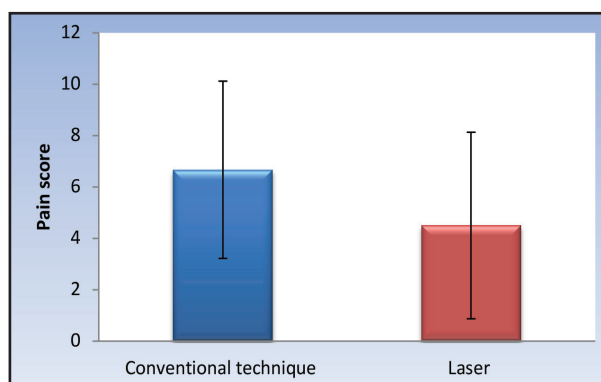


Figure (2): Bar chart representing values for pain scores after using the two caries removal techniques

III. Need for anesthesia

Evaluation of need for anesthesia was presented in fig (3).

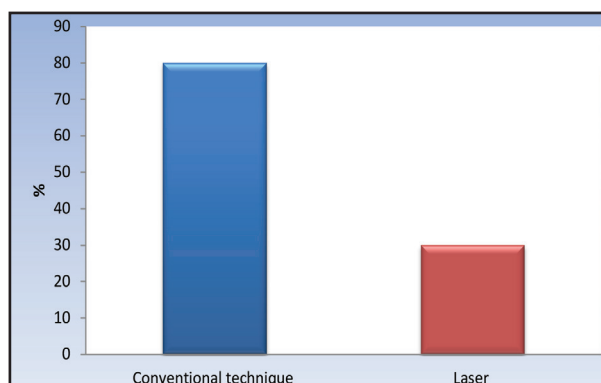


Figure (3): Bar chart representing percentage of subjects who were in need for anesthesia during using the two caries removal techniques

IV. Clinical evaluation

The both materials displayed excellent clinical evaluation and there no statistically significantly between their performance all study period.

According to USPHS criteria, most of restorations (90%) in EQUIA Forte group whether removed by conventional or Laser technique showed (Alpha) score in all USPH criteria. All bulk fill composite restorations (100%) whether removed by conventional or Laser technique showed (Alpha) score through all follow up periods.

Table (1): Descriptive statistics and results of Fisher's Exact test for comparison between secondary caries of the two materials

Time	EQUIA Forte		Bulk Fill		P-value	Effect size (v)
	(n = 10)		(n = 10)			
	N	%	N	%		
Base line						
Alpha	10	100	10	100		NC†
3 months						
Alpha	10	100	10	100		NC†
6 months						
Alpha	9	90	10	100	1.000	0.229
Bravo	1	10	0	0		

DISCUSSION

The negative aspects arising from the use of the traditional bur such as pain, vibration, noise, and risk of accidental damage to soft tissues or pulp during cavity preparation make the dentist sought for other more tolerable instrument⁽⁷⁾. Now the laser systems are being widely used in soft-tissue and hard-tissue surgery in adults and pediatric patients as it considered the prime potential alternative for dental treatment⁽⁸⁾.

The current study discussed the ability of laser to be an alternative method for cavity preparation in pediatric dentistry, as the most of published researches considered it the golden technique. The comparison between the erbium laser and conventional caries removal was manipulated in the current study from multiple aspects like pain perception, need for anesthesia and time required for cavity preparation. Split mouth design is used for standardization.

The first aspect for evaluation was the time needed for both techniques. It is well-known that, the attention span for child is very limited when compared with adult, so the time needed for all-over dental procedure (cavity preparation and restoration) is critical factor and must be taken in consideration. In the current study, the cavity preparation time was significantly longer by using laser when compared with conventional methods.

Without a doubt between all studies^(9,10) the laser always need more time for cavity preparation when compared with high speed turbine. The difference in duration between laser and mechanical preparation is mainly due to differences in mechanism of actions. The turbine removed carious tissue by direct cutting. In contrast, the ablation of enamel by laser occurs through the explosive removal of tissue in a thermo-mechanical event. By overheating the water chromophore (chemical group capable of selective light absorption), the steam pressure within the tissue exceeds the structural strength of the overlying material, micro explosions occur, ejecting particles of fractured material⁽¹¹⁾.

The pain perception is another aspect had been evaluated in the present study. Pain when removing caries is a major complaint and a main factor leading to fear of dental procedures⁽¹²⁾. In the current study, the results showed that laser limited the incidence of pain compared to drill but this alteration was not significant. The findings from this research are approximately in line with the prevalent results of considerable number of studies^(13,14). These studies

displayed that the application of lasers for hard and soft tissue therapy is much more painless and comfortable for patients than the patterns of conventional treatment. In the present study the procedure for caries removal by laser wasn't extremely painless as recorded in previous studies. It is painless but for limited degree when compared with high speed turbine.

These non-significant results may be due to the high-power setting 3.5watt and longer preparation time compared to the use of a conventional bur. Additionally, usage turbo handpiece may be also the cause as it produces more powerful energy that may be more painful than gold one. Further studies should be done to demonstrate differences between turbo and gold handpiece in cavity preparation speed and pain perception.

Cavity preparation is not the only main concern for dentist, choosing the appropriate restoration is also has the same importance for successful result. Modification in composites and glass ionomer cement has introduced to improve their properties and durability. High viscous glass ionomer and bulk fill composite are the two modifications that discussed in our study. Clinical evaluation for both restorations in this research was done using modified USHPS criteria. It is estimated color match, marginal adaptation, Surface roughness, retention, anatomic form, sensitivity and 2nd caries. The evaluation done on spot, after three and six months. Rubber dam was used for adequate isolation.

First aspect of clinical evaluation was Color match which achieved alpha score for both restorative materials. During the six months of clinical assessment there is no mismatch in shade, color, or translucency between the restorations and adjacent teeth. These results are in agree with the other studies^(15,16). The second aspect was Marginal adaptation. In the present study, marginal adaptation was good and within alpha range for both restorations all study period.

Absence of Marginal staining is good indication for a good adaptation. Similarly, a pervious study is in a line with our outcomes⁽¹⁷⁾. In contrast, another one⁽¹⁵⁾ that displayed the bulk fill composite had a low marginal adaptation when compared with Equia Forte. In addition, the absence of failures due to Secondary caries during study period may be due to good oral hygiene status of the patients. Firm instruction of oral hygiene measures was followed especially during follow up period.

Furthermore, operative trauma and leakage are the main causes of postoperative sensitivity⁽¹⁸⁻¹⁹⁾. The causes of sensitivity minimization in the current study possibly due to the application of the Equia coat on the restorations surface and use the selective etching technique with universal bond in bulk fill composite. As well, there is no statistically significant difference between the two groups in Surface roughness evaluation in all study period, all results reach alpha score.

Moreover, the anatomical form in most of restorations throughout the study period achieved alpha scores indicate that the absence of restoration wear. Retention criteria was clear visible clinically for all restorations. Therefore, both of the materials have successful anatomic form, smooth surface textures and retention. SEM examinations in pervious study supported our clinical observations⁽¹⁵⁾.

CONCLUSION

The use of lasers in caries removal would be a beneficial method in children. The highly viscous GIC restorative system and bulk fill composite, showed good clinical behavior in Class 1 cavities over the study period according to modified USPHS criteria.

REFERENCES

1. Tanboga I, Eren F, Altunok B, Peker S, Ertugral F. The effect of low-level laser therapy on pain during dental tooth-cavity preparation in children. *Eur Arch Paediatr Dent*. 2011; 12:93–5.

2. Nazemisalman B, Farsadeghi M, Sokhansanj M. Types of lasers and their applications in pediatric dentistry. *J Lasers Med Sci*. 2015; 6:96–101.
3. Arbabzadeh F, Birang E, Nazem R, Abbasian M, Koosha F, Birang R. A comparative study on micro hardness and structural changes of dentin floor cavity prepared by Er: YAG laser irradiation and mechanical bur. *J Dent*. 2013; 14:73.
4. Perito MAM, Jorge ACT, de Freitas PM, Cassoni A, Rodrigues JA. Cavity preparation and influence of restorative materials on the prevention of secondary caries. *Photomed Laser Surg*. 2009; 27:729–34.
5. Chisini LA, Collares K, Cademartori MG, de Oliveira LJC, Conde MCM, Demarco FF, et al. Restorations in primary teeth: a systematic review on survival and reasons for failures. *Int J Paediatr Dent*. 2018;28:123–39.
6. Olegário IC, Hesse D, Bönecker M, Imparato JCP, Braga MM, Mendes FM, et al. Effectiveness of conventional treatment using bulk-fill composite resin versus Atraumatic Restorative Treatments in primary and permanent dentition: A pragmatic randomized clinical trial. *BMC Oral Health*. 2016;17:1–8.
7. Bagheri R. Effect of G-Coat Plus on the properties of aesthetic restorations. *J Dent Res*. 2012;91.
8. Aljamhan A, Platt JA, Cook NB, Cochran MA, Matis BA, Ferreira Zandona AG. Resin-coated glass ionomer cement abrasion and wear resistance. *J Dent Res*. 2012;91.
9. Olivi G, Genovese MD, Caprioglio C. Evidence-based dentistry on laser paediatric dentistry: review and outlook. *Eur J Paediatr Dent*. 2009;10:29.
10. Valério RA, Borsatto MC, Serra MC, Polizeli SAF, Nemezio MA, Galo R, et al. Caries removal in deciduous teeth using an Er:YAG laser: a randomized split-mouth clinical trial. *Clin Oral Investig*. 2016;2:65–73.
11. Evans DJP, Matthews S, Pitts NB, Longbottom C, Nugent ZJ. Restorative dentistry: a clinical evaluation of an Erbium: YAG laser for dental cavity preparation. *Br Dent J*. 2000;188:677.
12. Von Baeyer CL. Children's self-reports of pain intensity: scale selection, limitations and interpretation. *Pain Res Manag*. 2006;11:157–62.
13. Eren F, Altinok B, Ertugral F, Tanboga I. The effect of erbium, chromium:yttrium-scandium-gallium-garnet (Er,Cr:YSGG) laser therapy on pain during cavity preparation in paediatric dental patients: a pilot study. *Oral Health Dent Manag*. 2013;12:80–4.
14. Tao S, Li L, Yuan H, Tao S, Cheng Y, He L, et al. Erbium Laser Technology vs Traditional Drilling for Caries Removal: A Systematic Review with Meta-Analysis. *J Evid Based Dent Pract*. 2017;17:324–34.
15. Relevance C. Four-year Randomized Clinical Trial to Evaluate the Clinical Performance of a Glass Ionomer Restorative System. *J Oper Dent*, 2015; 126:134–43.
16. Bayraktar Y, Ercan E, Hamidi MM, Çolak H. One-year clinical evaluation of different types of bulk-fill composites. *J Investig Clin Dent*. 2017;8:e12210..
17. Turkun LS, Kanic O. Clinical evaluation of new glass ionomer coating combined systems for 18-months. *J Dent Res*. 2010;89: 402.
18. Lopes RM, Trevelin LT, da Cunha SRB, de Oliveira RF, de Andrade Salgado DMR, de Freitas PM, et al. Dental adhesion to erbium-lased tooth structure: a review of the literature. *Photomed Laser Surg*. 2015; 33:393–403.
19. Swift JEJ, May JKN, Mitchell S. Clinical evaluation of Prime & Bond 2.1 for treating cervical dentin hypersensitivity. *Am J Dent*. 2001; 14:13–6.