

Oral Medicine and Surgical Sciences Issue (Oral Medicine, Oral and Maxillofacial Surgery, Oral Pathology, Oral Biology)

7-1-2022

Evaluation of Photodynamic Therapy Using Diode Laser with Photosensitizer in Treatment of Chronic Periodontitis

Doaa Bhgaat

Demonstrator of Oral Medicine, Periodontology, Radiology and Oral Diagnosis Department, Faculty of Dental Medicine, Al -Azhar university, Cairo, Egypt., doaa.bahgaat@gmail.com

Hamdy Nassar

Professor of Oral Medicine, Periodontology, Oral Diagnosis and Dental Radiology Department, Faculty of dental medicine for Girls, Al-Azhar University, Cairo, Egypt.

Naglaa Elkilani

Professor and the Head of Oral Medicine, Periodontology, Oral Diagnosis and Dental Radiology Department, Faculty of Dental Medicine for Girls, Al-Azhar University, Cairo, Egypt.

Eman Kandeel

Professor and the head of Applied and Organic Chemistry Department, Faculty of Science for Girls, Al-Azhar University, Cairo, Egypt.

Follow this and additional works at: <https://azjd.researchcommons.org/journal>



Part of the [Other Dentistry Commons](#)

How to Cite This Article

Bhgaat, Doaa; Nassar, Hamdy; Elkilani, Naglaa; and Kandeel, Eman (2022) "Evaluation of Photodynamic Therapy Using Diode Laser with Photosensitizer in Treatment of Chronic Periodontitis," *Al-Azhar Journal of Dentistry*. Vol. 9: Iss. 3, Article 13.

DOI: <https://doi.org/10.21608/adjg.2022.58090.1330>

This Original Study is brought to you for free and open access by Al-Azhar Journal of Dentistry. It has been accepted for inclusion in Al-Azhar Journal of Dentistry by an authorized editor of Al-Azhar Journal of Dentistry. For more information, please contact yasmeenmahdy@yahoo.com.



Evaluation of Photodynamic Therapy Using Diode Laser with Photosensitizer in Treatment of Chronic Periodontitis

Doaa M. Bhgaat ^{1*}, Hamdy A. Nassar², Naglaa S. Elkilani ³, Eman M. Kandeel ⁴

Codex : 13/22.07

azhardentj@azhar.edu.eg

http://adjg.journals.ekb.eg

DOI: 10.21608/adjg.2022.58090.1330

Oral Medicine & Surgical Sciences
(Oral Medicine, Oral & Maxillofacial
Surgery, Oral Pathology, Oral Biology)

ABSTRACT

Purpose: The current clinical study was conducted to evaluate clinical and biochemical effects of photodynamic therapy in treatment of periodontal disease. **Material and methods:** The current study was conducted on twenty-eight (28) sites in fourteen (14) patients. A split-mouth design was used, sites were randomly selected from each patient, and assigned into two groups:(control group A) fourteen (14) sites received scaling and root planning only, and (test group B): fourteen (14) sites received PDT (Curcumin as photosensitizer agent was irradiated by diode laser beam) and another group without any laser beam in oral cavity, 5 patients received SRP only. Clinical parameters included probing pocket depth (PPD), clinical attachment level (CAL), Plaque index (PI), and gingival index (GI) were used to make clinical evaluation. ELISA analysis of human P.gingivalis IGg was done. **Results:** Comparison between the groups at baseline, one week and one month was showed significant difference in human P.gingivalis IGg which decreased in test group more than in control group. **Conclusion:** This clinical study illustrated that SRP in combination with PDT can be effective especially when used as an adjunctive therapy to the mechanical conditioning of the periodontal pockets. Although using Curcumin as natural photosensitizer agent have great effect on enhancement of inflammation in patients with periodontal disease.

KEYWORDS

Periodontitis,
Photodynamic therapy,
Nano-curcumin, laser.

• Paper extracted from Master Thesis titled “Evaluation of photodynamic Therapy Using Diode Laser with Photosensitizer in Treatment of Periodontitis”.

1. Demonstrator of Oral Medicine, Periodontology, Radiology and Oral Diagnosis Department, Faculty of Dental Medicine, Al-Azhar university, Cairo, Egypt.
2. Professor of Oral Medicine, Periodontology, Oral Diagnosis and Dental Radiology Department, Faculty of dental medicine for Girls, Al-Azhar University, Cairo, Egypt.
3. Professor and the Head of Oral Medicine, Periodontology, Oral Diagnosis and Dental Radiology Department, Faculty of Dental Medicine for Girls, Al-Azhar University, Cairo, Egypt.
4. Professor and the head of Applied and Organic Chemistry Department, Faculty of Science for Girls, Al-Azhar University, Cairo, Egypt.

* Corresponding author email: doaa.bahgaat@gmail.com

INTRODUCTION

Periodontitis is a chronic infectious multi-factorial disease that affects the tissues surrounding the teeth, which is caused by different microorganisms. The most prominent criteria include formation of periodontal pocket, loss of connective tissue attachment, destruction of alveolar bone, and gingival inflammation. If this condition lasts for long time without intervention, it leads to tooth loss. Beginning from simple form gingival inflammation (gingivitis), to irreversible damage of the soft gingival tissue and alveolar bone (periodontitis) ⁽¹⁾.

Previously, there are seven major categories of destructive periodontal disease: (1) chronic periodontitis; (2) localized aggressive periodontitis; (3) generalized aggressive periodontitis; (4) periodontitis as a manifestation of systemic disease; (5) necrotizing ulcerative gingivitis/periodontitis; (6) abscesses of the periodontium; and (7) combined periodontic-endodontic lesions, the 1999 periodontal disease and condition classification system ⁽²⁾.

Recently, the American Academy of Periodontology Task Force (AAP-TF) published a report on the Update to the 1999 Classification of Periodontal Diseases and Conditions which classified in to Staging and Grading Periodontitis". Based on the findings from Step 1, a determination of mild-moderate periodontitis, which is considered Stage I or Stage II, can be made. Severe or very severe periodontitis is considered to be Stage III or Stage IV ⁽³⁾.

Establishing a stage focuses on considerations of clinical attachment loss (CAL), radiographic bone loss (RBL), tooth loss due to periodontitis, and case complexity. For mild to moderate periodontitis, CAL is the central focus, unlike the more advanced stages (Stages III and IV) where RBL and case complexity factors are taken into account. Establishing a grade focuses on assessing risk factors, systemic considerations, rate of disease progression, and outcomes of non-surgical periodontal therapy ⁽⁴⁾.

P.gingivalis, is a "key stone pathogen" of periodontitis. *P.gingivalis* is one of the prominent pathogens present in the oral cavity which belongs to anaerobic Gram-negative coccobacillus species related to the Bacteroidaceae family ⁽⁵⁾.

P.gingivalis has powerful activity and is considered as A strong bacteria that makes tissue damages and disturbs the innate immune and inflammatory response by different virulence factors for example capsule, lipopolysaccharides(LPS), fimbriae, proteases and outer-membrane proteins. It can enhance immunogenicity by stimulating the action of innate and adaptive immunity, in both the host humoral immune response and the host cellular immune response ⁽⁶⁾.

So, to achieve the primary goal of treatment of periodontal diseases, the progression of the disease must be stopped, with reduction or destruction of the microbial biofilm, and attached microorganisms on the root surfaces.

The diode laser is considered a magic line of treatment in the dental field because it is easy and clear for application, and has great advantages with regard to periodontal treatment ⁽⁷⁾. Laser beam is absorbed by different chromophores such as hemoglobin, melanin, which are present in periodontal disease ⁽⁸⁾ Selectivity is one of the advantages of laser beam which affect only diseased gingival tissue. Transmission of laser energy occurs through delivery system (thin optical fibers) that can easily penetrate inside deep periodontal pockets in apico-coronal direction ⁽⁹⁾.

Diode lasers have powerful effect on surgical applications that makes incision easily and aids in hemostasis and coagulation procedure which leads to bloodless operating field, minimal swelling and scarring, and acts as analgesic with no postsurgical pain ⁽¹⁰⁾. A Study have examined the effect of laser in conjunction with scaling and root planning, and found that it has a benefit effect in enhanced, and more comfortable wound healing ⁽¹¹⁾.

Different treatment options are available to support the efficacy of instrumentation and more destruction of different microorganisms, like the usage of local antibiotics (local delivery), antimicrobials or new technology of photodynamic therapy (PDT) ⁽¹²⁾.

Antimicrobial PDT is a non-invasive method of treatment and it has been considered as an adjunctive intervention for periodontitis. It depends on the use of photoactive material, known as photosensitizers dyes (PS) that bind to the target cell and produces cytotoxic reactive oxygen species, resulting from type I or type II reaction, then light irradiation of a suitable wavelength, which coordinates with used dye ⁽¹³⁾. Application of the PS agent inside the periodontal pocket allows binding to microbial biofilm and bacteria. The light-PS interactions will promote the damage of microorganisms by the formation of reactive oxygen species (ROS) and with no harmful effect on host cells. In addition, bacterial resistance has not been reported ⁽¹⁴⁾, which is considered great advantage of this new technology.

The key benefits of APDT can be outlined as a broad spectrum of action compared to antibiotics since PS can act on multiple different organisms such as bacteria, protozoa, fungi.

It also has bactericidal effects independent of antibiotic resistance, more limited side effect profile and damage to the host tissue; no resistance following multiple sessions of therapy ⁽¹⁵⁾.

Born to nature, Curcumin (CUR) is considered as a good product, which is extracted from the rhizomes of turmeric (*Curcuma longa*), a yellow colored polyphenolic bioactive ingredient widely used as a dietary spice, food preservative, coloring and flavoring agent in Asian cooking. From kitchen to pharmacological rule, CUR has several activities such as anti-oxidant, anti-inflammatory, anticancer, antidiabetic, antibacterial, antifungal, and antiviral effect ⁽¹⁶⁾.

Because the CUR has low bioavailability and poor solubility in aqueous media, it is hydrolyzed rapidly, destroyed at physiological pH and loses its activity ⁽¹⁷⁾. Nano technology helps to improve the bioavailability of Curcumin, and water solubility by new formulations of Nano-curcumin, based on biocompatible organic substances such as liposomes and polyethylene glycols ⁽¹⁸⁾.

It is considered that the application of diode laser in adjunctive to SRP will produce significantly good results, enhance improvement of inflamed soft tissues and reduce survival of microorganisms ⁽¹⁹⁾.

The aim of the present study was to evaluate the effect of diode laser with photosensitizer agent in treatment of periodontitis.

MATERIAL AND METHODS

A randomized double-blind, split-mouth study was done on fourteen patients diagnosed as having periodontitis, to be selected consecutively from those referred to the Department of Oral Medicine, Periodontology, Diagnosis and Radiology, Faculty of Dentistry for girls Al-Azhar University seeking periodontal treatment.

Patients diagnosed as having periodontitis; stage II and III, grade (A & B) with age ranging from 40 to 60 years. All patients signed an informed consent. The inclusion criteria included patients who are free from systemic diseases with presence of at least seven natural teeth to provide reasonable number of teeth, matched periodontitis with a PD \geq 5 mm and attachment loss \geq 4 mm. The patients are non-smoker and non-pregnant (women cases).

All patients were divided randomly in two groups. (Laser group): fourteen (14) sites received scaling and root planning and photodynamic therapy using photosensitizer agent and 810 nm Diode laser. (Control group): fourteen (14) sites received scaling and root planning only without using photodynamic therapy. In these two groups split mouth technique was followed, while the other group received scaling and root planning only (with no laser application).

Study procedures

1-Periodontal therapy:

Phase one periodontal therapy, including supra and sub-gingival scaling and root planning and oral hygiene instructions were performed for each patient via manual and ultrasonic instrumentation. The clinical parameters and plaque control were re-assessed, at the baseline and 3 months, post-operatively. The clinical parameters assessed were: Pocket Probing Depth (PPD), Clinical Attachment Level (CAL), Gingival Index (GI), Plaque Index (PI)⁽²⁰⁾. and ELISA quantification for P.gingivalis.

Plaque Index (PI)⁽²⁰⁾

0 = No plaque in the gingival area.

1 = A film of plaque adhering to the free gingival margin and the adjacent area cannot be seen by naked eyes only detected by disclosing agent

2 = accumulation of soft deposits within the gingival pocket, on the gingival margin on the tooth surface, clearly visible not exceed half of the tooth.

3 = Abundance of soft matter within the pocket and/or gingival margin and/or tooth surface, exceed the half of the tooth.

Gingival index (GI)⁽²⁰⁾

The gingival status was evaluated using the (GI) of which divided tissues surrounding each tooth into four gingival scoring units: Disto-facial papilla, facial margin, mesio-facial papilla, and the entire lingual gingival margin. The degree of inflammation was scored according to the following scale.

0 = Normal gingiva.

1 = Mild inflammation, slight change in color, slight edema, no bleeding on probing.

2 = Moderate inflammation, redness, edema, and glazing; bleeding on probing.

3 = Severe inflammation, marked redness and edema, ulceration, tendency to spontaneous bleeding.

Probing pocket depth (PD):⁽²⁰⁾

The distance from the base of the pocket to the gingival margin was measured using Williams periodontal probe with the following graduations: [1, 2, 3, 5, 7, 8, 9 and 10 millimeters (mm)].

The probe was inserted parallel to the long axis of the tooth using a light force.

Clinical attachment level (CAL):⁽²⁰⁾

The distance from the base of the periodontal pocket to cement-enamel junction (CEJ) is CAL. The readings were recorded at the same location of PD .

Curcumin was supplied as pure powder and then Nano-curcumin was prepared in the Department of Applied Organic Chemistry, Faculty of science for girls, Al-Azhar university Curcumin extra pure 99% crystals was used (LOBA chemie pvt ltd, Mumbai, India). Curcumin powder used was a yellowish orange with molecular formula $C_{21}H_{20}O_6$.

2- Preparation of Nano-curcumin:

1. Oil-in-water Nano-emulsion was prepared in two stages.
2. Curcumin (3gm) was added to 100 ml of total emulsion along with MCT-60 (2%), surfactant Tween-80 (10% w/w) and emulsifier WPC-70 (0-1% w/w) in Millipore water.
3. The coarse emulsion was then prepared using magnetic stirrer under ambient temperature for different time intervals.
4. Fine emulsion was prepared by sonifying the coarse emulsion by optimizing the sonification time using ultrasonicator.
5. Emulsion stability was measured by centrifugation at 1300 g at 5°C for 30 min and heating at 80 °C for 30 min.

3- Application of NC:

Nano-curcumin was used as natural photosensitizer agent, applied by plastic syringe with blunt end about 3ml of NC inside the pocket in apico-coronal direction.

4- Laser application:

Diode laser with a wavelength 810 ± 20 nm was used in photodynamic application. Laser beam at power of 0.6 W in a continuous mode was applied to the pocket parallel to the long axis of the tooth from apical to coronal direction with a 200mm tip diameter (Fig.1), for 30 seconds and stopped for 10 seconds (relaxation time). This process was repeated 4 times, with total time of 240 sec. Protective eyewear was worn to prevent injury from laser exposure and to comply with safety standards.

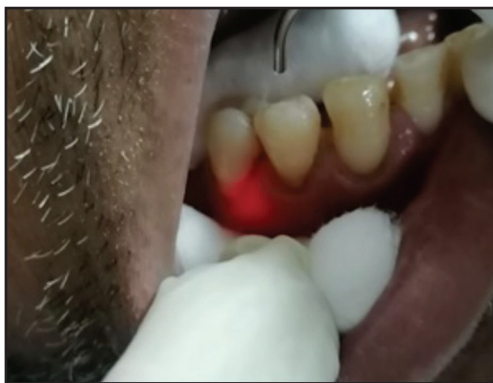

Figure (1): Clinical photograph showing laser beam application.

5- Collection of GCF samples and p. gingivalis biomarker ⁽²¹⁾:

- Supra gingival plaque was carefully removed using periodontal curettes, then pre-cut pre-sterilized paper point was inserted into the isolated periodontal pocket, it was left for 30 seconds.
- At each appointment (baseline, 1 week and 1 month), GCF samples were collected from one pocket site.
- The paper point with GCF samples immediately placed into a microfuge tube on ice at chair side and stored frozen at -80°C within 10 minutes of collection.

6- Bio-chemical evaluation:

Collection of GCF samples: GCF samples were collected from pockets at three appointments: baseline, 1 week and 1 month. Amount of human P.gingivalis IGg in GCF samples was measured by means of Enzyme Linked Immune Sorbent Assay (ELISA).

Statistical analysis

Values were presented as mean and standard deviation (SD) values. Data were explored for normality using Kolmogorov-Smirnov test of normality. The results of Kolmogorov-Smirnov test indicated that data were normally distributed (parametric data), therefore, ANOVA and Tukey's post hoc tests were used for inter-group (between groups) and intragroup comparisons (effect of time within the same group).

The percent change in amount of human P.gingivalis (IGg) detected by ELISA was calculated by the formula.

$$\frac{\text{Value after} - \text{value before}}{\text{Value before}} \times 100$$

The significance level was set at $p \leq 0.05$. Statistical analysis was performed with SPSS 18.0 (Statistical Package for Scientific Studies, SPSS, Inc., Chicago, IL, USA) for windows.

RESULTS

All involved patients completed the study and were re-evaluated at follow up visits. Baseline values were not significantly different among the test and control sets for all the assessed variables, but significant difference was noticed after 1 week and 1 month in detection of amount of human P.gingivalis IGg.

The biochemical findings of human P.gingivalis IGg revealed that there was no statistically significant difference between groups at baseline, (p=0.624).After 1 month, the highest mean value was recorded in the control group (0.051±0.01), followed by Group A (Mechanical debridement) (0.045±0.01), with the least value recorded in

Group B (Mechanical debridement +photodynamic therapy) (0.036±0.005). ANOVA test revealed that the difference between groups was statistically significant (p=0.017). Tukey’ post hoc test revealed that group A was not significantly different from control or Group B table (1), (Fig .2).

Table (1) Descriptive statistics and inter group comparison at each observation time.

		Mean	Std. Dev	Std. Error	95% Confidence Interval for Mean		Min	Max	F	P
					Lower Bound	Upper Bound				
Baseline	Control group	.237	.14	.06	.06	.41	.24	.14	.453	.642ns
	Group A (Mechanical debridement)	.294	.11	.04	.21	.38	.29	.11		
	Group B (Mechanical debridement +photodynamic therapy)	.295	.11	.04	.21	.38	.30	.11		
After 1 week	Control group	.167 ^a	.05	.03	.08	.25	.17	.05	23.179	.000*
	Group A (Mechanical debridement)	.101 ^b	.02	.01	.09	.11	.10	.02		
	Group B (Mechanical debridement +photodynamic therapy)	.057 ^c	.02	.01	.04	.07	.06	.02		
After 1 month	Control group	.051 ^a	.01	.01	.03	.07	.05	.01	5.113	.017*
	Group A (Mechanical debridement)	.045 ^{a,b}	.01	.00	.04	.05	.04	.01		
	Group B (Mechanical debridement +photodynamic therapy)	.036 ^b	.005	.00	.03	.04	.04	.00		

Significance level $p \leq 0.05$, *significant, ns=non-significant

Tukey’s post hoc test: within the same comparison, means sharing the same transcript letter are not significantly different.

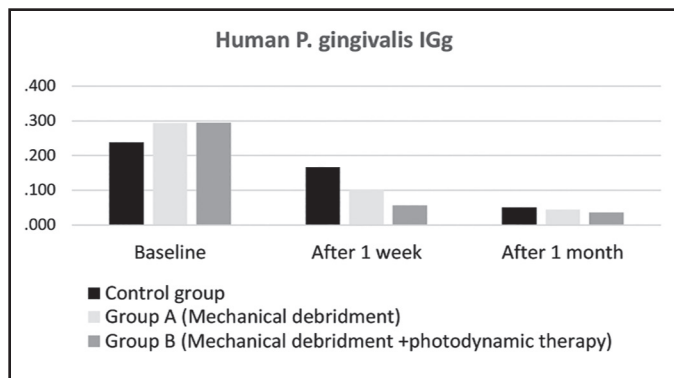


Figure (2): Bar chart illustrating mean values of human P.gingivalis IGg in different groups in different observation times.

Regarding to clinical parameters:

Table (2) Changes of the mean of clinical parameters within the control and laser groups through the whole study period.

		Baseline	After 3 months	t value of paired t test	P value
PI (mean ±SD)	Control group	2.36±0.5	1.07±0.62	6.06	0.00*
	PDT group	2.36±0.48	0.79±0.56	7.96	0.00*
GI (mean ±SD)	Control group	2.36±0.5	1.07±0.47	7.03	0.00*
	PDT group	2.36±0.5	0.79±0.43	8.9	0.00*
PD(mean ±SD)	Control group	6±0.68	5.43±0.94	1.84	0.077 ns
	PDT group	6.36±1.01	4.86±0.77	4.42	0.0002*
CAL (mean ±SD)	PDT group	5.29±1.59	4.93±1.21	1.8	0.0475*
	Las group	6.43±2.14	5.14±1.83	1.7	0.0565*

Significance level $p \leq 0.05$, *significant, ns=non-significant

DISCUSSION

The treatment of periodontitis has different lines of treatment, which involve scaling and root planning (mechanical debridement), nonsurgical and surgical approach methods in conjunction with antimicrobial agent including the use of disinfectant agent and antibiotics⁽²²⁾. Although nonsurgical sub-gingival debridement is effective, certain pathogens such as *P. gingivalis* and *Aa* are particularly resistant to the effects of sub-gingival debridement due to their ability to invade underlying connective tissues⁽²²⁾.

A new treatment possibility obviating these disadvantages is a PDT, which combines the application of different PS dyes and irradiation with light of appropriate wavelength. PDT application is beneficial at areas difficult to access, for example deep periodontal pockets, furcations, and root concavities.

One of the most effective methods in treatment of periodontitis is photodynamic therapy which depends on using specific agent, which is hydrophilic in nature, bio-available and easy absorbed. The

pocket is then irradiated by a low level light diode laser.

The mechanism of photodynamic therapy depends on using photosensitizer agent which has ability to absorb energy produced from laser beam, the presence of oxygen which produces sensitive oxygen species (ROS), that causes bacterial damage effect on cytoplasmic membrane, organelles, cytoplasmic proteins and DNA. To optimize the effect of photodynamic therapy, selected photosensitizer must be compatible with laser wavelength (i.e. the wavelength and the energy absorbed lies in the color spectrum of the dye)⁽²³⁾.

Different types of photosensitizer agent used in photodynamic therapy are either natural or synthetic. one of the natural agents is Curcumin, which is yellow polyphenolic bioactive ingredient extracted from the rhizomes of turmeric (*Curcuma longa*). CUR is widely used in treatment of several diseases such as diabetes, wounds, liver disorders, rheumatism, cough, and respiratory illness⁽²⁴⁾. CUR is also used as anti-inflammatory, anti-cancer, anti-oxidant, antidiabetic, antifungal, anti-bacterial and anti-viral effects. It is also used in treatment of

gingivitis, periodontitis, oral mucositis and oral lichen planus ⁽¹⁸⁾. The aim of this study was to evaluate the effect of diode laser with photosensitizer agent in treatment of periodontitis.

In the current study Curcumin was used as photosensitizer agent under stimulation of diode laser 810 nm 0.6 Watt, after scaling and root planning (mechanical debridement). By microbiology evaluation, it was found that there is significant reduction in amount of *P. gingivalis* after 1 week and 1 month in the test group (group B SRP +PDT).

The results of current study, showed no significant difference between groups in all the clinical parameters (PI, GI, PD, CAL) at the base line, a finding that ensured comparable treatment outcomes at the follow up. Intragroup statistical analysis of the PI showed that from baseline to 3 months, in each group, there was no significant difference between baseline and follow-up. The area under test was free of plaque at the beginning and the end of the study. Patients were kept under strict maintenance program and performed proper oral hygiene so plaque accumulation was minimal.

Regarding the comparison of clinical parameter which in each group that significance difference between interval in the same group for PI, CAL, GI, and PD .result indicated that more enhancement in PDT more than SRP. Result may be related to the effect of thorough debridement and removal of local factors which lead to decrease in inflammatory mediators and in turn decrease in bleeding on probing, Curcumin has the ability to reduce edema, inflammation and bleeding ⁽²⁵⁾.

Application of laser is useful in treatment of periodontitis and this effect can be evaluated by change in bacterial load, clinical parameters and radiograph. It was stated that the application of diode laser adjacent to SRP made good effect and enhanced the inflammatory condition in the oral cavity by reducing pathogenic bacteria such as *P. intermedia*, and *P. gingivalis*. One study was conducted on 2 groups of ligature-induced periodontitis in rats, one

group received laser only, the other group used laser in adjacent to SRP, it was found that diode laser is effective both when used alone and when used as adjunctive therapy to SRP⁽²⁶⁾.

This is in accordance with another study that concluded the fact that APDT affects the growth of *P. gingivalis* by inhibition of growth factor and inactivates it is protease ⁽²⁷⁾.

In contrast, there are also several clinical studies which have estimated that there is no antimicrobial change of photodynamic therapy and no significant differences between groups at any time during the study in the levels of micro-organisms such as *Aggregatibacter actinomycetemcomitans*, *Porphyromonas gingivalis*, *Treponema denticola* and *Tannerella forsythia*. The authors suggested that APDT is unable to achieve success of anti-microbiological benefits in the treatment of periodontitis ⁽²⁸⁾.

Contrary to our study, there is another study which explained the effect of PDT in a short period of study (one week). Control group: scaling and root planning, test group: scaling and root planning + PDT. The results of this study have estimated that there is no significant difference between treatment groups. They suggested that photodynamic therapy has short term effects on clinical and microbiological outcomes ⁽²⁹⁾.

Curcumin has several functions in enhancement of oral condition and treatment of periodontitis because it act as anti-oxidant, anti-inflammatory antibacterial, and also used in systemic diseases as anti-cancer, antidiabetic, antibacterial, antifungal, and anti-viral effects ⁽³⁰⁾, also used in treatment of autoimmune diseases.

Several studies have reported that CUR has powerful effects against microorganisms especially oral pathogens such as (*S.mutans*), *Actinomyces viscosus*, *P.gingivalis*, *Prevotella intermedia*, and *Treponema denticola* ⁽³¹⁾. Also CUR has benefit effects on growth, metabolism and biofilm formation in *P.gingivalis* ⁽³²⁾.

In a previous study, Curcumin gel was used with concentration of 10 mg/gm as photosensitizer agent then activated by diode laser 470 nm wavelength, which produce cytotoxic species including singlet oxygen and free radical that have selective toxicity, which means lethal effect on bacteria but Non-toxic to host cells⁽³³⁾

It is suggested that Curcumin as local drug adjunct to SRP is effective in elimination of gingival bleeding and periodontal pathogens like Aa. Curcumin suppresses the growth of Streptococcus, Staphylococcus, Lactobacillus, Helicobacter pylori, etc. and also equally effective in reducing Pg as tested by N-benzoyl-d L-arginine-2-naphthylamide test⁽³⁴⁾.

CONCLUSION

Application of PDT in the current study protocol with this parameter (use CUR as natural photosensitizer agent + 810 nm wavelength, 0.6 watt) has shown: enhancement in reduction of oral pathogens especially P.gingivalis.

CUR have multiple targets, it is simple and inexpensive therapeutic strategy for treating periodontal disease. So, the application of APDT significantly suppressed the formation of dental plaque, which indicated that APDT has been promised to be alternative or adjunct method to mechanical means in dental plaque control for oral care.

REFERENCES

- Berglundh T, Armitage G, Araujo MG, Avila-Ortiz G, Blanco J, Camargo PM, et al. Peri-implant diseases and conditions. *J Clinical Periodontology*. 2018; 45:286-91.
- Mittal V, Bhullar RP, Bansal R, Singh K, Bhalodi A, KhindaPK. A practicable approach for periodontal classification. *Dental research journal*. 2013; 10:697.
- Papapanou PN, Sanz M. Periodontitis: Consensus report of workgroup 2 of the 2017 World Workshop on the Classification of Periodontal and Peri-Implant Diseases and Conditions. *J Periodontol*. 2018; 89:173-82.
- Berglundh T, Armitage G, Araujo MG, Avila-Ortiz G, Blanco J, Camargo PM, et al. Peri-implant diseases and conditions: Consensus report of workgroup 4 of the 2017 World Workshop on the Classification of Periodontal and Peri-Implant Diseases and Conditions. *J. Clinical Periodontology*. 2018 ; 45:286-91.
- Hajishengallis M, Darveau A. The keystone-pathogen hypothesis. *Nat. Rev. Microbiol*. 2017;4: 717-25.
- Hasegawa A, Yoshimura G, Persson M. Structural and functional characterization of shaft, anchor, and tip proteins of the Mfa1 fimbria from the periodontal pathogen *Porphyromonas gingivalis*. *J of microbiology* 2018; 8:1793.
- Carvalho PC, Gomes IS, Meyer R, Olczak.T, Xavier M.T. Role of *Porphyromonas gingivalis* HmuY in Immunopathogenesis of Chronic Periodontitis. Review article .2016;34:156-66.
- Miriam T. Laser Treatment of Periodontal Disease. A Systematic Review of Histological Outcomes. *EC Dental Science*. 2018;122: 1344-67.
- Birang E, Talebi M, Rajab Z, Sarmadi G, Birang R, Gutknecht N, et al. Evaluation of effectiveness of photodynamic therapy with low-level diode laser in non-surgical treatment of peri-implantitis. *J. Lasers Med Sci* .2017;8:136-42.
- Pnar G, Nurcan B. Photodynamic Therapy and Periodontal Treatment May Clinical Anti-Inflammatory & Anti-Allergy Drugs. *J periodontology* .2016 ;2:38-42.
- Crispino A, Figliuzzi M, Iovane C. Effectiveness of a diode laser in addition to non-surgical periodontal therapy. *J lasers Med sci*. 2015; 6:15-20.
- Biochem J. New photosensitizers for photodynamic therapy. *J laser surg*. 2017; 67:9.
- Hisham M, Ahmed E, Mouchira S, Wael S. clinical and radiodensitometric evaluation of low energy laser in management of periodontal condition in smoker patients. *J dental sci*. 2020; 1:133-40.
- Borekci T, Meseli S, Noyan U, Kuru BE, Kuru L. Efficacy of adjunctive photodynamic therapy in the treatment of generalized aggressive periodontitis: a randomized controlled clinical trial. *Lasers Surg Med*. 2018; 66:76.
- Jaber G, Dariush R, Shahin A. Photosensitizers in antibacterial photodynamic therapy. *J laser sci*. 2018.544:45-76.
- Bhatia M, Urolagin SS, Pentyala KB. Novel therapeutic approach for the treatment of periodontitis by Curcumin. *J. Clin and Diagnostic Research*. 2014; 8: 65- 9.
- Amr A, Ahmed E: Antimicrobial Photodynamic Therapy Using Curcumin Photosensitizer in Conjunction with

- Periodontal Open Flap Debridement. Pilot Clinical Study with Real-Time PCR Bacterial Assessment. *Egyptian dental J (Oral Medicine, X-Ray, Oral Biology & Oral Pathology)*. 2021;66: 333-56.
18. Peram MR, Jalalpure SS, Joshi SA, Palkar MB, Diwan PV. Single robust RP-HPLC analytical method for quantification of Curcuminoids in commercial turmeric products, Ayurvedic medicines, and nanovesicular systems. *J Liq Chromatogr Relat Technol*. 2017;40 :487-99.
 19. Kao RT, Nares S, Reynolds MA. Periodontal regeneration intrabony defects: a systematic review from the AAP regeneration workshop. *J Periodontol* .2015; 86: 77-104.
 20. Renvert S, Persson G. A systematic review on the use of residual probing depth, bleeding on probing and furcation status following initial periodontal therapy to predict further attachment and tooth loss: *J Clin Periodontol*. 2002; 29: 82-9.
 21. Makeudom A, Kulpawaropas S, Montreekachon M. Positive correlations between hCAP18/LL-37 and chondroitin sulphate level in chronic periodontitis. *J Clinical Periodontology*. 2014; 41: 252-6.
 22. Paschoal M.A, Santos P. Photodynamic antimicrobial chemotherapy on *Streptococcus mutans* using Curcumin and toluidine blue activated by a novel LED device, *Lasers Med. Sci*. 2015;30: 885-90.
 23. Passanezi E, Damante C, Rezende M, Greggi S. Lasers in periodontal therapy. *Periodontol*. 2015; 67: 268-91.
 24. Prasad S, Tyagi A, Aggarwal B. The Chemistry of Curcumin: From Extraction to therapeutic agent molecules. 2017; 19: 91-112.
 25. Mahdi Z, Habiboallah G, Mahbobeh , Mina Z , Majid Z, Nooshin A, et al. Lethal effect of blue light-activated hydrogen peroxide, curcumin and erythrosine as potential oral photosensitizers on the viability of *Porphyromonas gingivalis* and *Fusobacterium nucleatum*. *Laser Therapy* 2015; 24(2): 103-111.
 26. Theodoro LH, Caiado RC, Longo M, Novaes VC, Zanini NA, Ervolino E, et al. Effectiveness of the diode laser in the treatment of ligature induced periodontitis in rats: a histopathological, histometric, and immune-histochemical study. *Lasers Med Sci*. 2015; 30:1209-18.
 27. Bozkurt SB, Hakki EE, Kayis SA, Dundar N, Hakki SS. Biostimulation with diode laser positively regulates cementoblast functions, in vitro. *Lasers Med Sci*. 2017; 32:911-9. 24.
 28. Carvalho VF, Andrade P, Rodrigues MF. Antimicrobial photodynamic effect to treat residual pockets in periodontal patients: A randomized controlled clinical trial. *J Clin Periodontol* .2015; 42: 440-7.
 29. Mirlinda S, Merita B, Kastriot M. Clinical and Biochemical Evaluation of the Effect of Diode Laser Treatment Compared to the Non-surgical and Surgical Treatment of Periodontal Diseases. *J periodontal* .2020; 14:281-8.
 30. Ajaikumar B, Devivasha B, Ganesan P, Javadi M, Nand K, Sahdeo P, et al. Curcumin, the golden nutraceutical: multi-targeting for multiple chronic diseases. *British J. Pharm*. 2016; 65: 2-4.
 31. Jin C, Jung W. Combination treatment with photodynamic therapy and Curcumin induces mitochondria-dependent apoptosis in AMC-HN3 cells international. *J. Oncology*.2018 ;41: 2184-90.
 32. Lin H, Zhou Y. Curcumin as a promising antibacterial agent: effects on metabolism and biofilm formation in *S. mutans*. *Bio Med Res Int*. 2018; 88:9.
 33. Rahimi M, Jouny F. Gold-Curcumin Nanostructure in Photo-thermal Therapy on Breast Cancer Cell Line: 650 and 808 nm Diode Lasers as Light Sources. *J. biomedical physics & engineering*. 2019; 9:4 473-82.
 34. Shawaer N, Garib A. Antibacterial Effect of Curcumin against Clinically Isolated *Porphyromonas gingivalis* and Connective Tissue Reactions to Curcumin Gel in the Subcutaneous Tissue of Rats. *Bio Med research international*.2019; 68:109-36.