

Pediatric dentistry and orthodontics Issue (Pediatric Dentistry, Orthodontics)

7-1-2022

Assessment of Treatment Outcomes of Skeletal Class II Malocclusion Using Forsus Fatigue Resistant Device

Esraa Taha

Dentist at Egyptian Ministry of Health, esraa.taha@azhar.edu.eg

Samir Ibrahim

Professor of Orthodontics, Faculty of Dental Medicine for Girls, Al-Azhar University, Cairo, Egypt., drsamiribra@hotmail.com

Khaled Abdallah

Lecturer of Orthodontics, Faculty of Dental Medicine for Boys, Al-Azhar University, Cairo, Egypt., khaledfarouk@azhar.edu.eg

Amany Ibrahim

Lecturer of Orthodontics, Faculty of Dental Medicine for Girls, Al-Azhar University, Cairo, Egypt., amanyortho@yahoo.com

Follow this and additional works at: <https://azjd.researchcommons.org/journal>



Part of the [Other Dentistry Commons](#)

How to Cite This Article

Taha, Esraa; Ibrahim, Samir; Abdallah, Khaled; and Ibrahim, Amany (2022) "Assessment of Treatment Outcomes of Skeletal Class II Malocclusion Using Forsus Fatigue Resistant Device," *Al-Azhar Journal of Dentistry*. Vol. 9: Iss. 3, Article 19.

DOI: <https://doi.org/10.21608/adjg.2022.58982.1333>

This Original Study is brought to you for free and open access by Al-Azhar Journal of Dentistry. It has been accepted for inclusion in Al-Azhar Journal of Dentistry by an authorized editor of Al-Azhar Journal of Dentistry. For more information, please contact yasmeenmahdy@yahoo.com.



Assessment of Treatment Outcomes of Skeletal Class II Malocclusion Using Forsus Fatigue Resistant Device

Esraa A. Taha^{1*}, Samir A. Ibrahim², Khaled F. Abdallah³, Amany M. Ibrahim⁴

Codex : 19/22.07

azhardentj@azhar.edu.eg

http://adjg.journals.ekb.eg

DOI: 10.21608/adjg.2022.58982.1333

Pediatric Dentistry & Orthodontics
(Pediatric Dentistry, Orthodontics)

ABSTRACT

Purpose: This study was carried out to assess treatment outcomes of Forsus Fatigue Resistant Device (FFRD) used in correction of skeletal Class II malocclusion through lateral cephalometric analysis. **Subjects and methods:** The study was conducted on ten Class II male patients. Treatment was followed through leveling and alignment till heavy 0.019 x 0.025-inch stainless steel archwires reached, then FFRD was inserted. The FFRD protocol ended when an overcorrected edge to edge incisal relation was obtained. Lateral cephalometric radiographs were taken before therapy and after completion of FRD therapy. The following skeletal parameters were measured from lateral cephalograms: SNA, SNB and ANB angles and linear measurement of total mandibular length, ramus height and corpus length. Measured dental parameters were maxillary and mandibular incisors inclination, amount of mesial movement of mandibular first molar, overjet and overbite. **Results:** The FFRD had a combined skeletal and dentoalveolar effect. It enhanced the sagittal skeletal relationships through maxillary restriction and mandibular forward repositioning. Dentoalveolar effects were significant in both arches and significant enhancement in overjet and overbite were found. **Conclusions:** The FFRD is effective in correcting Class II malocclusion through skeletal and dentoalveolar changes.

KEYWORDS

*Class II malocclusion,
fixed functional appliance,
Forsus Fatigue Resistant Device.*

INTRODUCTION

Any deviation from normal sagittal posture of jaws, teeth or lips could simply result in Class II malocclusion. The mandible is usually

- Paper extracted from Master Thesis titled “Assessment of Treatment Outcomes of Skeletal Class II Malocclusion Using Forsus Fatigue Resistant Device.”
- 1. Dentist at Egyptian Ministry of Health.
- 2. Professor of Orthodontics, Faculty of Dental Medicine for Girls, Al-Azhar University, Cairo, Egypt.
- 3. Lecturer of Orthodontics, Faculty of Dental Medicine for Boys, Al-Azhar University, Cairo, Egypt.
- 4. Lecturer of Orthodontics, Faculty of Dental Medicine for Girls, Al-Azhar University, Cairo, Egypt.

* Corresponding author email: esraa.taha@azhar.edu.eg

too distal in relation to the maxilla⁽¹⁾. The worldwide commonness of Class II malocclusion is 19.56%. However, it ranges from 1.6% in Nigerians to 63% in Belgians⁽²⁾. Its prevalence was found to be 21% in the Egyptian population⁽³⁾.

Class II malocclusion is a combination of skeletal and dental components; in which mandibular retrusion is the most frequent feature⁽⁴⁾. Among young Egyptian adults, it was found to be a combination of small mandibles, mandibular retrusion, backward rotation of mandibles and large maxillo-mandibular discrepancy⁽⁵⁾.

Functional appliances, through forward positioning of the mandible, aim to stimulate mandibular growth to correct Class II disharmony⁽⁶⁾. Functional appliances could either be fixed or removable, with the major limitation of removable functional appliances is the dependence on patient cooperation, which can influence the effectiveness of the treatment⁽⁷⁾.

The Herbst appliance is the most often used rigid fixed functional appliance worldwide. It was described first by Emil Herbst in 1905, then Pancherz renewed and reintroduced it in 1979⁽⁸⁾. The Twin force bite corrector and PowerScope are semirigid fixed functional appliances that proved their effectiveness in treatment of Class II malocclusion^(9,10).

The Forsus Fatigue Resistant Device (FRD) (Forsus; 3M Unitek, Monrovia, CA, USA) was described in 2006 by Vogt. FRDEZ2 module consists of a semirigid telescoping system incorporating a fatigue resistant stainless steel intermaxillary spring produces force of approximately 220g. It's secured into the maxillary molar tube through a clip, and connected to the mandibular arch through the push rod piece. FFRD can be used simultaneously with fixed brackets systems⁽¹¹⁾.

Noteworthy, supplementary mandibular growth is expected to be greater when functional treatment is accomplished during pubertal peak of skeletal maturation⁽¹²⁾.

So, this study was done to assess the treatment outcomes of skeletal Class II malocclusion using Forsus Fatigue Resistant Device and lateral cephalometric radiographic analysis.

SUBJECTS AND METHODS

The present study was done on 10 Class II male patients according to sample size power test aged 11-13 years old. These participants were selected from those coming to Clinic of orthodontic department, Faculty of Dental medicine for Girls, Al Azhar University. This research received ethical approval of the faculty Dental medicine of Al-Azhar University, Cairo, Egypt. Ethical code number: REC 17-102.

Patients were with Angle Class II molar relationship, equal to or greater than one half- cusp width, Mild to moderate Skeletal Class II malocclusion, ANB angle $> 4^\circ$, Overjet ≥ 5 mm and reached permanent dentition stage. No previous orthodontic treatment, free of any systemic disease and with good oral hygiene.

Composed informed consent forms were signed by the guardians and patients after the treatment methods were clarified in detail.

Selected patients received a treatment protocol with preadjusted 0.022-in slot Roth fixed appliances with FRD. The FFRD phase was initiated once a heavy 0.019 x 0.025-inch stainless-steel archwires was applied. Cinching of the maxillary and mandibular archwires distal to the molars was done. Mandibular canines were steel ligated to the archwires. The FRD push rod was placed distal to the mandibular canine. (Fig.1)

The FRD was active in place till a Class I relation of canine and molar was achieved. After that, finishing and settling the occlusion was carried through. Pre-FRD and post-treatments lateral cephalometric radiographs were obtained, traced and analyzed. Tracing of cephalograms was done manually using a 0.3 mm pencil on acetate paper using a viewer box screen. Skeletal and dental measurements were obtained.

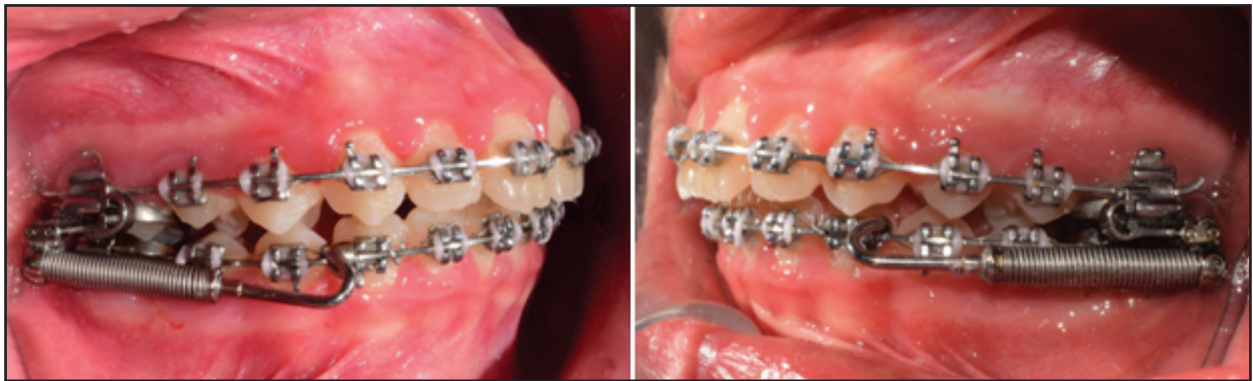

Figure (1) Intra-oral view of FFRD

Cephalometric analysis:

Tracing and analysis of lateral cephalograms was done at two separate times by the same researcher, readings were collected and evaluated for intra-observer error and variations. Cephalograms were traced by another colleague who is a Master degree student at the same department. Measurements were also evaluated for inter-observer error and variations. Obtained skeletal angular measurements were SNA, SNB and ANB to evaluate the effect of FFRD on the sagittal relationship of the mandible and maxilla. Skeletal linear measurements were ramus height (Co-Go), corpus length (Go-Me) and total mandibular length (Co-Me). Dental measurements obtained were U1/SN° and L1/SN° to evaluate the inclination of upper incisor and lower incisor in relation to SN plane. Also L6-RL2 (mm) that describes the linear measurement between lower first molar and reference line 2 ejected perpendicular to constructed FH through S point, overjet (mm) and overbite (mm) were measured.

RESULTS

All data showed normal (parametric) distribution when explored for normality. Numerical data were presented as mean and standard deviation (SD) values. Paired t-test was used to compare between measurements pre- and post-treatment. Intra- and inter-observer agreement (reliability) was assessed using Cronbach's alpha and Intra-Class Correlation Coefficient (ICC). The significance level was set at

$P \leq 0.05$. Statistical analysis was performed with IBM SPSS Statistics for Windows, Version 23.0. Armonk, NY:IBM Corp.

1. Demographic data

The present study was conducted on 10 male patients, their age was 12 ± 1 years.

2. Reliability analysis

Intra-observer reliability and Inter-observer reliability:

There was very good intra- and inter-observer reliability (agreement) regarding all measurements.

3. Skeletal measurements

There was a statistically significant decrease in mean SNA° and ANB° measurements post-treatment. There was a statistically significant increase in mean SNB° angle measurement post-treatment. (Table 1)

There was a statistically significant increase in mean ramus height, corpus length and total mandibular length measurements post-treatment. (Fig. 2)

4. Dental measurements

There was a statistically significant decrease in mean U1/SN°, L1/SN°, mean overjet (mm) and overbite (mm) measurements post-treatment. There was a statistically significant increase in mean L6-RL2 (mm) measurements post-treatment. (Table 2)

Table (1): Mean, standard deviation values and results of paired t-test for comparison between skeletal angular measurements pre- and post-treatment

Skeletal angular measurements (°)	Pre-treatment (n = 10)		Post-treatment (n = 10)		Change		P-value	Effect size (d)
	Mean	SD	Mean	SD	Mean	SD		
SNA°	81.8	1.33	81.45	1.36	-0.35	0.41	0.02*	0.26
SNB°	76.6	2.01	77.55	1.53	0.95	0.76	0.003*	0.531
ANB°	5.2	0.94	3.9	1.07	-1.3	0.94	0.001*	1.29

*: Significant at $P \leq 0.05$, SD=standard deviation, Sample size (n) = 10.

Table (2): Mean, standard deviation values and results of paired t-test for comparison between dental measurements pre- and post-treatment

Dental measurements (°)	Pre-treatment (n = 10)		Post-treatment (n = 10)		Change		P-value	Effect size (d)
	Mean	SD	Mean	SD	Mean	SD		
U1/SN°	107.6	5.73	102.9	5.34	-4.7	4.94	0.014*	0.848
L1/SN	42.5	5.1	35.6	4.92	-6.9	5.66	0.003*	1.377
L6-RL2	33.2	5.13	36.5	5.14	3.3	1.15	<0.001*	0.642
Overjet (mm)	6.5	0.7	1.9	0.69	-4.63	1.21	<0.001*	6.618
Overbite (mm)	4.25	1.08	1.5	0.57	-2.75	0.97	<0.001*	3.184

*: Significant at $P \leq 0.05$, SD=standard deviation, Sample size (n) = 10.

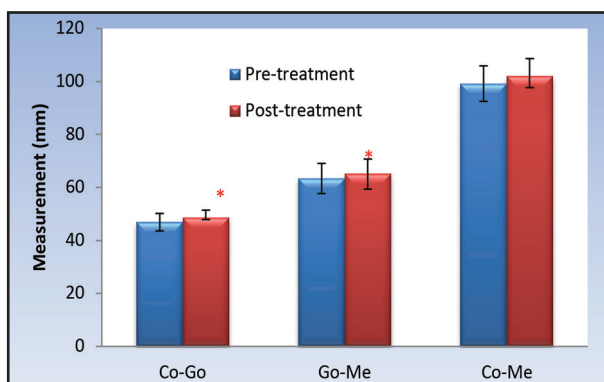


Figure (2): Bar chart representing mean and standard deviation of mandibular skeletal linear measurements pre- and post-treatment.

DISCUSSION

Functional jaw orthopedics (FJO) are considered a valuable option in treating growing skeletal Class II subjects. FJO primary mechanism is stimulating mandibular growth through mandibular advancement ⁽⁶⁾.

Functional appliances could either be fixed or removable. The major limitation of removable functional appliances is the dependence on patient cooperation, which can influence the effectiveness of the treatment. An advantage of FFAs is the use of the functional appliance with multibrackets simultaneously, shortening treatment duration ^(7,13).

Forsus Fatigue Resistant Device is an example of hybrid FFAs. It was described in 2006 by William Vogt. FRD EZ2 module consists of a semirigid

telescoping system incorporating a fatigue resistant stainless steel intermaxillary spring delivering approximately 220g. It's secured into the maxillary molar tube through a clip, and connected to the mandibular arch through the push rod piece⁽¹¹⁾.

This study aimed to assess the skeletal and dentoalveolar changes produced by a fixed functional appliance, the Forsus Fatigue Resistant Device, in treatment of skeletal Class II malocclusion in adolescent patients. The study was conducted on 10 males. For ethical reasons, this study did not include a control group. Since the age group selected is a critical circumpubertal growth age, a biological period that has been related with the foremost favorable treatment impacts in Class II patients⁽⁶⁾.

The FRD was successful in the correction of Class II malocclusion. The assessment of skeletal and dental changes in the present study was derived from cephalometric analysis obtained before treatment and after FRD treatment. Intra- and inter-observer agreement (reliability) was assessed using Cronbach's alpha and Intra-Class Correlation Coefficient (ICC), it was found to be very good.

There was a statistically significant reduction of mean SNA by -0.35° . This change revealed a noteworthy effect of the FFRD in maxillary restriction. The restraint effect was evident in previous studies^(12, 14). While other studies reported no significant effect of FFRD on the maxillary skeletal base^(11, 15). This disputation might result from treatment age variations, distinctive treatment mechanics, or treatment duration⁽¹⁵⁾.

The FFRD also showed a statistically significant increase in the mean SNB by 0.95° . This change indicated evident forward repositioning of the mandible. This finding is similar to the results from previous studies^(11, 16). Other previous studies reported that FFRD does not affect SNB⁽¹²⁾. The maxillary and mandibular changes accounted for a statistically significant enhancement in their sagittal relation, with reduction in the mean ANB value by -1.3° . This finding is in harmony with results reported from previous studies^(11, 15).

There was a statistically significant increase in the mean ramus height (Co-Go), corpus length (Go-Me) and total mandibular length (Co-Me) by 1.8 mm, 1.8 mm and 2.8 mm, respectively; indicating mandibular growth. Previous studies also reported substantial mandibular growth with the FRD appliance^(11, 16). The present study findings are in contrast with other studies that reported no significant effect of FRD on the total mandibular length with limited effect on mandibular growth^(12, 17).

Regarding dentoalveolar changes, there was significant decrease of mean U1/SN⁰ and L1/SN⁰ measurements post-treatment by -4.7° and -6.9° , respectively. These results indicate significant retroclination of upper incisor and labial flaring of lower incisor. These findings are in agreement with previous studies⁽¹⁰⁻¹²⁾.

There was a statistically significant increase in mean L6-RL2 (mm) by value of 3.3 (mm) post-treatment. This finding indicates mesial movement of mandibular first molar. This finding is in agreement with previous studies^(10, 11).

There was a statistically significant decrease in mean overjet and overbite measurements post-treatment by -4.63 (mm) and -2.75 (mm), respectively. Most of the previous studies reported an improvement in overjet and overbite values which was also found in the present study^(10, 12, 15, 17).

CONCLUSION

Forsus Fatigue Resistant Device was successful in correction of skeletal Class II malocclusion. FFRD results in restriction of maxilla and forward repositioning of the mandible. FFRD resulted in significant flaring of mandibular incisors and retroclination of maxillary incisors.

ACKNOWLEDGEMENT

I would like to thank the staff members of the orthodontic department, faculty of Dental medicine for Girls, Al-Azhar University for their help, support and guidance throughout this study.

RECOMMENDATIONS

Based on the results provided by the present study the followings are recommended:

1. Further trials are recommended to compare between males and females and the effect of difference in gender.
2. Further trials are recommended to assess the changes in maxillary arch width with FFRD.
3. Further trials are recommended to assess the benefits of FFRD in late mixed dentition stage.
4. Further investigations are recommended to assess the spring fatigue of the EZ2 module of FFRD.

NO CONFLICT OF INTEREST

No Funding Was Received For This Study

REFERENCES

1. Batista KBSL, Thiruvengkatachari B, Harrison JE, O'Brien KD. Orthodontic treatment for prominent upper front teeth (Class II malocclusion) in children and adolescents. *Cochrane Database Syst Rev.* 2018;CD003452.
2. Alhammadi MS, Halboub E, Fayed MS, Labib A, El-Saaidi C. Global distribution of malocclusion traits: A systematic review. *Dental press J Orthod.* 2018;23:40-e1-10.
3. Rashid A, El Feky H. Prevalence of Malocclusion using Angle classification within The Dental Students of Fayoum University, Egypt (A Survey Study). *Egy Dent J.* 2019;65:965-69.
4. Franchi L, Pavoni C, Faltin K, Bigliuzzi R, Gazzani F, Cozza P. Thin-plate spline analysis of mandibular shape changes induced by functional appliances in Class II malocclusion. *J OrofacOrthop.* 2016;77:325-33.
5. Elkordy SA. Evaluation of Miniplates Anchored Forsus Fatigue Resistant Device for Correction of Skeletal Class II Malocclusion in Growing Subjects: A Randomized Controlled Trial. PhD thesis, Cairo University, 2016.
6. Zymperdikas VF, Koretsi V, Papageorgiou SN, Papadopoulos MA. Treatment effects of fixed functional appliances in patients with Class II malocclusion: a systematic review and meta-analysis. *Eur J Orthod.* 2016;38:113-26.
7. Koretsi V, Zymperdikas VF, Papageorgiou SN, Papadopoulos MA. Treatment effects of removable functional appliances in patients with Class II malocclusion: a systematic review and meta-analysis. *Eur J Orthod.* 2015;37:418-34.
8. Yang X, Zhu Y, Long H, Zhou Y, Jian F, Ye N, Gao M, Lai W. The effectiveness of the Herbst appliance for patients with Class II malocclusion: a meta-analysis. *Eur J Orthod.* 2016;38:324-33.
9. Foncatti CF, Henriques JF, Janson G, Caldas W, Garib DG. Long-term stability of Class II treatment with the Jasper jumper appliance. *Am J OrthodDentofacialOrthop.* 2017;152:663-71.
10. Arora V, Sharma R, Chowdhary S. Comparative evaluation of treatment effects between two fixed functional appliances for correction of Class II malocclusion: A single-center, randomized controlled trial. *AngleOrthod.* 2018;88:259-66.
11. Elkordy SA, Abouelezz AM, Salah Fayed MM, Attia KH, Rahman Ishaq RA, Mostafa YA. Three-dimensional effects of the mini-implant-anchored Forsus Fatigue Resistant Device: A randomized controlled trial. *Angle Orthod.* 2016;86:292-305.
12. Eissa O, El-Shennawy M, Gaballah S, El-Meehy G, El Bialy T. Treatment outcomes of Class II malocclusion cases treated with miniscrew-anchored Forsus Fatigue Resistant Device: A randomized controlled trial. *Angle Orthod.* 2017;87:824-33.
13. Ishaq RA, AlHammedi MS, Fayed MM, Abou El-Ezz A, Mostafa Y. Fixed functional appliances with multi-bracket appliances have no skeletal effect on the mandible: A systematic review and meta-analysis. *Am J OrthodDentofacialOrthop.* 2016;149:612-24.
14. Servello DF, Fallis DW, Alvetro L. Analysis of Class II patients, successfully treated with the straight-wire and Forsus appliances, based on cervical vertebral maturation status. *Angle Orthod.* 2015;85:80-6.
15. Elkordy SA, Abdeldayem R, Fayed MM, Negm I, El Ghouli D, Abouelezz AM. Evaluation of the splint-supported Forsus Fatigue Resistant Device in skeletal Class II growing subjects. *Angle Orthod.* 2021;91:9-21.
16. Unal T, Celikoglu M, Candirli C. Evaluation of the effects of skeletal anchored Forsus FRD using miniplates inserted on mandibular symphysis: a new approach for the treatment of Class II malocclusion. *Angle Orthod.* 2015;85:413-19.
17. Linjawi AI, Abbassy MA. Dentoskeletal effects of the for-sus™ fatigue resistance device in the treatment of class II malocclusion: A systematic review and meta-analysis. *J OrthodSci.* 2018;7:5-18.