

Restorative Dentistry Issue (Removable Prosthodontics, Fixed Prosthodontics, Endodontics, Dental Biomaterials, Operative Dentistry)

10-1-2022

Evaluation of the Remineralizing Effect of Natural Versus Synthetic Materials on Deep Carious Dentin

Dalia M. Elasser

Assistant Lecturer of Operative Dentistry, Faculty of Dental Medicine for Girls, Al-Azhar University,
elasserd27@gmail.com

Maha A. Niazy

Professor of Operative Dentistry, Faculty of Dental Medicine for Girls, Al-Azhar University, Cairo, Egypt,
drniazy_maha@hotmail.com

Wael E. jAMIL

Professor of Operative Dentistry, Faculty of Dental Medicine for Girls, Al-Azhar University, Cairo, Egypt,
jamilwael@yahoo.com

Doaa A. Elsharkawy

Assistant Professor and Head of Operative Dentistry Department, Faculty of Dental Medicine for Girls, Al-Azhar University, Cairo, Egypt, doshar@yahoo.com

Follow this and additional works at: <https://azjd.researchcommons.org/journal>

 Haneya A. Anani
Assistant professor of Medical microbiology and immunology, Faculty of Medicine for Girl, Al-Azhar University, Cairo, Egypt, haneya.amr2008@yahoo.com

How to Cite This Article

Elasser, Dalia M.; Niazy, Maha A.; jAMIL, Wael E.; Elsharkawy, Doaa A.; and A. Anani, Haneya A. (2022) "Evaluation of the Remineralizing Effect of Natural Versus Synthetic Materials on Deep Carious Dentin," *Al-Azhar Journal of Dentistry*. Vol. 9: Iss. 4, Article 4.
DOI: <https://doi.org/10.21608/adjg.2022.100631.1417>

This Original Study is brought to you for free and open access by Al-Azhar Journal of Dentistry. It has been accepted for inclusion in Al-Azhar Journal of Dentistry by an authorized editor of Al-Azhar Journal of Dentistry. For more information, please contact yasmeenmahdy@yahoo.com.



Evaluation of the Remineralizing Effect of Natural Versus Synthetic Materials on Deep Carious Dentin

Dalia M. Elasser^{1*}, Maha A. Niazy², Wael E. jamil³, Doaa A. Elsharkawy⁴, Haneya A. A. Anani⁵

Codex : 04/22.10

azhardentj@azhar.edu.eg

<http://adjg.journals.ekb.eg>

DOI: 10.21608/adjg.2022.100631.1417

Restorative Dentistry
(Removable Prosthodontics, Fixed
Prosthodontics, Endodontics, Dental
Biomaterials, Operative Dentistry)

ABSTRACT

Purpose : The purpose of this in-vivo study was to investigate the remineralizing effects of natural (propolis, hesperidin) versus synthetic agent (silver diamine fluoride with potassium iodide) after treatment of deep carious dentin at different time intervals. **Materials and methods:** Patients with deep carious class I lesions were selected according to inclusion and exclusion criteria. Class I carious lesions were randomly distributed into 4 groups according to treatment material: 1. Propolis, 2. Hesperidin, 3. Silver diamine fluoride with potassium iodide (SDF+KI), and 4. Control group (no treatment). Class I cavities were all prepared using step-wise caries removal technique. The treatment materials were then applied on the remaining carious dentin and restored with a glass ionomer (GIC) restoration. Assessment of remineralization was done by measurement of mineral-density of dentin using digital x-ray machine at baseline, 6-weeks and 12-weeks time intervals. **Results:** Silver diamine fluoride had a higher significant remineralizing effect than control, propolis or hesperidin. While propolis had a higher significant remineralizing effect than hesperidin. **Conclusions:** Both silver diamine fluoride and propolis agents have remarkable effect on remineralization of carious dental tissues.

KEYWORDS

Silver diamine fluoride (SDF),
Propolis, Hesperidin, Stepwise
Excavation

INTRODUCTION

Carious tissue are areas of regional tooth tissue deterioration caused by bacterial flora and acid products. Caries occurs when there is an environmental disturbance between tooth minerals and oral biofilm.

1. Assistant Lecturer of Operative Dentistry, Faculty of Dental Medicine for Girls, Al-Azhar University.
2. Professor of Operative Dentistry, Faculty of Dental Medicine for Girls, Al-Azhar University, Cairo, Egypt.
3. Professor of Operative Dentistry, Faculty of Dental Medicine for Girls, Al-Azhar University, Cairo, Egypt.
4. Assistant Professor and Head of Operative Dentistry Department, Faculty of Dental Medicine for Girls, AL-Azhar University, Cairo, Egypt.
5. Assistant professor of Medical microbiology and immunology, Faculty of Medicine for Girl, Al-Azhar University, Cairo, Egypt.

* Corresponding author email: elasserd27@gmail.com

Biofilms contain microbiological activity that lower the oral pH to an influential level, resulting in demineralization ⁽¹⁾. Although early mineral depletion in teeth is still only apparent under a microscope, it can progress over time producing deep cavities. If prevention of mineral loss failed, it will result in the production of cavities, which can result in irreparable bacterial destruction to the pulp⁽²⁾. The removal of carious dentin is a critical stage in the restoration process. For a long time, the complete removal of carious tissue was the best strategy to cure carious lesions⁽³⁾, however, pulp exposure is a significant concern. An alternative concept for complete caries dentin removal is the stepwise excavation technique⁽⁴⁾. This technique involves retaining a layer of carious dentin above the pulp. After that, a protective liner is placed, and the tooth is sealed for a specific duration (30 to 45 days). The goal of this technique is to stimulate the development of tertiary dentin prior to complete excavation, hence decreasing the likelihood of pulp exposure⁽⁵⁾.

Modern methods of caries prevention are focused on utilizing natural agents such as tannins, terpenoids, flavonoids, alkaloids, etc. Antibacterial activities of these agents have been found to be useful against dental caries. Propolis, a bee product, has drawn interest for its safety and profusion of biological activity. Propolis is a resinous yellow brown to dark brown substance obtained from honey bees from sprouts, exudates of trees and other parts of plants⁽⁶⁾. Similarly, hesperidin is a flavonoid mined from citrus fruits. Hesperidin produces an extensive variety of advantages such as: anti-inflammatory, anti-microbial, collagen cross-linker, opposition to caries development, advancement of the remineralization process and anti-oxidant effects⁽⁷⁾.

A variety of synthetic agents have been used in clinical trials to arrest dentin caries. Some antimicrobial agents contain silver (Ag) such as silver diamine fluoride, which has bactericidal effect. Silver diamine fluoride (SDF) is an affordable, effective, safe, and easy to use agent for caries arresting⁽⁸⁾. The

null hypothesis of this study was that no difference of the remineralizing effect between natural agents (propolis, hesperidin) and synthetic agent (silver diamine fluoride) after treatment of deep carious dentin at different time intervals.

MATERIALS AND METHODS

Trial design and sample size calculation:

The research was planned as an interventional, randomized, prospective, single-center clinical trial. This trial was conducted at restorative dental clinic (RDC) at the Faculty of Dental Medicine for Girls, Al-Azhar University, Cairo; Egypt; from January 2019 to March 2020. Recruitment of participants was done between January 2019 and March 2019. According to Kabil et al 2018⁽⁹⁾. Assuming an alpha (α) level of 0.05 (5%) and a Beta (β) level of 0.20 (20%) i.e., power=80% and an effect size (f) of (0.595); the estimated sample size (n) was a total of (24) samples i.e. (6) for each group. The overall sample size was modified by (25%) to account for possible dropouts to be (32) samples i.e. (8) for each group. G*Power version 3.1.9.2 software was used to determine sample size.

Eligibility criteria:

Inclusion Criteria:

The age ranged from 18–40 years of both genders. Patient had to have at least one permanent molar with deep carious lesion (class I cavity) with no pulpal involvement. Bitewing radiograph showed extension into inner 1/3 of dentin with a radiopaque layer between the carious lesion and the pulp chamber⁽¹⁰⁾.

Exclusion Criteria:

Patients with poor oral hygiene with multiple carious lesions or evidence of rampant caries or any chronic debilitating disease were excluded. Also previously restored teeth or cracked enamel or pregnancy/ breastfeeding were excluded. Spontaneous

sever pain more than 15s after sensitivity cold test that indicate irreversible pulpitis, Internal or external resorption were also excluded.

Trial registration and ethical approval:

The trial was registered online in clinicaltrials.gov database. Protocol Registration and Results System (PRS) with identification number (ID: **NCT04145102**) were given. Data regarding the study description, conditions, study design, arms and interventions, outcome measures, eligibility and contacts/locations were provided. The research protocol, patient information sheet as well as consent form were analyzed and approved by the Ethical Research Committee, Faculty of Dental Medicine For Girls, AI-Azhar University, Cairo; Egypt (**approval code: REC-OP-21-05**).

Patient risk assessment:

The enrolled patients were categorized as medium or high-risk category through the ADA caries risk assessment that is used to formulate an individualized caries risk for developing future caries.

Grouping of patients:

Each patient had at least one permanent molar with deep carious lesion (class I cavity). A total of 32 human teeth (upper and lower, first and second molars) were selected for this study. Patient's Teeth were grouped into four main groups of (8) each, according to the treatment agent applied (A): A₁, Propolis, A₂, Hesperdin, A₃, SDF and A₄, Control (no treatment). radiographic assessment was done at different time intervals (B). The baseline was obtained before treatment (B₀). Each intervention group received applications of their respective agents then were re-evaluated consecutively, after 6 weeks (B₁) and after 12 weeks (B₂).

Randomization, blinding, allocation sequences:

The process was made using an excel sheet with random numbers. A list of sequential number was created, in which each randomly assigned participant in this list occupied a sequence no (ID) from "1 to

8" to be assigned to one of the four groups either propolis or hesperdin or silver diamine fluoride or no treatment control group. The study is a doubled blinded trial

Clinical procedures:

First visit:

a. Patient Preparation:

Each patient's preoperative data was written in predesigned patient's chart. Each patient first received full mouth scaling and polishing to clean the teeth surfaces. Patients were given proper oral hygiene instructions.

b. Cavities' preparation:

Thirty-two cavities were prepared in both upper & lower first and second molars. Pre-operative procedures included radiographs taken using digital x-ray machine (Kodac 2200, France) with plate (digital sensor size 2 Image plate, size 2 Durr Dental, Germany) wrapped in a barrier envelope to prevent cross infection (sensor protection bag, No. SDT-XR57, Smile dental, NiHEN). Local anesthesia was administrated by infiltration technique and nerve block technique for upper and lower, respectively. Heavy sheet rubber dam isolation, and class I cavities were prepared. Selective caries excavation technique was used on the pulpal floor using a double ended spoon excavator until leathery or firm dentin was reached.

Application of treatment agents

After cavity preparation, each group received treatment according to the following instructions (fig.1):

Group A₁ was treated by covering the remaining carious lesions by propolis extract.

Group A₂ was treated by hesperidin powder mixed with distilled water by 3:1 ratio to achieve a green like clay. The mix was applied using an amalgam carrier to the remaining carious lesion.

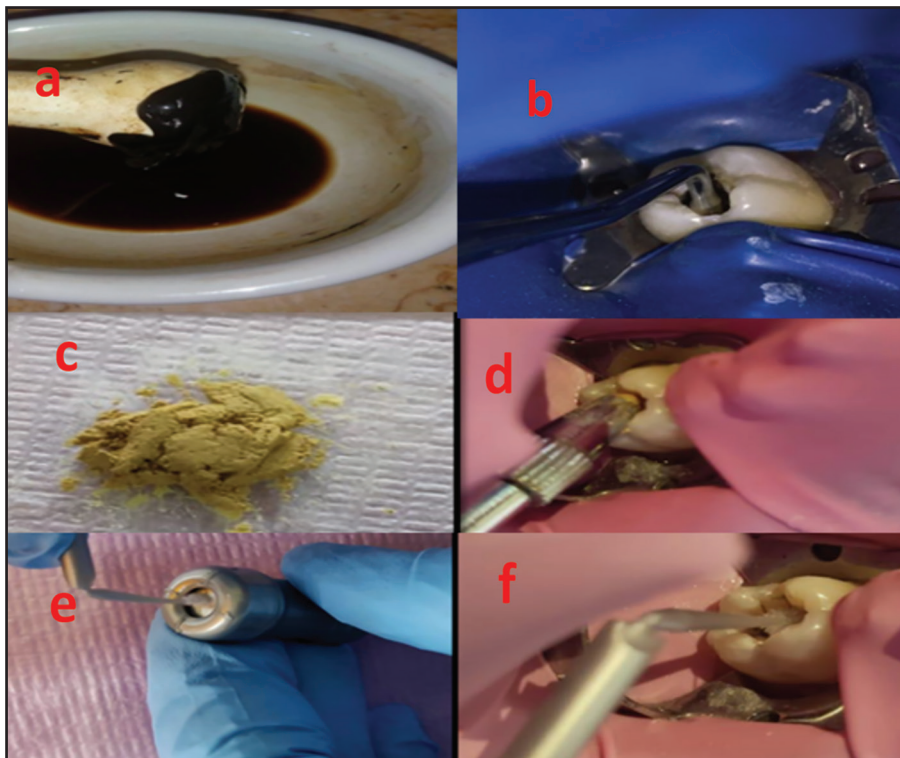


Figure (1): application of treatment agents in each group (a and b: application of propolis extract , c and d: application of hesperidin , e and f: application of silver diamine fluoride)

Group A₃ was treated by SDF+KI (RIVA STAR, SDI, Bayswater, Australia) following manufacturer's instructions. The capsules are colored coded; the SDF is gray colored and it is the first step in which a brush is used to apply the material from the capsule and onto the cavity floor. The second step involves using the potassium iodide (KI) which green coded and applying it until a creamy white precipitate turns clear otherwise staining may occur & finally oil free drying.

Restorative procedures:

Temporary restoration:

After application of the material to be tested a highly viscous GIC restoration material was applied to seal the cavities. Excess material was removed by a sharp explorer and allowed to set for 6 minutes. Finishing by high-speed finishing stones was done, Riva coat applied and cured with LED intensity of 1200 mW/cm² for 20 seconds. Patients would come for a second image after 6 weeks B₁ and recalled after 12 weeks B₂ for a third image.

Final restoration:

In the second visit after temporary restoration and complete caries removal, glass ionomer restoration was applied as a base before final restoration was applied (composite resin material). Selective etching technique utilizing 35% phosphoric acid on enamel surface for 15 seconds was used, rinsed with water for 15 seconds, gentle air water/oil-free for 5 seconds, blot-drying any moisture by absorbent tissue. A micro brush was used in a rubbing motion to apply a single layer of universal adhesive for 10 seconds, air drying for 5 seconds, and then light cured for 20 seconds. Shade selection, 2 mm incremental packing of composite cured for 20 seconds. Finishing and polishing was then done.

Assessment of remineralization

To assess the dentin remineralization, Digital x-ray machine (Kodac 2200, France) was used with DBSWin software at interval of (baseline, 6 weeks and 12 weeks). Using a size 2 digital sensor and posterior parallel kit for image standardization that has two ends: one for x-ray cone & the other for

the sensor. The sensor would then be removed and scanned by Dur Vista Scan and stored. Measurements in each sample fixed for all samples at assessment intervals. 2 lines were drawn, one along the CEJ for reference and a 2nd parallel line to it at the bottom of the cavity. The distance between the 2 lines was standardized for each tooth & measured by a vertical line connecting them. The software was used to determine the length in pixel and fix it for each sample. Three points on this line (at its start, middle and end) were determined. The intensity of these points was calculated by recording each time at follow-up intervals and using the software.

Statistical analysis

Numerical data were explored using Kolmogorov-Smirnov and Shapiro-Wilk tests. Data

showed parametric distribution so; it was represented by mean and standard deviation (SD) values. Two-way ANOVA was used to study the effect of different variables and their interaction. The significance level was set at $P \leq 0.05$ for all tests. Statistical analysis was performed with IBM SPSS Statistics Version 25 for Windows.

RESULTS

The results revealed that silver diamine fluoride group (A_3) recorded higher absolute mean and SD values at 6 weeks and 12 weeks than other groups followed by control group (A_4) then propolis group (A_1) finally hesperidin group (A_2) recorded the least absolute mean and SD values at 6 weeks and 12 weeks.

Radio-density assessment results :(Table 1 and 2)

Table (1): Comparison of mean \pm standard deviation (SD) absolute values of dentin radio density at base line, after 6 weeks and after 12 weeks within each group.

Treatment agents	Time of measurement (mean \pm SD)			f-value	p-value
	Baseline(B_0)	6 weeks(B_1)	12 weeks(B_2)		
Propolis (A_1)	0.63 \pm 0.12 ^b	0.70 \pm 0.14 ^b	1.02 \pm 0.21 ^a	21.75	<0.001*
Hesperdine (A_2)	0.60 \pm 0.11	0.57 \pm 0.12	0.62 \pm 0.12	0.493	0.625ns
SDF (A_3)	0.62 \pm 0.13 ^c	1.03 \pm 0.15 ^b	1.45 \pm 0.10 ^a	63.77	<0.001*
Control group (A_4)	0.63 \pm 0.12 ^c	0.87 \pm 0.14 ^b	1.22 \pm 0.25 ^a	40.81	<0.001*

Different superscript letters indicate a statistically significant difference within the same row *significant ($p \leq 0.05$) ns; non-significant ($p > 0.05$).

Table (2) Mean and standard deviation (SD) values of percent change of dentin density for different materials within each time interval (ΔT).

Time interval (ΔT)	Treatment agents (mean \pm SD)				f-value	p-value
	Propolis (A_1)	Hesperdine (A_2)	SDF (A_3)	Control group (A_4)		
Baseline to 6 weeks (ΔT_1)	16.17 \pm 2.79 ^c	14.22 \pm 2.53 ^c	83.05 \pm 8.78 ^a	29.15 \pm 5.23 ^b	210.72	<0.001*
Baseline to 12 weeks (ΔT_2)	79.39 \pm 9.68 ^c	20.20 \pm 5.53 ^d	110.92 \pm 8.55 ^a	93.29 \pm 7.57 ^b	188.87	<0.001*

Different superscript letters indicate a statistically significant difference within the same row *significant ($p \leq 0.05$).

DISCUSSION

Stepwise treatment (SW) technique was performed in this clinical trial to decrease the further demineralization by isolating the microorganisms from the oral environment to decrease the chance for pulp exposure by stimulating reactions from the dentino pulpal complex, such as dentin sclerosis and tertiary dentin formation. Stepwise excavation has also been advocated to avoid the high cost of invasive root canal treatment, which requires expensive equipment, supplies and highly trained dental health staff. These factors limit access to dental care in countries where financial, human and structural resources are scanty⁽¹¹⁾.

Another challenge was found for the modern approach in restorative dentistry is to induce the remineralization of hypo mineralized carious dentin, and therefore, protecting and preserving the vital pulp. Therefore, after removal of the carious lesions, it is likely that the substrate for clinical bonding to restorative materials will be a combination of sound dentin on the periphery and infected dentin in the center of the lesion. The caries-infected dentin mineral distribution is highly variable, and the extension of the lesion depth is hundreds of microns below the excavated surface. The biomimetic treatment of caries-infected tissues involves guiding remineralization, replicating the physiological mechanisms of tissue mineralization⁽¹²⁾.

This study was designed to evaluate the remineralizing effect of propolis hesperidin as natural agents and silver diamine fluoride as synthetic agent on deep carious dentin.

Propolis (bee glue) is one of many herbal products that possess antibacterial properties. Propolis promotes dental pulp regeneration by preventing microbial infection, inflammation, and pulp necrosis. The antimicrobial activity derives from the flavonoids, phenolic acids and phenolic acid esters. Propolis was selected in this study as it is safe for human application, inexpensive and available without difficulty. Propolis was extracted in this clinical trial to increase concentrations of

flavonoids and aromatic compounds which found at certain ratios in propolis extracts to enhance the consistency and optimize the remineralizing activity⁽¹³⁾.

Similarly, hesperidin is the most active compound of orange fruit. It is a natural flavonoid. Earlier many researchers focus on the biological activity of orange fruit and hesperidin due to, anti-oxidant, anti-inflammatory, collagen cross linker, resistance to caries progression, promotion of the remineralization process⁽¹⁴⁾.

There are also some alternatives in preventing progression of dental caries, one of which is the application of silver diamine fluoride (SDF) on carious lesion. The fluoride content of SDF has the ability to form fluoroapatite, which has higher resistance than hydroxyapatite toward acid challenges⁽¹⁵⁾.

Class I carious lesions were selected to decrease the probability of leakage and communication with the external environment, which is important especially in the in vivo study where teeth are embedded in mineral- containing natural saliva. Carious dentin samples were taken after removing the superficial dentin layer to ensure that the sample contained the largest amount of organisms originally situated in the body of the lesion, not in the dental plaque⁽¹⁶⁾.

All the tested materials were restored with self-cure highly viscous glass ionomer which offer a good seal which is critical factor for success treatment of deep carious lesion. Glass ionomer offer also potential advantages over other restorative materials for cavity sealing following partial caries removal. For instance, GIC chemically bonds well to moist tissue and releases of fluoride, which may aid in the remineralization of carious lesions⁽¹⁷⁾.

Assessment of remineralizing effect was performed at two different periods, one short period of 6 weeks to monitor the initial mineral gaining of the three tested materials. One longer observation periods of 12 weeks were selected to investigate the remineralization of infected dentin which left after

step wise excavation and the progressive changes in the bacteria which found into deep caries.

The pixel grey measurement in digitized radiograph method was used to assess the remineralization. A study⁽¹⁸⁾ reported that, the average pixel grey value can be used to quantitatively monitor caries remineralization, considering that remineralization is a slower process than demineralization, since mineral intake occurs in minute amounts, this quantitative method revealed encouraging results in detecting mineral changes.

Radio density results of this clinical trial revealed that treatment of active carious dentin with different treatment agents (propolis, hesperidin and silver diamine fluoride) showed significantly increase in dentin mineral density at the different time intervals. When comparing the effect of different materials on dentin mineral radio density after 6-week period, results showed that there was a significant increase in the percent change of mineral density of carious dentin (post treatment) in silver diamine fluoride group than control group then propolis group, finally hesperidin group has non-significant increase in the percent change of mineral density of carious dentin. The results of propolis extract group (post treatment) exhibited increasing in the percent change of mineral density of carious dentin after 6 weeks. This may be related to the flavonoid which is the main component of propolis. Flavonoid was able to induce reparative dentin formation through inducing formation of growth factors (TGF)- β_1 , which interact with the extra cellular matrix resulting in collagen formation⁽¹⁹⁾. Furthermore, flavonoids contained in propolis can inhibit microorganisms by denaturing proteins and nucleic acids that can cause coagulation and freezing of proteins. This is in harmony with a previous study which emphasized that the important role of propolis as future remineralizing material and reported that the 30% propolis extract can induce formation of new hydroxyapatite crystals within dentin due to interaction of components of propolis (flavonoids) with the dentin, thus forming crystals which obliterate the dentinal tubule. Therefore, reduce

dentin hypersensitivity. This theory was based on the study in which found that partial dentin bridge formation was detected beneath the pulp-capping material at week 4 when direct pulp capping was performed with propolis-derived flavonoids^(20, 21).

While hesperidin group showed less degree of remineralizing effect on the mean values of mineral density of carious dentin. This can be attributed to the fact that hesperidin is a natural flavonoid, exhibited a chroman ring that can interact with proline-rich proteins such as collagen resulting in stabilization of collagen matrix. This called cross-linking action which improves the mechanical properties of dentin. The stabilized collagen matrix which act as a mechanical barrier to mineral diffusion, thereby resisting mineral loss and promotes mineral gain since it acts as a frame work for mineral deposition⁽²²⁾. Furthermore, non-collagenous proteins in dentin play an important role as on the organic matrix for apatite precipitation. These results were in accordance with the finding obtained by previous studies of hesperidin when compared with chlorohexidin^(23,24). Results showed that there was a remineralization of the surface and the subsurface of carious lesion of dentin when treated with different concentrations of hesperidin. Hesperidin enhances slow mineral precipitation which result in the formation of homogeneous mineral precipitation. In contrast to chlorohexidin group which may be associated with the 'fast' mineral precipitation on the surface faster than ion-diffusion into the subsurface lesion.

On the other hand, silver diamine fluoride group showed significant increase in the percent change of mineral density of carious dentin (post treatment) these results may be directly attributed to high concentration of fluoride in silver diamine fluoride. Silver diamine fluoride reacts with the remaining hydroxyapatite in carious dentin through chemical bond formation. One of the products of the chemical reaction is calcium fluoride CaF_2 , which acts as a fluoride reservoir. During dropout of the ph in the oral environment it can releases fluoride in a slow process to regulate pH and form fluorapatite,

which is more acid resistant. Beside the mechanism of action of fluoride ions silver diamine fluoride is an alkaline solution with pH 10. This condition encourages the formation of covalent bond between Phosphate ions and collagen molecules which are essential for collagen protection⁽²⁵⁾. Also these results are in accordance with a study which revealed that 24-month biannual application of SDF resulted in arrested dentin carious lesions^(26,27). These results were attributed to silver diamine fluoride reaction with hydroxyapatite resulted in calcium fluoride and silver phosphate which will protect tooth structures by the forming a black impermeable layer. This layer can obstruct the dentinal tubules and lower the loss of calcium and phosphorus ions. Silver can activate growth factors GTF enzymes, which prevent the formation of biofilm.

Also control group (dentin restored only with conventional glass ionomer without treatment) exhibited higher mean values of dentin mineral density after 6 weeks than natural agents but less than silver diamine fluoride when compared to base line. It may be directly attributed to the role of fluorine from the glass ionomer cement. The fluoride ion makes a strong bond with a hydroxyapatite crystal, actually better than the hydroxyl group and this result in lower solubility of fluoridated apatite when compared with fluoride-free apatite. This is supported by previous studies which exhibited that the presence of poor organized dentin showed signs of remineralization after 60 days of cavity sealing with glass ionomer^(9,28). Histological reorganization of dentin with intratubular dentin thickening and the formation of a dense collagen network were observed.

Also, when cavity was sealed efficiently by glass ionomer will lead to arresting of caries and also mineral deposition was occurred. This attributed to the absence of bacteria that can produce enzymes cleaving the terminal sugars from the glycoproteins. These bacteria speices are recovered from the dentin. These factors allow host-defense reactions of the dentin-pulp complex with the resulting deposition of calcium. This is also supported by another study

when measured the mineral changes on a longer term showed increased radiographic density during 10 to 15-month follow-up period, indicating mineral gain and dentin remineralization after glass ionomer restoration⁽²⁹⁾.

Assessment time sometimes is a critical factor for healing process and reparative dentin formation. It is also important for reminerlizing agent action completion in accurate manner. Also follow up period is a good chance for any undergoing a sudden change will occurred for the participant in the clinical trial. But in our study, there is a significant difference between natural agent's propolis and synthetic agent silver diamine fluoride this was attributed to the fact that natural agents need more time for action completion may be due to the concentration of active ingredient is lower than the required amount for therapeutic need in comparison with synthetic agent which have more concentrations of active therapeutic agents.

It was become obvious that there was a significant increase in dentin mineral density when treated with different agents over time. The lowest mean value of the mineral density of carious dentin was recorded at the base line and reaches its highest value after 12 weeks for all groups. Also, the results revealed that there was a significant difference between each time interval 6 weeks and 12 weeks within each group (silver diamine fluoride group, control group and propolis group), while hesperidin group showed no significant difference between each time interval 6 weeks and 12 weeks. On the other hand, there was a significant difference between the main groups (silver diamine fluoride group, control group and propolis group) after 12 weeks.

These results agree with several studies, one of these found that the application of standardized propolis extract as a pulpotomy medication caused the formation of a partial mineralized tissue barrier after 21 days, a complete calcified bridge after 42 days. They related these results to the anti-inflammatory property of propolis, which inhibits prostaglandin synthesis and nitric oxide production, stimulates cell immunity, increases the reparative

capacity, and causes less tissue irritation this reaction need more time for completion so propolis need more time for exhibiting good results⁽²⁰⁾. While another study revealed that after 2 months following pulp capping with propolis, dentin bridge was formed in most of the samples^(19,26).

These results supported by another study which compared the remineralizing and antibacterial effect of silver diamine fluoride with propolis fluoride when applied to carious dentin. It was found that silver diamine fluoride has superior antibacterial and remineralizing ability than propolis fluoride. This attributed to the concentration of active material in silver diamine fluoride that reaches 38%, in relation to propolis fluoride which only contains 10% active material. Another cause of propolis fluoride inferior antibacterial ability is the unstable nature of the propolis fluoride mixture⁽³⁰⁾.

On the other hand, results of hesperidin group showed there was no significant difference in mineral density value of carious dentin between the different assessment time (6 weeks and 12 weeks) besides its lesser remineralizing effect on the carious dentin. This may be attributed to its acidic nature since hesperidin was extracted from citrus fruits that are slightly acidic in nature. This low pH media resulted in low calcium and phosphorus ions participation leading to lesser remineralizing and antibacterial effect. This suggestion was going in the same line with another study which revealed that high level of pH is essential for calcium and phosphorous ions release for hard tissue healing⁽³¹⁾.

The null hypothesis that there is no difference between natural and synthetic agents on the remineralizing potential of carious dentin was rejected as the results demonstrated that there was a statistically significant difference between each material after follow up period.

CONCLUSION

Both silver diamine fluoride and propolis agents have remarkable effect on remineralization of carious dental tissues.

RECOMMENDATIONS

Further clinical trials are required to evaluate the pulpal outcome against the applied materials. Further clinical trials also are required to investigate the clinical performance of other natural materials.

Funding

This research did not receive any specific grant from funding agencies in the public, commercial, or not-for-profit sectors.

Conflicts of Interest

The authors have no proprietary, financial, or other personal interest of any nature or kind in any product, service, and/or company that is presented in this article.

Regulatory Statement

This study was conducted in accordance with all the provisions of the local human subjects oversight committee guidelines and policies of: the Ethics Committee of faculty of dental medicine for girls, Al Azhar University with an approval code of REC-OP-21-05.

REFERENCES

1. Yadav K, Prakash S. Dental Caries: A Review. Asian j biomed pharm 2016; 6: 1– 7.
2. O'Mullane DM, Baez RJ, Jones S, Lennon MA, Petersen PE, Rugg-Gunn AJ, et al. Fluoride and Oral Health. Community Dent Health. 2016 ; 33: 69– 99.
3. Anjum S, Ullah A, Khan K, Attaullah M, Khan HU, Ali H, et al. Composition and functional properties of propolis (bee glue): A review. Saudi J Biol Sci. 2018; 1: 26.
4. Alencar Cr, Silva Ol, Mendonça Fl, Andrade Fj. Strategies for control and treatment of carious lesions in deciduous molars: a review of the literature. RGO-Revista Gaúcha de Odontologia. 2016; 64: 62- 9.
5. Banerjee A, Frencken JE, Schwendicke F, Innes NP. Contemporary operative caries management: consensus recommendations on minimally invasive caries removal. Br Dent J. 2017; 223: 215- 22.

6. Amalina R, Soekanto SA, Gunawan HA, Sahlan M. Analysis of CPP-ACP complex in combination with propolis to remineralize enamel. *J Int Dent Med Res*. 2017; 10: 814- 9.
7. Ghorab S, Ibraheim A. Effect of hesperidin on antibacterial activity and adhesive properties of an etch-and-rinse adhesive system. *Egypt Dent J*. 2018; 64: 3801-12.
8. Zhao IS, Gao SS, Hiraishi N, Burrow MF, Duangthip D, Mei ML, et al. Mechanisms of silver diamine fluoride on arresting caries: a literature review. *Int Dent J*. 2018; 68: 67- 76.
9. Kabil NS, Badran AS, Wassel MO. Effect of the addition of chlorhexidine and miswak extract on the clinical performance and antibacterial properties of conventional glass ionomer: an in vivo study. *Int J Pediatr Dent*. 2017; 27: 380- 7.
10. Al-Sabri FA, El-Marakby AM, Abdulrab S, Al-Shamiri HM, Al-Mansoub T. Effect of calcium hydroxide on deep caries dentin:A clinical study. *J Clin Res Dent*. 2019; 2: 1-4.
11. Mostafa NM, Moussa SA. The Effectiveness of the Partial Caries Removal as a Treatment Option in Deep Carious Lesion Management-Review. *Oral Health Dent Sci*. 2018; 2: 1- 3.
12. Braga RR, Habelitz S. Current developments on enamel and dentin remineralization. *Current Oral Health Reports*. 2019; 6: 257-63.
13. Er Yasim. In vitro and in vivo antimicrobial activity of propolis extracts against various plant pathogens. *J Plant Diseases Protect*. 2021; 21: 1- 9.
14. Liu Y, Liu P, Wang L, Shi Y, Chen J, Wang H, et al. Inhibitory effects of citrus lemon oil and limonene on *Streptococcus sobrinus*–Induced dental caries in rats. *Arch Oral Biol*. 2020; 118: 104851- 7.
15. Firouzmandi M, Vasei F, Giti R, Sadeghi H. Effect of silver diamine fluoride and proanthocyanidin on resistance of carious dentin to acid challenges. *PloS one*. 2020; 15: 0238590-607.
16. Baraba A, Kqiku L, Gabrić D, Verzak Z, Miletić I. Efficacy of removal of cariogenic bacteria and carious dentin by ablation using different modes of Er: YAG lasers. *Braz J Med Biol Res*. 2018; 5: 1414- 34.
17. Baghbaninaghadehi F, Armijo-Olivo S, Woodhouse L. Fundamentals of randomization in clinical trial. *Int J Advanced Nutrition Health Sci*. 2016; 4: 174- 87.
18. Labib ME, Hassanein OE, Moussa M, Yassen A, Schwendicke F. Selective versus stepwise removal of deep carious lesions in permanent teeth: a randomised controlled trial from Egypt—an interim analysis. *BMJ*. 2019; 9: 030957- 66.
19. Gargouri W, Kammoun R, Elleuche M, Tlili M, Kechaou N, Ghoul-Mazgar S. Effect of xylitol chewing gum enriched with propolis on dentin remineralization in vitro. *Arch oral Biol*. 2020; 112: 104684- 93.
20. Saleh RS, Nagi SM, Khallaf ME, Abd El-Alim SH, Zaazou MH, Abu-Seida AM, et al. In-vivo assessment of dentin bridge formation after using MTA and experimental Propolis Paste as direct pulp capping material. *Res J Pharma Biol Chem Sci*. 2016; 7: 1244- 50.
21. Darwita RR, Soekanto SA, Finisha AR, Wahyuni HN, Andiani SG. The Effect of Propolis Fluoride on Caries Dentin Activity. *AIP Conference Proceedings*. 2018; 1933: 030021-5.
22. Jain K, Beri L, Kunjir K, Borse N, Neekhara N, Kadam A. Comparative evaluation of the effect of 10% sodium ascorbate, 10% hesperidin, 1% riboflavin 5 phosphate, col-lagen cross-linkers, on the push-out bond strength of fiber postluted to radicular dentin: In vitro study. *J Conserv Dent* 2018; 21: 95- 9.
23. Liu Z, Li F, Zhang L, Yu H, Yu F, Chen J. The effect of active components from citrus fruits on dentin MMPs. *Arch oral biol*. 2017; 83: 111-7.
24. Mandal A, Manohar B, Shetty N, Mathur A, Makhijani B, Sen N. A Comparative Evaluation of Anti-Inflammatory and Antiplatelet Efficacy of Citrus Sinesis Mouthwash and Chlorhexidine Mouthwash. *J Nepalese Society Perio Oral Implant*. 2018 ; 2: 9-13.
25. Firouzmandi M, Shafiei F, Jowkar Z, Nazemi F. Effect of silver diamine fluoride and proanthocyanidin on mechanical properties of caries-affected dentin. *Eur J Dent*. 2019; 13: 255- 60.
26. Satyanegara A, Darwita RR, Setiawati F, Adiatman M, Muhammad R. An invitro study of caries arresting effect of propolis fluoride and silver diamine fluoride on dentin carious lesions. *J Int Dent Med Res*. 2017; 10: 751- 6.
27. Mei ML, Nudelman F, Marzec B, Walker JM, Lo ECM, Walls AW, et al. Formation of Fluorohydroxyapatite with Silver Diamine Fluoride. *J Dent Res*. 2017; 96: 1122– 8.
28. Crystal YO, Niederman R. Evidence-Based Dentistry Update on Silver Diamine Fluoride. *Dent Clin North Am*. 2019; 63: 45– 68.

29. Elgamily H, Ghallab O, El-Sayed H, Nasr M. Antibacterial potency and fluoride release of a glass ionomer restorative material containing different concentrations of natural and chemical products: An in-vitro comparative study. *J Clin Exp Dent*. 2018; 10: 312- 20.
30. Soekanto SA, Marpaung LJ, Djais AA, Rina R. Efficacy of propolis fluoride and nano silver fluoride for inhibition of *Streptococcus mutans* and *Enterococcus faecalis* biofilm formation. *Int J Applied Pharma*. 2017; 9: 51- 4.
31. El-Mal EO, Abu-Seida AM, El Ashry SH. A comparative study of the physicochemical properties of hesperidin, MTA-Angelus and calcium hydroxide as pulp capping materials. *Saudi Dent J*. 2019; 31: 219- 27.