

Restorative Dentistry Issue (Removable Prosthodontics, Fixed Prosthodontics, Endodontics, Dental Biomaterials, Operative Dentistry)

4-1-2023

## Effect of Different Lateral Condylar Guidance Registration Methods and Articulators on Bilateral Balanced Occlusion of Complete Denture

Omnia Ahmed

*Dentist in the ministry of Health., domy7bibi@gmail.com*

Mostafa Abdel-Ghany

*Professor of Removable Prosthodontic Department, Faculty of Dental Medicine for Girls, Al-Azhar University, Cairo, Egypt., mostafama1@hotmail.com*

Naglaa Elkilany

*Professor and Head of Oral Medicine, Periodontology, Diagnosis, and Radiology Department, Faculty of Dental Medicine for Girls, Al-Azhar University, Cairo, Egypt., nelkilani@gmail.com*

Hager El-Sadany

*Lecturer of Removable Prosthodontic Department, Faculty of Dental Medicine for Girls, Al-Azhar University., gogo\_elsadany@yahoo.com*

Follow this and additional works at: <https://azjd.researchcommons.org/journal>



Part of the [Other Dentistry Commons](#)

---

### How to Cite This Article

Ahmed, Omnia; Abdel-Ghany, Mostafa; Elkilany, Naglaa; and El-Sadany, Hager (2023) "Effect of Different Lateral Condylar Guidance Registration Methods and Articulators on Bilateral Balanced Occlusion of Complete Denture," *Al-Azhar Journal of Dentistry*. Vol. 10: Iss. 2, Article 10.

DOI: <https://doi.org/10.58675/2974-4164.1497>

This Original Study is brought to you for free and open access by Al-Azhar Journal of Dentistry. It has been accepted for inclusion in Al-Azhar Journal of Dentistry by an authorized editor of Al-Azhar Journal of Dentistry. For more information, please contact [yasmeenmahdy@yahoo.com](mailto:yasmeenmahdy@yahoo.com).



## Effect of Different Lateral Condylar Guidance Registration Methods and Articulators on Bilateral Balanced Occlusion of Complete Denture

Omnia A. Ahmed <sup>1\*</sup>, Mostafa M. Abdel-Ghany <sup>2</sup>, Naglaa S. Elkilany <sup>3</sup>, Hager F. El-Sadany<sup>4</sup>

Codex : 1-01/23.04

azhardentj@azhar.edu.eg

<http://adjg.journals.ekb.eg>

<https://doi.org/10.58675/2974-4164.1497>

Restorative Dentistry  
(Removable Prosthodontics, Fixed  
Prosthodontics, Endodontics, Dental  
Biomaterials, Operative Dentistry)

### ABSTRACT

**Purpose:** This study was conducted to accomplish the most balanced occlusion of the complete denture through comparing between lateral condylar guidance angle records of Hanau Equation, Gothic arch tracing and Computed tomography (CBCT) using arcon and non arcon articulators. **Materials and methods:** Twelve completely edentulous patients were selected for this study, with age ranging from 50-60 years. Selected patients were free from any temporomandibular disorders or dental diseases. Each patient received a complete denture and then duplicated another one for work. With bilateral balanced occlusion concept. The lateral condylar guidance measured using Hanau equation calculated from protrusive interocclusal records, Gothic arch tracer and Cone beam computed tomography. All records transferred to two types of semi-adjustable articulators Hanau non arcon articulator and Bio-art arcon articulator. Denture adjusted on the both articulator system to measure and achieve the bilateral balanced occlusion. **Results:** In present study comparison between the three methods of right and left lateral condylar guidance registrations Hanau Equation, Cone Beam CT and Gothic arch tracing on both types of articulators shows insignificant difference between right side ( $p=0.443$ ) and left side ( $p=0.094$ ) of lateral condylar guidance and also the balanced occlusion values of right and left side on arcon and non arcon semi-adjustable articulator were statically non-significant. **Conclusions:** Within the outcomes of this study, it could be concluded that to achieve balanced occlusion of complete denture Hanau equation obtained from inter occlusal records with using of Hanau arcon semi-adjustable articulator will be recommended.

### KEYWORDS

Hanau Equation, Gothic arch  
tracer, Cone Beam CT.

1. Dentist in the ministry of Health.
2. Professor of Removable Prosthodontic Department, Faculty of Dental Medicine for Girls, Al-Azhar University, Cairo, Egypt.
3. Professor and Head of Oral Medicine, Periodontology, Diagnosis, and Radiology Department, Faculty of Dental Medicine for Girls, Al-Azhar University, Cairo, Egypt.
4. Lecturer of Removable Prosthodontic Department, Faculty of Dental Medicine for Girls, Al-Azhar University.

\* Corresponding author email: domy7bibi@gmail.com

## INTRODUCTION

The purpose of prosthodontics is to fabricate restorations in harmony with the patient's functional movements, to avoid interferences and subsequent disharmony in the stomatognathic system. The inclination of the condylar path is the most important factor to consider when rehabilitating a patient's oral prosthetics. When the mandible is moved protrusively or laterally from centric relation, the condyle follows a route in relation to the articular eminence. Condylar guidance should be carefully recorded as it has an important role in achieving balanced occlusion<sup>(1)</sup>. Incorrect recording of condylar guidance might result in occlusal interferences, resulting in lost chairside time. These consequences result in low patient satisfaction and a paradoxical occlusion<sup>(2)</sup>. The condylar guidance inclination in semi-adjustable articulators is adjusted either by protrusive (horizontal) or lateral interocclusal registrations recorded in a suitable recording medium<sup>(3)</sup>.

Balanced occlusion in complete dentures is unique, it is a favored occlusal scheme that is adopted for setting denture teeth for conventional complete dentures. It helps to preserve the supporting residual ridge and enhance the stability of dentures. Balanced occlusion provides teeth contacts at both working and balancing sides at the same time hence allowing better distribution of masticatory forces<sup>(4)</sup>.

Despite the routine use of complete dentures to restore edentulous ridges, the average life span of a complete denture is largely unknown. Unsatisfactory complete dentures impact the masticatory ability, comfort, and self-esteem of the wearer. Mandibular movements are complex, and this fact needs to be considered and understood in the use of articulators. The more accurate these articulators have been in simulating mandibular movements; the more complex they have become in design. One of these mandibular movements is the lateral movement which is defined as the grinding movement. It is responsible for chewing food during eating. It is divided into the balancing

and working sides most of the human studies. The balancing condyle moves downward, forward, and medially, while the working condyle rotates it with a slight bodily movement<sup>(5,6)</sup>.

Semi-adjustable articulator allows adjustment to replicate average mandibular movements. Two basic types of semi-adjustable articulators have been introduced: Arcon and non-arcon. These instruments allow for the orientation of the cast relative to the joints. The mechanical condyle on arcon articulators is situated on the lower frame of the articulator to mimic the natural joint's condyle. The articulator's upper frame has a joint cavity that mimics the natural joint fossa. In every eccentric position of the upper member, the Arcon articulator copies the natural bones of the skull and represents a consistent relationship between the maxillary occlusal plane and the condylar guides, while the mechanical condyle is located on the upper half of the frame of non-arcon articulators with the condyle traveling in the other direction, hence the non-Arcon articulator is in reverse. Because of their small size, non-anatomical articulators do not accurately replicate anatomical movements of the mandible<sup>(7-9)</sup>.

Gothic arch tracing is one of the popular graphic methods and is considered as the ideal method for programming the articulator. It is one-dimensional graphic tracing method that can be applied intra-orally and extra-orally to record lateral condylar guidance. Intraoral Gothic arch tracing is a good way to get consistent mandible positions in motion (retrusive, protrusive, and lateral) at a comfortable VDO. The concept is to attach a stylus (Central Bearing Pointer) to one occlusal rim and a plate (Central Bearing Plate) to the opposite occlusal rim. As the mandible moves away from the centric point, the stylus traces or marks the path on the plate. The tracing – is usually in the shape of an arrowhead or “gothic arch”<sup>(10)</sup>.

Because radiographic measurement involves stable bone landmarks and does not depend on the operator or patient's neuromuscular control, studies

have demonstrated that radiology approaches can record condylar guidance more accurately than other methods. However, expensive equipment, inconvenience, and radiation exposure to patients are the main barriers to the broad use of radiographic procedures. Cone beam computed tomography (CBCT) has recently improved its accuracy, safety, and cost, resulting in widespread use in prosthodontics. CBCT is a cutting-edge technology that allows for three-dimensional multiplane sections to be created without superimposition. As a result, the sagittal condylar guidance (SCG) values derived from radiography approaches can be used directly to design the semi-adjustable articulators<sup>(11)</sup>. The present study will be performed to evaluate the effect of different lateral condylar guidance registration methods and articulators on bilateral balanced occlusion of complete dentures. The result of the present study leads to the rejection of the null hypothesis that there was no significant difference in lateral condylar guidance angulation obtained using interocclusal wax records, Gothic arch tracing, and CBCT<sup>(12)</sup>.

## MATERIALS AND METHODS

Twelve completely edentulous male patients were selected, with an age range from 50-60 years (average of 55 years). The patients were selected from the outpatient Clinic of the Removable Prosthodontics Department, Faculty of Dental Medicine for Girls, AL-Azhar University. They were all free from any oral or debilitating systemic diseases, or temporomandibular joint disorders and with moderately resorbed maxillary and mandibular alveolar ridges that were covered with firm, thick, healthy, and compressible mucosa free from any signs of inflammation or ulceration. Patients with bad habits such as smoking, or alcohol drinking were excluded.

Before starting the study, all patients were informed about the steps of this study, accepted this dental treatment, and signed a written consent with the Research Ethics Committee (REC) approval (REC-PR-21-01). Thorough medical and dental

history was carried out for all patients including asking the patient about the cause and timing of teeth loss. Clinical examination of each patient's TMJ, ridge, mucosa, lips, muscles, and skin were carried out<sup>(13)</sup>.

Maxillary and mandibular primary impressions were made using metal stock trays with suitable sizes for each patient and alginate impression materials. Auto-polymerizing acrylic resin special trays were constructed on study casts of maxillary and mandibular jaws for tracing definitive impressions using green stick compound (Hiflex, India) and zinc oxide and eugenol (Cavex, Holland), these steps were duplicated.

Maxillomandibular relations records were made using auto-polymerizing acrylic resin (Rapid stone, keel, USA) used for maxillary and mandibular trial denture bases, and modeling wax occlusion rims were constructed and adjusted in the patient's mouth. Facebow records were carried out using the Hanau face bow (Whip Mix Corporation, USA) and transfer maxillary occlusion rim with bite records to the Hanau 96 H2 articulator (Whip Mix Corporation, USA) and then maxillary cast mounted to the upper member of the articulator using plaster.

Maxillary and mandibular occlusion blocks were inserted into the patient's mouth to record centric relation using interocclusal record wax (Cavex, Holland) then separated from the mandibular record block and kept in cold water. Then two layers of softened wax approximately 4mm were added to the mandibular occlusion block, and the patient was instructed to protrude his mandible about 6mm and close to record blocks together in a protrusive position. The wax record was separated and removed from the patient's mouth and kept in cold water.

The mandibular record block was seated and sealed firmly to the mandibular cast using molten wax. The interocclusal centric relation record was placed on the maxillary record block. The mandibular cast was placed on the CR and checked for stability. The mandibular cast was mounted to

the lower member of the articulator using plaster. Then the protrusive interocclusal wax record was applied to the occlusion blocks on a semi-adjustable Hanau 96 H2 articulator to adjust the Horizontal condylar guidance of both sides. Lateral condylar guidance calculated from horizontal values by Hanau equation <sup>(14)</sup>:

$$L = H/8 + 12$$

Then maxillary and mandibular teeth were set up according to the mechanical and esthetic requirements in balanced articulation using anatomical acrylic teeth (Acrostone Manufacturing and Import Co, Egypt). Denture was waxed up, tried in the patient's mouth, and processed into heat-cured acrylic resin (Rapid stone, kee, USA). It was then delivered to the patient after carrying all necessary adjustments

A maxillary face bow record was carried out using the maxillary denture. Remounting of finished denture applied twice on Hanau articulator then on bio art arcon articulator. The adjustment of the occlusion for the finished denture was made by using centric, protrusive, and lateral records without teeth contact. The occlusal interference was removed until even contacts through the arch were achieved <sup>(15)</sup>.

A mix of silicon impression material was poured into the fitting surface of the denture and then flasking. The duplicated denture was checked for proper extension, retention, stability, and fine adjustment of occlusion was carried out inside the patient's mouth. Prepare duplicated denture for our study including remounting on both semi adjustable articulators as previous steps, occlusal adjustment. Metal tubes with internal diameter 0.44 mm. was cemented in place of the maxillary second molar area facing square recording paper in the mandibular denture to trace bucco-lingual, mesiodistal and direct lines during protrusive and lateral movement of the mandible then record the angles of this triangle. Compare the results from different methods as it will be represented in this study, Figure (1).

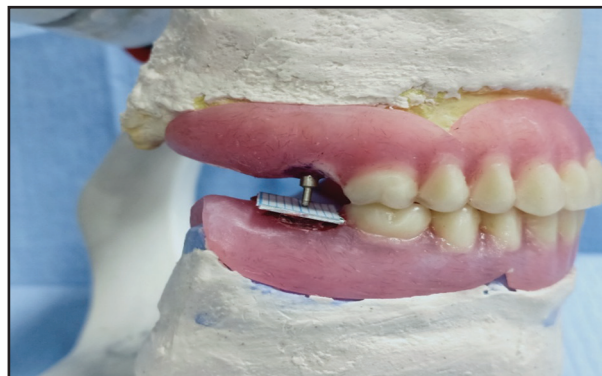


Figure (1): Metal tube cemented in upper second molar area.

Registration of the lateral condylar guidance<sup>(16,17)</sup>, through Hanau Equation which obtained from the protrusive interocclusal record, record the horizontal condylar guide angles then calculate the lateral condylar guide angles through the equation and adjust them on the articulators. The carrier of the intraoral Gothic arch tracer (Gerber Condylator, Swiss) was attached to the occlusal surface of the mandibular duplicated denture by auto-polymerizing acrylic resin, the tracing pointer was adjusted to be centrally across a line joining the position premolars while the tracing plate was attached to the occlusal surface of the maxillary duplicated denture and covered with thin film of blue soft wax to produce the tracing. The maxillary and mandibular dentures with the tracer attached to them, were inserted into the patient's mouth while the tracing point was adjusted to keep the occlusal surface of the maxillary and mandibular dentures slightly apart. The patient was instructed to perform protrusive-retrusive, right- retrusive and left-retrusive movements while the tracing point kept in contact with the tracing plate. Then dentures removed from patient's mouth and the arrow that was traced should be clearly identified to record lateral condylar path. The tracing arrow over the tracing plate was scanned and printed by the computer then magnified 10 times. Both angles right and left between the protrusive and lateral right and left condylar paths were measured using the protractor to the nearest 0.5 degree.



The left and right lateral condylar guidance were derived from the following formula <sup>(18)</sup>:

$$L = 1.06 BP - 45.$$

Where L was the lateral condylar angle and BP was the angle between the lateral border paths of the patient and the protrusive path.

CBCT CRANEX 3Dx machine (Helsinki, Finland) was used in this study. The patient was placed on the machine and field of vision (FOV) was adjusted guided by laser lines for scanning <sup>(18)</sup>. Cone

beam CT was applied on the patient while placed on the machine in upright position looking forward rested his chin on the chin rest, then the patient was guided to close his mouth in centric occlusion then moves his mandible laterally. After the patient exposure, the images were acquired in a process called (image acquisition) on a computer connected to the cone beam machine, were these images are called (basis images) which were performed using a third-party software Ondemand3D ver.1.0.10 (Seoul, South Korea), Figure (2).

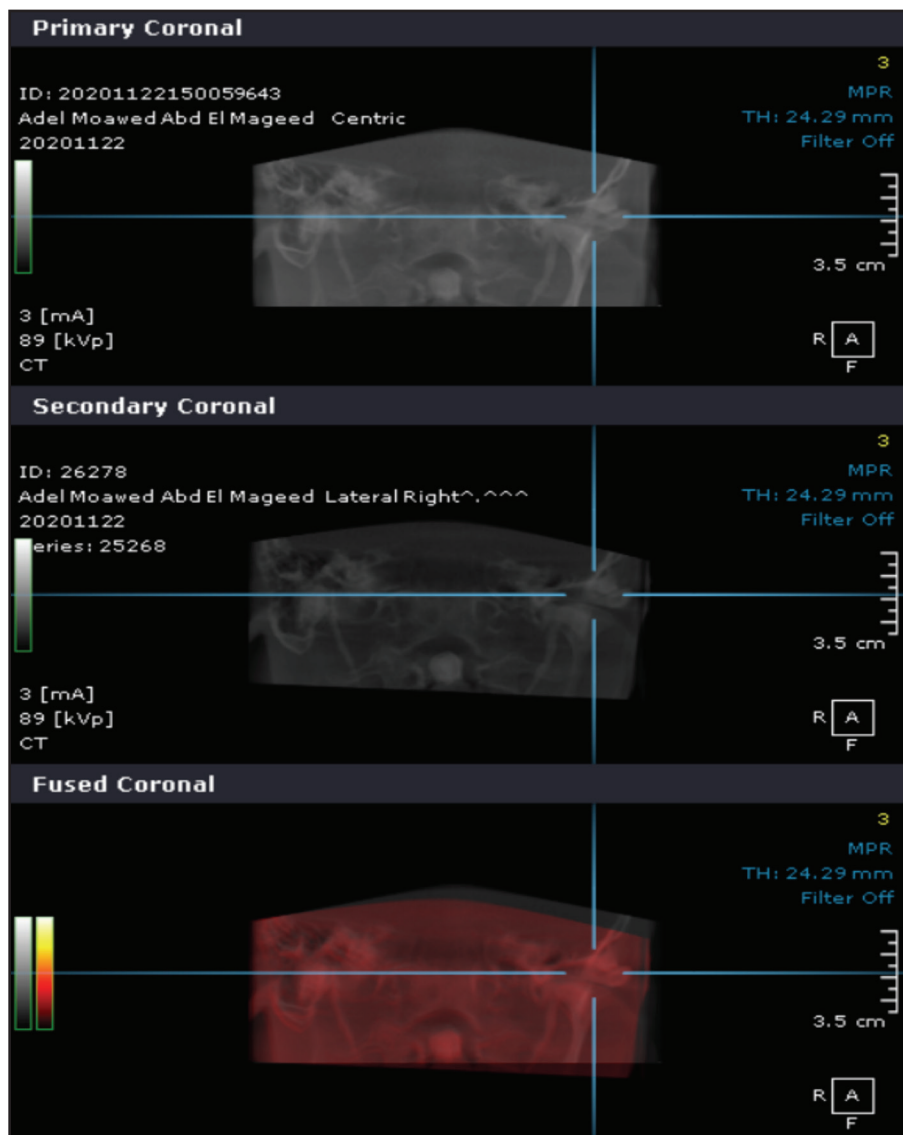


Figure (2): Cone beam CT showing condyle in centric and lateral movement.

Both images (centric & lateral balancing condyle) were superimposed together in three dimensions (Axial, coronal & Sagittal) as follows: centric image was set as the primary image & the lateral working image was set as a secondary image. Each image was given a specific color different from the other image to differentiate between the primary & secondary images during the fusion process. Image fusion was performed by first obtaining the same plane in both, centric & lateral images in the axial plane roughly. The lateral condylar path was obtained for the balancing condyle by drawing a line tangent the highest point of the condyle in maximum intercuspation and in lateral position. The angle between two tangent lines was measured, Fig (3).

This procedure was made twice for each balancing condyle of the same patient and the mean angle was obtained and tabulated. For the working condyle the Bennett movement was measured by measuring the amount of working condyle movement laterally from the maximum intercuspation to the lateral position. The measured angles tabulated for each patient were then applied on the articulators to record the balanced occlusion.

### Statistical Analysis

Numerical data were explored for normality by checking the data distribution, calculating the mean and median values using Kolmogorov-Smirnov and Shapiro-Wilk tests. Data showed parametric distribution so; they were represented by mean and standard deviation (SD) values and were analyzed

using paired t-test. The significance level was set at  $p \leq 0.05$  for all tests. Statistical analysis was performed with IBM® SPSS® (SPSS Inc., IBM Corporation, NY, USA) Statistics Version 26 for Windows.

### RESULTS

Comparison between three lateral condylar guidance registration methods Hanau equation, Gothic arch tracer and Cone Beam CT on two types of semi-adjustable articulators Hanau and Bio art in this study on right side revealed that the Hanau articulator had a higher value with mean difference = 16.41 and standard deviation= 1.02 than that of Bio-art with mean difference = 15.94 and standard deviation= 1.13, yet the difference was not statistically significant while  $p=0.443$ . The mean difference for the left side was 16.39 and standard deviation 0.35 of Hanau articulator which higher than Bio-art that shows mean difference = 15.26 and SD= 0.86 which yet the difference was not statistically significant  $p=0.094$  of values of lateral condylar guidance angles obtained from the three registration methods on both articulator systems.

Effect of these different registration records using Hanau non-arcon and Bio-art arcon articulators on bilateral balanced occlusion revealed that the mean difference for the right side of Bio-art articulator was 2.31 and standard deviation difference was 0.24 higher than Hanau articulator with value of  $P=0.603$ , while mean of difference of Hanau articulator = 2.22 and SD=0.34. The mean difference for left

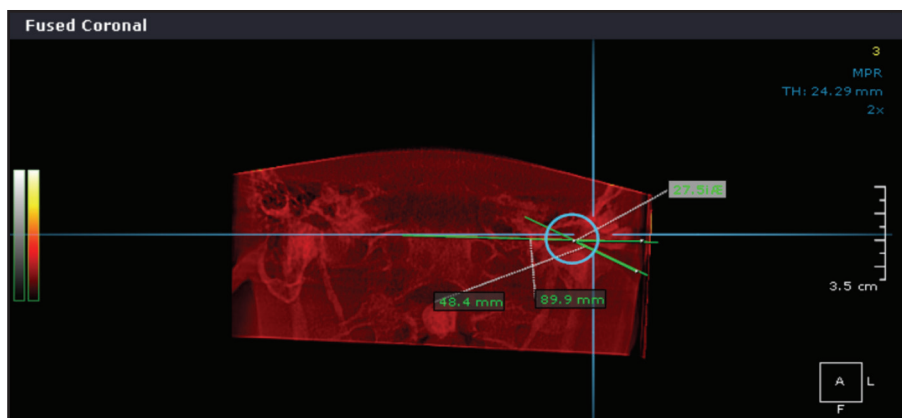


Figure (3) Superimposition of condyle in centric and lateral movement to measure the Bennet angle

side of Hanau articulator was 2.31 and SD= 0.53 higher than Bio-art articulator with mean difference =2.24 and standard deviation difference was 0.18 with value of P was 0.743 yet the difference was not statistically significant, Fig (5). These results represent the value of  $P > 0.05$  of values of lateral

guidance angle on both sides represent non-significant difference between Gothic tracer, Hanau equation and cone beam CT on both articulator systems (table 1). Bio-art and Hanau articulators recorded values of balanced contact measurements represented in bar chart below, Figure (4).

**Table (1)** Mean, Standard deviation (SD), paired *t* test values of balanced contact measurements with different lateral condylar path inclination records for both articulators.

Group	Side	Measure	Lateral path inclination records (mean±SD)		t-value	P-value
			Bioart	Hanu		
Hanau	Right	MD	1.77±0.18	2.07±0.35	1.77	0.128ns
		BL	1.58±0.26	1.61±0.37	0.24	0.818ns
		Direct	2.31±0.24	2.22±0.34	0.54	0.607ns
	Left	MD	1.80±0.31	2.03±0.29	1.30	0.240ns
		BL	1.51±0.31	1.71±0.61	0.78	0.467ns
		Direct	2.24±0.18	2.31±0.53	0.36	0.733ns
Gothic	Right	MD	1.79±0.16	2.35±0.39	3.44	0.014*
		BL	1.32±0.30	1.58±0.39	1.72	0.136ns
		Direct	2.15±0.36	2.46±0.58	1.10	0.313ns
	Left	MD	1.81±0.28	2.17±0.44	1.85	0.113ns
		BL	1.55±0.37	1.69±0.26	0.65	0.542ns
		Direct	2.24±0.48	2.50±0.40	1.07	0.326ns
CBCT	Right	MD	1.75±0.26	1.68±0.49	0.43	0.685ns
		BL	1.42±0.25	1.44±0.57	0.11	0.916ns
		Direct	2.04±0.23	2.07±0.64	0.12	0.912ns
	Left	MD	1.85±0.40	1.95±0.66	0.34	0.747ns
		BL	1.48±0.18	1.51±0.49	0.16	0.880ns
		Direct	2.19±0.35	2.31±0.61	0.37	0.727ns

ns; non-significant ( $p > 0.05$ )

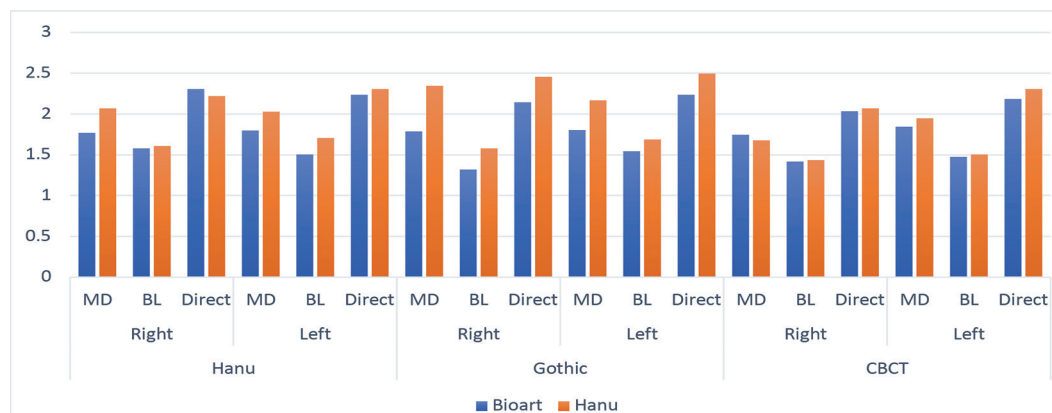


Fig (4): Bar chart showing average values of balanced contact measurements with different lateral condylar path inclination records for both articulators.



## DISCUSSION

Hanau 92 had the highest level of statistical significance when arcon and Non-arcon articulators were compared in the current study.

Articulators usage needs to be considered with complicated and tangly mandibular movements. So more accurate articulator results in simulating mandibular movements that more sophisticated in design. Fully adjustable articulator mimic mandibular movements most accurately but it limited in usage due to complexity of record determination and articulator adjustment as agreed by many authors (Bhawsar SV, Marathe AS and Ansari SA) while semi-adjustable articulators are more favorable due to using individual static records make it more accurate. However, most of the studies revealed that these articulators don't emulate the patient's temporomandibular joint (TMJ) anatomy and are based on average condylar accuracy<sup>(19)</sup>. This the rationale behind using two types of semi adjustable articulators in this study; Bio-art arcon and Hanau Non arcon 96 H2 series articulator and exclude fully adjustable articulator.

The results in present study come in agree with Tannamala which conducted a study compared the sagittal condylar angles set in the Hanau articulator by using an intraoral protrusive record to those angles obtained using a panoramic radiographic image and concluded that the protrusive condylar guidance angles obtained by panoramic radiograph were not statistically significant when compared with the angles obtained by protrusive interocclusal record method. Hence the records thus obtained by this method could be used to program the semi-adjustable articulator to obtain clinically acceptable restorations<sup>(20,21)</sup>.

This study in tended to achieve bilateral balanced occlusion of the conventional complete denture as balanced occlusion can help in better chewing efficiency, maintaining the stability of the denture and ensure even pressure on the residual ridge<sup>(22)</sup>.

Hanau equation by interocclusal records are the most common method used to adjust different types of semi-adjustable articulators for measuring the lateral condylar guidance; because it is simple, easy, quick, not expensive, and does not require specialized devices or machinery<sup>(23)</sup>. During registration of protrusive interocclusal records to calculate Hanau equation, it is important to keep the distance of protrusion the same for both articulators because the condylar guidance changes with the degree of protrusion. Accordingly, the protrusive interocclusal wax record was obtained at 6 mm of protrusive movement then calculate the Hanau equation from the resulted angles<sup>(24)</sup>.

Gothic arch tracing is the most commonly used graphic method and is considered as the ideal method in programming the articulator as presented by Shetty PP and Chowdhary R, it is one-dimensional graphic tracing method usually recorded in horizontal plane and can be recorded intraorally and extraorally<sup>(25)</sup>. Gothic arch methods have been used to record centric relation and condylar guidance but there is certain disadvantage of this technique including it requires good ridge anatomy, experienced dentist and this method is time consuming, the effect of tissue resiliency, stable denture bases, patient co-operation and neuromuscular co-ordination, insufficient inter ridge dimension. Gothic tracer was found as delicate technique may exhausting patient due to excessive mandibular movement to produce head arrow tracing in accurate form<sup>(26)</sup>.

The CT volumetric acquisition always gives complete information about the bone and dental structures of the masticatory apparatus that Cone beam computed tomography measurement involves stable bony landmarks and can be standardized. The centric relation, the right laterality and the left laterality were determined<sup>(27,28)</sup>. In the present study the Cone Beam images was used for recording Bennett angle and movement. However computed tomography scan was greater than those obtained from other clinical methods according to most literature which not coincide with the results of

this study. Conventional complete denture Hanau equation verified on Hanau non arcon semi-adjustable articulator is recommended <sup>(29)</sup>.

## CONCLUSION

Within the outcomes of this study; It could be concluded that there were no significant differences between the angles for both right and left sides for all methods investigated. All three methods showed comparable lateral condylar path angulations with insignificant differences regardless of the type of articulator used (whether Arcon or Non Arcon semi adjustable articulator).

## ACKNOWLEDGMENT

I would like to thank Dr. Shereen Mohamed Qabeel for her considerable support, valuable supervision. Her guidance helped me in all the time of research.

## RECOMMENDATION

To accomplish bilateral balanced occlusion for complete denture, using Hanau equation obtained from adequate interocclusal record on Hanau non arcon semi adjustable articulator is favorable because its ease of use with limited chance of errors and it less time-consuming method with less complexity of non arcon semi adjustable articulator.

## CONFLICT OF INTEREST

The authors have no conflict of interest relevant to this study.

## FUNDING

No external financial support was received.

## REFERENCES

1. Prasad KD, Shah N, Hegde C. A clinico-radiographic analysis of sagittal condylar guidance determined by protrusive interocclusal registration and panoramic radiographic images in humans. *Contemp Clin Dent*. 2012; 3: 383.
2. Mawani D, Muddugangadhar BC, Das A, Mukhopadhyay A. Comparative evaluation of condylar inclination in edentulous subjects as determined by two radiographic methods: Orthopantomograph and conebeam computed tomography—An in vivo study. *J Ind Prosth S*. 2019; 19: 113-21.
3. Rosenstiel SF, Land MF. Contemporary fixed prosthodontics-e-book. Elsevier Health Sciences, 2015.
4. Poštić SD. Influence of balanced occlusion in complete dentures on the decrease in reduction of an edentulous ridge. *Vojnosanit Pregl*. 2012; 69: 1055-60.
5. Carlson GL, Hultgren BW, Rzepecki SM, Marshall MC, Hillukka T, inventors. System and method for measuring and simulating mandibular movement. United States patent application US 15/578,206. 2018.
6. Taylor M, Masood M, Mnataganian G. Longevity of complete dentures: A systematic review and meta-analysis. *J Prosthet Dent*. 2021; 125: 611-9.
7. Azer SS, Kemper E. The patient-specific anatomical articulator. *J Prosthet Dent*. 2022; 128: 1158-64.
8. Manshaee F, Shakerin H. Rotation coordinating device for improving condylar guidance settings of nonarcon articulators: Part 1. *Dent R J*. 2018; 15: 313-20.
9. Culp T, Culp L. The dental reference manual: a daily guide for students and practitioners 1<sup>st</sup> ed. Springer, Cham, 2017.
10. Shetty S, Kunta M, Shenoy K. A clinico-radiographic study to compare and co-relate sagittal condylar guidance determined by intraoral gothic arch tracing method and panoramic radiograph in completely edentulous patients. *J Indian Prosthodont*. 2018; 18:19.
11. Amarnath G, Kumar U, Hilal M, Muddugangadhar B, Anshuraj K, Shruthi C. Comparison of cone beam computed tomography, orthopantomography with direct ridge mapping for presurgical planning to place implants in cadaveric mandibles: an ex-vivo study. *J Int Oral Health*. 2015; 7: 38.
12. Verma S, Kalra T, Kumar M, Bansal A. Comparative analysis of condylar guidance angle obtained by protrusive interocclusal records and radiographic methods in edentulous patients: an in vivo study. *Dent J Adv Stud*. 2022; 10: 87-94
13. Maxwell D, Odang RW, Koesmaningati H. Correlation of masticatory muscle activity with masticatory ability in complete denture patients with canine guidance and balanced occlusion. In *Journal of Physics: Conference Series*. IOP Publishing. 2017; 1: 012015.

14. Praveena K. Evaluation of lateral condylar guidance by clinical and radiographic methods–hanau’s formula revisited: an invivo Study (Doctoral dissertation, Vivekanandha Dental College for Women, Tiruchengode 2015).
15. Praveena K, Ajay R, Devaki V, Balu K, Preethisuganya S, Menaga V. A comparative evaluation of lateral condylar guidance by clinical and radiographic methods–Hanau’s formula revisited. *J Pharm Bioallied Sci.* 2021;13:537.
16. Lee YJ, Kim JH, Ko KH, Huh YH, Park CJ, Cho LR. Effectiveness of clinical remounting improving balanced occlusion of complete dentures. *J Korean Acad Prosthodont.* 2020;58:328-34.
17. Amin B, Kumar GP, Raj B. Assessment and comparison of the condylar guidance by protrusive interocclusal records and panoramic radiographic imaging in edentulous and dentulous individuals. *Int J Prosthodont Restor Dent.* 2018;8:10-6.
18. Hamilton A, Griseto N, Negreiros WM, Gallucci GO. Digital articulation of a complete arch fixed implant prosthesis using the implant prosthetic connections: A dental technique. *J Prosthet Dent.* 2022 Apr 14.
19. Bhawsar SV, Marathe AS, Ansari SA. Evaluation of Hanau’s formula in determination of lateral condylar guidance: A clinical research study. *J Indian Prosthodont Soc.* 2015; 15:326.
20. Kumari VV, Anehosur GV, Meshramkar R, Nadiger RK, Lekha K. An in vivo study to compare and correlate sagittal condylar guidance obtained by radiographic and extra-oral gothic arch tracing method in edentulous patients. *Eur. J. Prosthodont.* 2016;4:12.
21. Tannamala PK, Pulagam M, Pottem SR, Swapna B. Condylar guidance: Correlation between protrusive interocclusal record and panoramic radiographic image: A pilot study. *J Prosthodont.* 2012;21:181-4
22. Shetty R, Shetty S, Shetty N, Pingge SS, Zahid M, Suhaim KS. Comparative evaluation of lateral condylar guidance angle measured using hanau’s formula & lateral interocclusal records. *J Evol Med Dent Sci.* 2021 Jun 28;10:1917-21.
23. Bhandari A, Manandhar A, Singh RK, Suwal P, Parajuli PK. A Comparative study to measure the horizontal condylar guidance obtained by protrusive interocclusal records and panoramic radiographic images in completely edentulous patients. *J Coll Med Sci -Nepal.* 2018;14:21-7.
24. Amin B, Kumar GP, Raj B. Assessment and comparison of the condylar guidance by protrusive interocclusal records and panoramic radiographic imaging in edentulous and dentulous individuals. *Int J Prosthodont Restor Dent.* 2018;8:10-6.
25. Shetty PP, Chowdhary R. Hybrid tracer-A modified novel extra oral tracer. *J Oral Biol Craniofac Res.* 2022;12: 859-62.
26. Shetty S, Kunta M, Shenoy K. A clinico-radiographic study to compare and co-relate sagittal condylar guidance determined by intraoral gothic arch tracing method and panoramic radiograph in completely edentulous patients. *J Indian Prosthodont Soc.* 2018;18:19.
27. Das A, Muddugangadhar BC, Mawani DP, Mukhopadhyay A. Comparative evaluation of sagittal condylar guidance obtained from a clinical method and with cone beam computed tomography in dentate individuals. *J Prosth Dent.* 2021;125:753-7.
28. Pero AC, Scavassin PM, Policastro VB, de Oliveira Júnior NM, Marin DO, da Silva MD, et al. Masticatory function in complete denture wearers varying degree of mandibular bone resorption and occlusion concept: canine-guided occlusion versus bilateral balanced occlusion in a cross-over trial. *J Prosthodont Res.* 2019;63:421-7.
29. Fadhel N, Hassan MA, Hassan NA. Multiplanner Measurement to the clicked tempromandibular joint (condylar process and articular disk) with conbeam computed tomography. *Med Legal Update.* 2020 Jul 24;20:491-7