

Oral Medicine and Surgical Sciences Issue (Oral Medicine, Oral and Maxillofacial Surgery, Oral Pathology, Oral Biology)

4-1-2023

Clinical Evaluation of Different Techniques of Gingival Depigmentation

Nahla Meligy

Dentist at Medical Administration Center, Al-Azhar University, nahlameligy@gmail.com

Omneya E. Ahmed

Lecturer of Oral Medicine, Periodontology, Oral Diagnosis and Radiology Department, Faculty of Dental Medicine for Girls, Al-Azhar University, Cairo, Egypt.

Osama S. El-Shall

Professor of Oral Medicine, Periodontology, Oral Diagnosis and Radiology Department, Faculty of Dental Medicine for Girls, Al-Azhar University, Cairo, Egypt

Follow this and additional works at: <https://azjd.researchcommons.org/journal>



Part of the [Dentistry Commons](#)

How to Cite This Article

Meligy, Nahla; Ahmed, Omneya E.; and El-Shall, Osama S. (2023) "Clinical Evaluation of Different Techniques of Gingival Depigmentation," *Al-Azhar Journal of Dentistry*. Vol. 10: Iss. 1, Article 34. DOI: <https://doi.org/10.58675/2974-4164.1542>

This Original Study is brought to you for free and open access by Al-Azhar Journal of Dentistry. It has been accepted for inclusion in Al-Azhar Journal of Dentistry by an authorized editor of Al-Azhar Journal of Dentistry. For more information, please contact yasmeenmahdy@yahoo.com.



Clinical Evaluation of Different Techniques of Gingival Depigmentation

Nahla Meligy^{1*}, Omneya E. Ahmed ², Osama S. EL-Shall ³

Codex : 2-04/23.04

azhardentj@azhar.edu.eg

http://adjg.journals.ekb.eg

DOI: <https://doi.org/10.58675/2974-4164.1542>

Oral Medicine & Surgical Sciences
(Oral Medicine, Oral & Maxillofacial
Surgery, Oral Pathology, Oral Biology)

ABSTRACT

Purpose: The current study aimed to assess the difference in the clinical outcome of the removal of gingival hyperpigmentation and patient satisfaction of different techniques used for gingival depigmentation, namely; scalpel surgical technique, laser therapy, and vitamin C injection. **Subject and methods:** A total of thirty patients with gingival hyperpigmentation were included in this study. They were randomly divided into three equivalent groups to be managed with different gingival depigmentation techniques. Group I (control group; n = 10) involved patients treated with the scalpel surgical technique using scalpel 15. Group II (test group 1; n = 10) involved patients treated with diode laser. Group III (test group 2; n = 10) involved patients treated through Ascorbic acid injections. All patients were followed up with for 3 months. Clinically, pain was evaluated for each patient by using visual analog scale (VAS), Calculation of surface area of gingival pigmentation and re-pigmentation was assessed. Calculation of darkness value of gingiva using Image J intensity was assessed. **Results:** Laser and Ascorbic acid groups showed less pain at the surgical site and with the follow up, all three groups showed no sign of re-pigmentation after 3 months. **Conclusion:** The aesthetic effects of these three alternative treatments were outstanding and comparable, according to the current study with significant difference statically in pain perception, intensity darkness value and insignificant difference statically in re-pigmentation after 3 months follow up.

INTRODUCTION

A smile conveys enjoyment, self-assurance, confidence, and beauty. Gingiva, teeth and lips, are important parts of a beautiful and confident smile⁽¹⁾.

KEYWORDS

Depigmentation, Diode Laser,
Ascorbic acid injection.

1. Dentist at Medical Administration Center, Al-Azhar University.
2. Lecturer of Oral Medicine, Periodontology, Oral Diagnosis and Radiology Department, Faculty of Dental Medicine for Girls, Al-Azhar University, Cairo, Egypt.
3. Professor of Oral Medicine, Periodontology, Oral Diagnosis and Radiology Department, Faculty of Dental Medicine for Girls, Al-Azhar University, Cairo, Egypt.

* Corresponding author email: nahlameligy@gmail.com

Gingival hyperpigmentation caused by excessive production of melanin can be unsightly, especially if it is paired with a prominent smile line, higher anterior labial segment, and is uneven in appearance. It is a condition that affects people of different ethnicities⁽¹⁾.

Normal gingiva is a coral pink color. In different races and areas, the texture and color of the gingiva may vary. Gingival pigmentation can take the form of a broad purple discoloration or irregularly formed brown patches whether dark or light or black patches, strikes, or strands⁽²⁾.

The color of your gingiva is dependent on many factors. The number and size of capillaries, thickness of epithelium, keratinization degree, and pigments which are present in the gingival epithelium all contribute to the gingival color. The primary pigments which contribute to the normal color of the oral mucosa are melanin, carotene, decreased haemoglobin, and oxy-haemoglobin⁽³⁾.

Melanocytes are the cells that produce melanin, which is the pigment that causes the abnormal gingival pigmentation. It is common knowledge that melanocytes exist in the oral epithelium. Melanin protects the skin from harmful environmental factors like UV light and reactive oxygen species⁽⁴⁾.

Excessive discoloration and darkening of the gingival mucosa are known as gingival hyperpigmentation. It is defined as increased melanin accumulation in the epithelium's basal and suprabasal cell layers, which is not considered a pathological condition⁽⁵⁾.

Removal of the gingival hyperpigmentation is a periodontal aesthetic procedure that removes or reduces the excess gingival pigmentation using a variety of methods. It's primarily due to patient's need for better aesthetics and more beautiful smile. Depigmentation treatments of various kinds have been used. The technique should be decided by the operator based on clinical experience and personal preference⁽⁶⁻⁸⁾.

The goal of depigmentation is to give patient a better esthetic appearance with optimal comfort. There are various treatment modalities for esthetic depigmentation such as abrasion of tissues with diamond bur, slicing with scalpel, cryosurgery, electrosurgery, gingivectomy with free gingival autografting, Ascorbic acid injection and various types of lasers. This all come with different patient comfort, operator's ease, complications, clinical outcome, and prognosis^(6,7).

Almost no patient discomfort, minimal or no anesthesia, operator friendliness, low technique sensitivity, negligible or no bleeding during surgery, minimal destruction of the surrounding tissues, minimal post-surgical complications and lastly an excellent outcome which can be sustained over a prolonged period of time are all requirements for an ideal treatment method⁽⁹⁾.

The Scalpel surgical procedure was one of the earliest methods for gingival depigmentation to be reported, and it is now still the most popular and gold standard treatment modality. This procedure is contraindicated in thin gingival areas because the removal of pigmented gingival epithelium with the thin gingival biotype can result in gingival recession^(10,11).

Split thickness epithelial excision is another name for the scalpel surgical method. The traditional scalpel procedure entails surgical removal of gingival epithelium with a 15-blade sized scalpel^(10,11).

The most ideal condition for performing the surgical method is thick gingival biotype. In order to decrease the recurrence rate, enough gingival tissue thickness must be removed. Even in thicker gingival biotypes, the marginal and interdental papillary tissues are essential to be preserved. The biotype of these areas is not always the same as the biotype of the remaining gingival tissues⁽¹²⁾.

Various types of lasers, particularly diode lasers which are soft tissue lasers, have been used for gingival depigmentation. When energy is delivered

in the presence of a pigment, the laser develops a unique affinity for melanin or dark pigments and performs better giving better results. During or after surgery, there are no indicators of discomfort, pain, or bleeding⁽¹²⁻¹⁴⁾.

Lasers are good for gingival depigmentation because they penetrate deeply and are absorbed easily by the melanin. The diode laser's profound thermal impact causes unintended irradiation, which blocks blood capillaries in the surrounding tissue, potentially delaying melanocyte migration. A hot tip, created by heat accumulation at the fiber's end, causes the thermal effect of a diode laser. Furthermore, pigment-containing cells such as melanophages and melanophores that have become lodged in the lamina propria might absorb the diode laser, delaying re-pigmentation.⁽¹⁵⁻¹⁷⁾

Topically applied, trans-dermally, or intravenously injected vitamin C (ascorbic acid) are some of the methods that are utilized in skin depigmentation. Both immune and host cells require vitamin C, for nutrition. Collagen synthesis, photoprotection, skin layer strengthening, melanin reduction, free radical scavenging, and immune system augmentation are all stimulated by vitamin C (L-ascorbic acid)^(12,18).

Vitamin C, often known by its chemical name ascorbic acid (AA), is a water-soluble antioxidant that is lost in substantial amounts during food preparation. AA plays an essential role in the maturation and maintenance of bones, ligaments, gums, teeth and blood vessels, as well as other metabolic functions. In healthy adults, the daily essential dose of AA is (40–60) mg⁽¹⁹⁾.

Because of its direct effect on melanogenesis, vitamin C has been proven to be beneficial in depigmentation. Melanin is thought to operate as a storage site for reactive oxygen species (ROS), copper (Cu), and calcium (Ca) in cells. It interacts with the copper (Cu) ions at the tyrosinase active

site after entering the target tissue, thus inhibiting the enzyme tyrosinase and lowering melanin production. This results in a lack of ROS, Cu, and Ca, which then reduces melanin formation because calcium is required for the formation of Cadherins, So a calcium deficit causes the failure of melanocytes to form cellular attachment to keratinocytes. This attachment to keratinocytes acts as a stimulator for melanocytes, causing them to produce melanin, and transfer the produced melanin to adjacent cells, So the failure of this attachment causes the stopping of the melanogenesis process and reducing the amount of melanin produced, and thus aiding in the treatment of gingival hyperpigmentation^(20,21).

SUBJECT AND METHODS

Patients Selection:

This study was performed on 30 patients selected from the Outpatient Clinic, Department of Oral Medicine, Periodontology and Diagnosis, Faculty of Dentistry, Al-Azhar University (Girls Branch), Cairo Egypt. The study population consisted of age-matched patients. The technique was prescribed each patient in detail. A written consent was signed for each included participant who agreed to participate voluntarily prior to the start of the study. The research design was approved by the Ethics Committee, Faculty of Dentistry, and Al-Azhar University. Approval number is REC-ME-21-04.

Patients were chosen based on the following inclusion criteria: Subjects with physiologic hyperpigmentation of the gingiva in the aesthetic zone (anterior labial area), Subjects seeking for esthetic improvement, Age between 20 and 35 years old, Periodontally healthy subjects and good oral hygiene, Subjects who have high and very high smile line. Patients who were excluded are former and current smokers, Patients with compromised systemic health, pregnant and/or lactating women, and gingival pigmentation due to other causes than physiologic pigmentation⁽²²⁾.

Sample Calculation:

Power calculation test was performed, setting an effect size = 0.80, $\alpha = 0.05$, and a power at 80%. The sample size calculation showed a requirement for 8 subjects per group. Accordingly, at the present study, 10 subjects will recruit per group, Subjects will be divided randomly into 3 different groups according to the treatment regimen of gingival de-pigmentation⁽²³⁾. **Group I, (Surgical group):** Will consist of 10 patients and will be treated by the scalpel surgical technique, **Group II, (Laser group):** Will consist of 10 patients and will be treated by soft-tissue diode laser with wavelength range 810–980 nm, **Group III, (vit. C group):** Will consist of 10 patients and will be treated by the injection of Vitamin C.

Clinical Evaluation: Clinical evaluation was performed at baseline, 15 days, 30 days and 90 days intervals, to record the following: Calculation of surface area of gingival pigmentation and re-pigmentation as described by Perlmuter 1986, Calculation of darkness value of gingiva using Image J intensity values, Visual Analogue scale (VAS), for pain and patient satisfaction, was assessed at 7th, 10th, and 15th day of the operation⁽²³⁾.

Calculation of the surface area of gingival pigmentation and re-pigmentation as described by Perlmuter 1986 was performed through measuring the height of the hyper pigmented gingival tissue and width of the hyper pigmented gingival tissues before the procedure and measuring the re-pigmented areas if present at the follow-up periods, using the periodontal probe for accurate measurements⁽²⁴⁾.

The darkness intensity values were measured using an image analysis software called Image-J using standardized photographs. The total surface area from maxillary canine to canine was measured. The measurement of the intensity of the pigmentation is based on the image histogram by the software expressed in mean grey scale values

from 0-255.2. Comparison of the values were performed using pre operative and post operative standardized photographs to detect the difference in the gingival darkness intensity value at baseline and then at 15 days, 30 days and 90 days thus indicating the result of the depigmentation process in regards to decreasing the darkness intensity value and removing the gingival hyperpigmentation⁽²³⁾.

Statistical Analysis:

The different clinical, parameters for all subjects at all groups will be analyzed statistically using student t test and ANOVA test.

Pre-surgical preparation:

After patient selection, initial periodontal treatment consisted of scaling using ultrasonic instruments was performed prior to any procedures. Then routine records of all the patients such as recording the pre-treatment calculation of the surface area of the gingival pigmentation, extra oral and intra oral photographs, have been done pre-operatively for every patient. The calculation of the surface area of the gingival pigmentation was carried out using the periodontal probe to measure the height and the width of the pigmented surface related to each tooth in the anterior aesthetic zone as in (Figure 1, and 2).

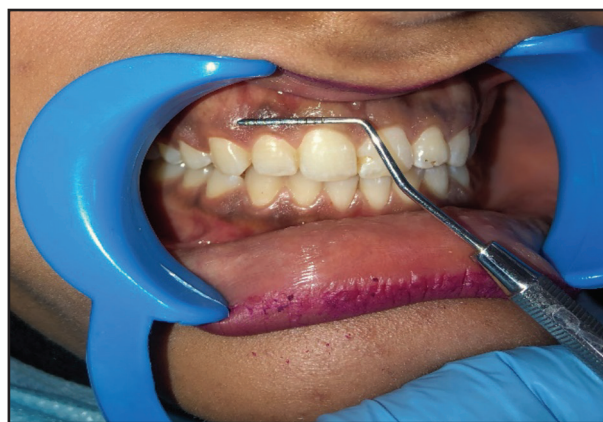

Figure (1) Measuring the width of the pigmented tissue

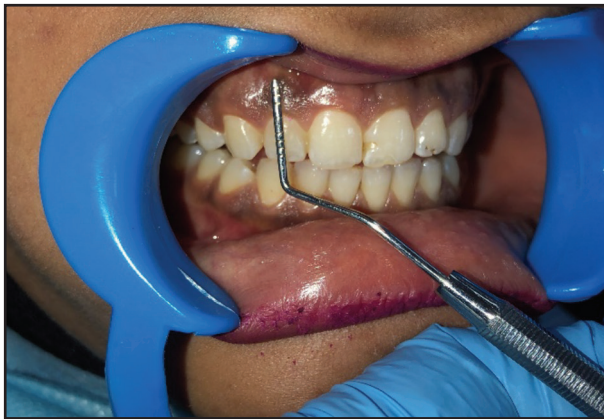

Figure (2) Measuring the height of the pigmented tissue

Surgical Phase:

Group A (Surgical group): Six maxillary and mandibular anterior teeth were infiltrated with 4 % Articaine hydrochloride as a topical anesthetic. The pigmented gingival epithelium, as well as a layer of the underlying connective tissue, were surgically removed using a disposable surgical blade #15c, as indicated in (Fig. 3).

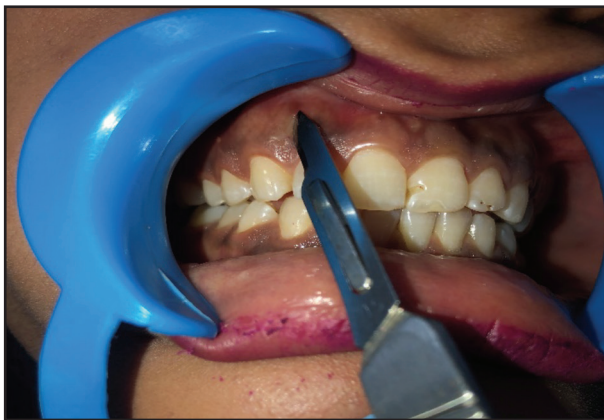

Figure (3) Showing the scalpel used for removal of gingival epithelium

From the distal surface of the last tooth in the aesthetic zone on the right side to the distal side of the last tooth in the aesthetic zone on the left side, the scalpel was employed. The mandibular arch was surgically excised as well from canine to canine.

Bleeding was managed by applying pressure using sterile gauze. Post-surgical instructions were given to the patient, all patients were monitored^(14,25,26).

Group B (Laser group): Six maxillary and mandibular anterior teeth were infiltrated with 4% Articaine hydrochloride as a topical anesthetic. Protection goggles were worn by both the patient and the surgical crew. Depigmentation was done with the K2 Mobile portable laser unit from the HULaser firm in Korea. The laser utilized was a diode laser with a wavelength of 980 nm and a power of 1.0 W. The laser beam's emission mode is continuous beam cutting, as indicated in (Fig. 4). The ablation in the maxillary arch began at the distal surface of the last tooth in the aesthetic zone on the right side and progressed to the distal surface of the last tooth in the aesthetic zone on the left side. The mandibular arch was ablated from canine to canine as well⁽²⁷⁻²⁹⁾.

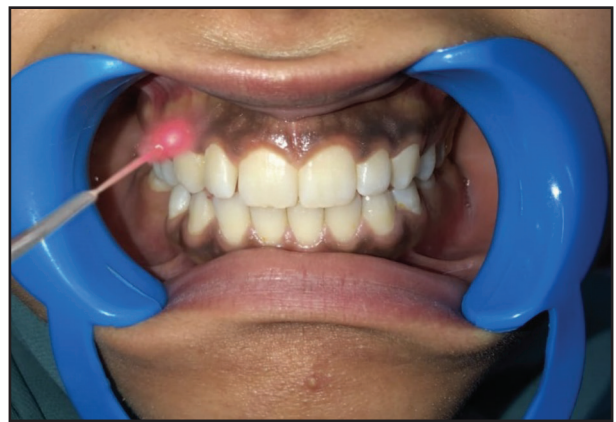

Figure (4) Showing the direction of the laser beam.

Group C (Vit. C group): Six maxillary and mandibular anterior teeth received topical anesthetic infusion of 4% Articaine hydrochloride in the muco-buccal fold. In the upper and lower arches, 1.5mL (200-300mg concentration) of L-ascorbic acid (Pascorbin – Ascorbic Acid by Pascoe company-Germany) were injected into the gingiva. Using a 30-gauge needle, it was introduced locally in

connection to the keratinized gingival tissue, with expansion throughout the entire aesthetic region in the maxillary and mandibular arch. With the bevel facing upwards the needle was inserted parallel to the tissues. Vit C was injected into the epithelium-connective tissue junction until the tissues blanched, as indicated in (Fig. 5). Each point received a maximum of 0.1 ml of ascorbic acid, spaced 2-3 mm apart. The same dosage was given once a week for a total of four visits, or until no more color improvement was noticed. Post-surgical instructions were given to the patient, all patients were closely monitored⁽¹²⁾.

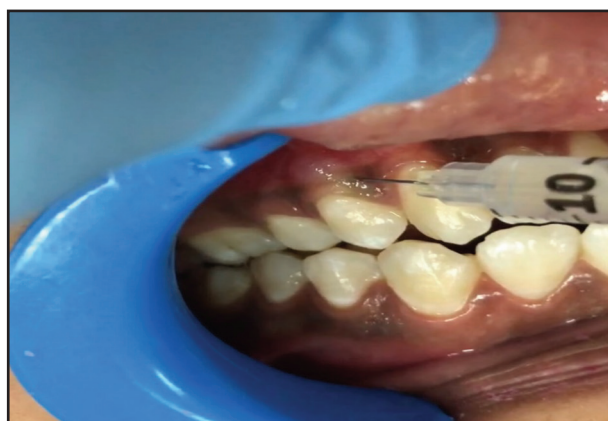

Figure (5) Showing the direction of the needle and blanching of the tissues.

RESULT

In the present research, 30 healthy individuals aged 20 to 30 years were enrolled. They were split into three groups, each with ten patients. Group A was treated using surgical excision, Group B was treated using diode soft tissue laser and Group C was treated using gingival injection of vit C for gingival hyperpigmentation. All the patients completed the study and all were satisfied with the new healthy gingival look.

Clinical evaluation was performed at baseline, 15 days, 30 days, and 90 days intervals, which included Calculation of surface area of gingival

pigmentation and re-pigmentation as described by Perlmuter 1986 and Calculation of darkness value of gingiva using Image J intensity values. Visual Analogue Scale (VAS) was assessed at 7th, 10th and 15th day of the depigmentation procedures.

As regards to mean values of darkness intensity for the group A (scalpel group) at base line, it recorded 232.960 ± 23 , and after 15 days of the operation it recorded 210.762 ± 46 . At 30 and 90 days intervals it recorded 205.119 ± 77 and 203.645 ± 59 respectively. The gingiva is shown at baseline and after the 90 days follow up as shown in (Fig. 6) and (Fig. 7) respectively. There was a significant statistical difference only between the baseline records and 15-day intervals. ($p=0.005$) as shown in (Fig. 8).

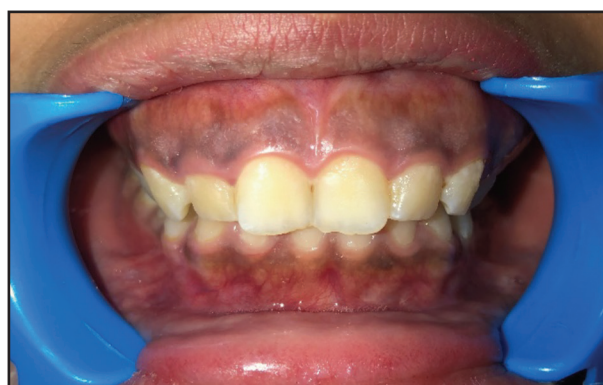

Figure (6) Showing Baseline for (Surgical group)

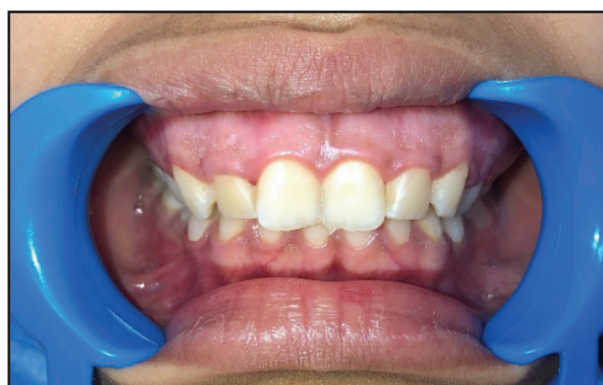

Figure (7) Showing 90 days follow-up for (Surgical Group)

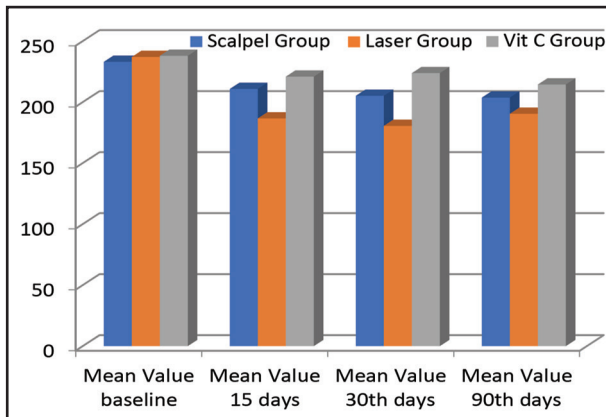


Figure (8) Showing the difference in the mean darkness values.

Group B (Laser group) at 15 days interval showing better records when compared with the base line records, where it records 236.960 ± 59 at base line and 186.570 ± 87 at 15 days interval. The improvement of the grey scale was continued till 30 days interval, where it recorded 180.45 ± 74 , and at the end of the study it recorded 190.367 ± 27 as shown in (Fig. 11). The gingiva is shown at baseline and after the 90 days follow up as shown in (Fig. 9) and (Fig. 10) respectively. There was a statistically significant difference only between the baseline records and 15 days intervals ($p=0.005$) as shown in (Fig. 11).

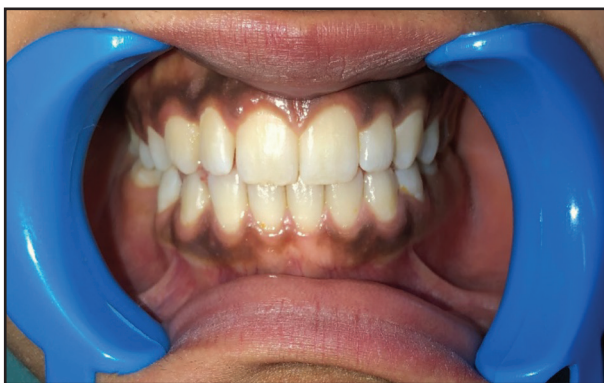

Figure (9) Showing Baseline for (Laser group)

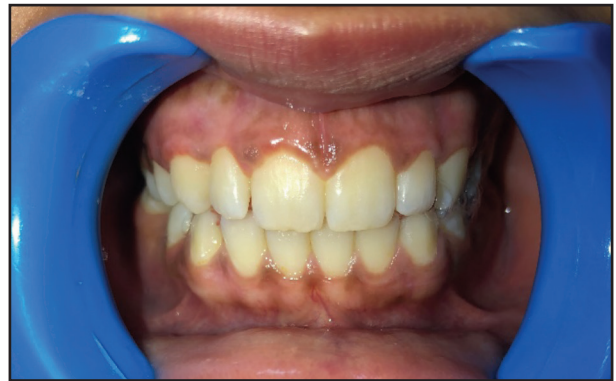

Figure (10) Showing 90 days follow-up for (Laser group)

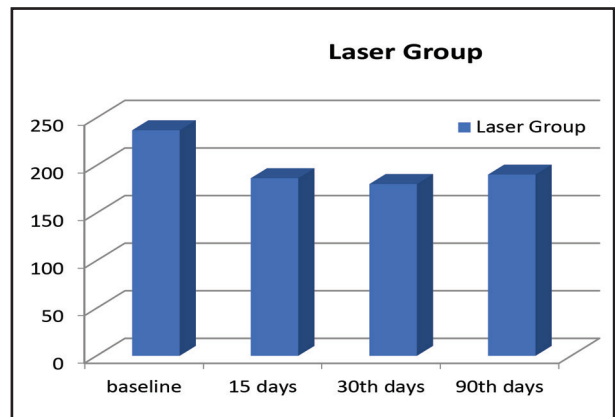


Figure (11) Showing darkness value intensity for the laser group

As regards to the mean grey scale value for the Vit. C group (group c) it was recorded 237.910 ± 26 at base line, and 220.830 ± 92 , 223.7 ± 67 and 214.37 ± 53 at 15, 30 and 90 days intervals respectively. The gingiva is shown at baseline and after the 90 days follow up as shown in (Fig. 12) and (Fig. 13) respectively. There was no statistically significant difference between the four follow-up intervals. ($p=0.005$) as shown in (Fig. 14).

When comparing the mean values of darkness intensity of the gingiva between all the three groups at base line, there was no statistically significant difference between the groups. While at 15 days intervals there was a statistically significant difference between all the examined groups, on which the laser group recorded the lowest darkness intensity values. These decreased values recorded at 15 days interval continued until the end of the study.

As regard to pain and discomfort evaluation recorded by VAS, only 5 patients operated with scalpel at group A complained of moderate pain at 15 days interval but patients treated with diode laser and vit c injection, showing only slight or no pain. However, the pain almost diminished 1 week after the surgery.

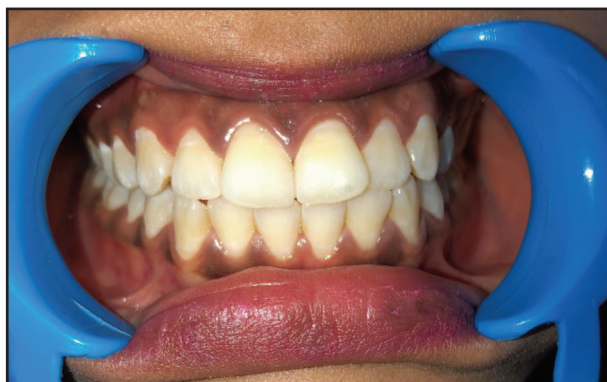

Figure (12) Showing Baseline for (Vit C group) Figure

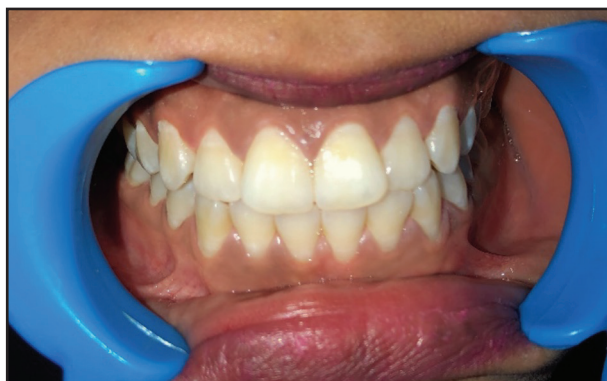

Figure (13) Showing 90 days follow-up for (Vit C group)

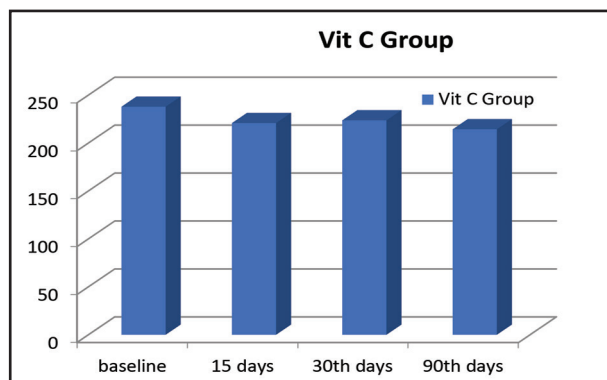


Figure (14) Showing darkness intensity values for Vit C group.

DISCUSSION

A smile can convey a variety of emotions, including enjoyment, success, confidence, and kindness. The gingival tissues, especially in those with gummy smiles, have a role in the harmony of the smile, along with the shape, location, and color of the teeth and lips. The majority of patients with gingival hyperpigmentation regards it as an aesthetic issue⁽⁷⁾.

The purpose of this study was to compare and evaluate the efficacy of three distinct gingival depigmentation techniques: scalpel surgery, laser therapy, and vitamin C injection. The current study included 30 patients with aesthetic zone gingival hyperpigmentation who were seeking treatment for their hyperpigmented gingiva. Patients were chosen based on a set of precise inclusion and exclusion criteria. The selected patients ranged in age from 20 to 35 years old. A patient over the age of 20 can comprehend the depigmentation methods as well as the vocal and written instructions^(28,30).

Patients who practiced smoking were not a part of the trial because smoking causes melanocytes to become activated and produce melanin when stimulated. Nicotine and benzopyrenes are polycyclic amines that have been shown to enter the oral mucosa and cohere to melanin as a result of smoking. This melanin hyperpigmentation has been referred to as "smoker's melanin"^(28,30).

Pain after surgery is a complicated phenomenon that is influenced by some variables such as psychological, environmental, and physical variables. In comparison to the spoken rating scale, the visual analogue scale (VAS) is a more reliable and trusted way to assess pain in clinical situations. The VAS was employed in this study to assess each patient's subjective pain level. It consists of a simple flat line ranging from 0 to 10, starting at the left side ending with "no pain" and ending at the right ending with "worst severe pain." Patients were asked to rate the degree of their pain on a scale of one to ten⁽³¹⁾.

Only 5 patients who were operated on with a scalpel reported moderate discomfort 15 days later, whereas patients who were treated with a diode laser and vitamin C injection had only minor or no pain. The coagulation of the protein on the wound surface, served as a biological wound cover and blocked the endings of sensory nerves, which is likely to be the cause of laser groups of patients having minor pain⁽³⁰⁾. The current findings were consistent with those of a study conducted in 2018 that examined the pain levels of scalpel and diode laser patients and found that the diode laser group had much less pain than the scalpel group⁽²⁸⁾, also according to another study conducted in 2017, It was found that during the first week after the procedure, the patients on the side treated with the scalpel approach experienced more discomfort/pain than the diode laser-treated side^(32,33).

The current study found that vitamin C when injected intramucosal which is also identified as mesotherapy technique is an effective, and patient-pleasing non-aggressive non-surgical approach for gingival depigmenting which blocks important stages of melanogenesis. In vivo and vitro experiments conducted in 2019, came to similar conclusions, which were extensively noted in dermatology^(12,34).

Oral re-pigmentation which is the return of melanin pigment to the oral mucosa following a duration of clinical depigmentation⁽⁴⁾. The process of re-pigmentation is unknown and poorly understood; however, the migration idea would suggest that the active melanocytes from the adjacent pigmented tissues would migrate to the previously treated areas, thus resulting in failure. Re-pigmentation studies are few and far between⁽³¹⁾.

When evaluated frequently for up to 3 months, it was discovered that surgical scalpel, diode laser, and Ascorbic acid injection methods offered equal results in terms of successful elimination of gingival pigmentation and no recurrence of the pigment in all 3 groups⁽³⁴⁾.

With laser and surgical procedures, Studies conducted in 2009 and 2011 reported no recurrence after 3 months. In 2012 and 2020 other studies matched those of our investigation⁽³⁵⁾.

The findings of this study are similar to those of other studies in which a placebo-controlled clinical experiment was conducted to confirm the possible role of ascorbic acid in the treatment of gingival melanin pigmentation. In their case report study, these studies also demonstrated the complementary role of vitamin C in conjunction with surgical scalpel excision^(12,21,36).

CONCLUSION

Gingival hyperpigmentation can be an aesthetic concern to many patients. The current study found that the aesthetic results of these three different approaches were efficient, with the laser approach having more superior results regarding the reduced post-operative pain. After 3 months of follow-up, there was no trace of re-pigmentation in any of the groups, and there was a substantial difference in the darkness intensity values in all of them when measured using ImageJ program which indicates a successful treatment in removing the hyperpigmentation thus reducing the darkness value of the gingiva.

RECOMMENDATION

It is recommended to prolong the follow up period specially in the laser and Vitamin C group up to one year to detect more accurate results regarding the re-pigmentation and darkness intensity values.

CONFLICT OF INTEREST

The Author declared that there is no conflict of interest.

FUNDING

No fund was received for this study.

REFERENCES

- Farid H, Shinwari M, Khan FR, Tanwir F. Journey from black to pink gums: management of melanin induced physiological gingival hyper pigmentation. *J Ayub Med Coll Abbottabad*. 2017; 29: 132-8.
- Abdel Moneim RA, El Deeb M, Rabea AA. Gingival pigmentation (cause, treatment and histological preview). *Futur Dent J*. 2017; 3: 1-7.
- Rakhewar PS, Patil HP, Thorat M. Identification of gingival pigmentation patterns and its correlation with skin color, gender and gingival phenotype in an Indian population. *Indian J Multidiscip Dent*. 2016; 6: 87-92.
- Pai A, Prasad S, Patil BA, Dyasanoor S, Hedge S. Oral pigmentation. case report and review of malignant melanoma with flow charts for diagnosis and treatment. *Gen Dent*. 2012; 60: 410-6.
5. Pakhare VV, Bajaj P, Bhongade ML, Shilpa BS. Gingival depigmentation by free gingival autograft: a case series. *Dent. Update*. 2017; 44: 1012968.
- Patil KP, Joshi V, Waghmode V, Kanakdande V. Gingival depigmentation: A split mouth comparative study between scalpel and cryosurgery. *Contemp Clin Dent*. 2015; 6: 97-101.
- Suchetha A, Shahna N, Divya Bhat, Apoorva S, Sapna N. A review on gingival depigmentation procedures and re-pigmentation. *Int J Appl Dent Sci*. 2018; 4: 336-341.
- Lesly D, Ayala O, Cantos Tello PM, Endara Carvajal AS. Gingival Melanosis: Diagnosis and Therapy of Its Aesthetic Involvement. Literature Review. *Int J Dent Sc*. 2021; 23: 1015517.
- Gautam A, Raaj V, Singh M, Anusha. Gingival depigmentation to enhance esthetics by two different modalities. *Indian J Multidiscip Dent* .2015; 5: 91-3.
- Jain SK, Shenoy N, Chourasia MK, et al. A comparative clinical study on surgical blade and diode laser in the treatment of gingival melanin pigmentation. *J Evolution Med Dent Sci*. 2021;10: 689-693.
- Alasmari DS. An insight into gingival depigmentation techniques: The pros and cons. *Int J health sci. (Qassim)*. 2018;12: 84-9.
- Yussif NM, Abdel Rahman AR, ElBarbary A. Minimally invasive non-surgical locally injected vitamin C versus the conventional surgical depigmentation in treatment of gingival hyperpigmentation of the anterior esthetic zone: A prospective comparative study. *Clin Nutr Exp*. 2019;24: 54-65.
- Muruppel AM, Pai J, Bhat S, Parker S, Lynch E. Laser-Assisted Depigmentation—An Introspection of the Science, Techniques, and Perceptions. *J Dent*. 2020; 8: 103390.
- Malhotra S, Sharma N, Basavaraj P. Gingival Esthetics by Depigmentation. *J periodontal med clin pract*. 2014;1: 79-84.
- Altayeb W, Hamadah O, Alhaffar BA, Abdullah A, Romanos G. Gingival depigmentation with diode and Er,Cr:YSGG laser: evaluating re-pigmentation rate and patient perceptions. *Clin Oral Investig*. 2021;25: 5351-61.
- Booley AB, Peerbhay F, Mulder R, Mulder-van Staden S. The use of a digitally pulsed, high power diode laser for the treatment of physiological gingival pigmentation. *S Afr Dent J*. 2018; 73: 245-8.
- Suragimath G, Lohana MH, Varma S. A Split mouth randomized clinical comparative study to evaluate the efficacy of gingival depigmentation procedure using conventional scalpel technique or Diode Laser. *J Lasers Med Sci*. 2016; 7: 227-232.
- Sanadi RM, Deshmukh RS. Vitamin C as a non-surgical gingival depigmentation agent – case study. *Med. Res. Chronicle*. 2021; 8: 74-8.
- Sanadi RM, Deshmukh RS. The effect of Vitamin C on melanin pigmentation – A systematic review. *J Oral Maxillofac Pathol*. 2020; 24: 374-382.
- Ravetti S, Clemente C, Brignone S, Hergert L, Allemandi D, Palma S. Ascorbic Acid in Skin Health. *Cosmetics*. 2019; 6: 103390.
- Sheel V, Purwar P, Dixit J, Rai P. Ancillary role of vitamin C in pink aesthetics. *BMJ Case Rep*. 2015; 2015: 101136.
- Abdelmagyd HAE, Al-Ahmari MMM, Shetty SR. Treatment of gingival hyperpigmentation using different techniques *J Datta Meghe Inst Med Sci Univ*. 2019; 14: 50-5.
- Rahman AR, Pratebha B, Jananni M, Saravanakumar R. Comparison of efficacy of depigmentation of gingiva in terms of ImageJ intensity values and surface area of repigmentation using scalpel and diode laser. *Indian J Dent Sci*. 2016; 6: 59-64.
- Perlmutter S, Tal H. Repigmentation of the gingiva following surgical injury. *J Periodontol*. 1986; 57 :48-50.
- ALHabashneh R, Darawi O, Khader YS, Ashour L. Gingival depigmentation using ER: YAG laser and scalpel technique: A six-month prospective clinical study. *Quintessence Int*. 2018; 49: 113-122.

26. Manickam P, Aspalii S, Mulla SA, Deoprasakam P. The reconstruction of pink esthetics through gingival depigmentation- a case series. *Acta sci dent sci* 2020; 3: 1031080.
27. Singh DK, Mandal A. Management of gingival pigmentation using laser depigmentation technique *J Prim Care Dent Oral Health*. 2021; 2: 81-4.
28. Vassoler F, Margo ED, Margo AK, Delacerda RRP, Paranhos LR, Santos PL, et al. Gingival melanin depigmentation with diode laser - case report. *Int Odontostomatol*. 2019;13: 481-5.
29. Pavlic V, Brkic Z, Marin S, Cicmil S, Gojkovic-Vukelic M, Aoki A. Gingival melanin depigmentation by Er:YAG laser: A literature review. *J Cosmet Laser Ther*. 2018;20: 85-90.
30. Bin Muharib, Sarah I, Allmasoud, Atheer A. Different surgical techniques for gingival depigmentation and their outcomes. A literature review. *Int J Med Dent*. 2020; 24: 607-11.
31. Ipek H, Kirtiloglu T, Diraman E, Acikgoz G. A comparison of gingival depigmentation by Er:YAG laser and Kirkland knife: osmotic pressure and visual analog scale. *J Cosmet. Laser Ther*. 2019; 21: 209-212.
32. Houshmand B, Janbakhsh N, Khalilian F, Ardakani MRT. Efficacy of Conventional Laser Irradiation Versus a New Method for Gingival Depigmentation (Sieve Method): A Clinical Trial. *J Lasers Med Sci*. 2017; 8: 88-94.
33. Agha MT, Polenik P. Laser Treatment for Melanin Gingival Pigmentations: A Comparison Study for 3 Laser Wavelengths 2780, 940, and 445 nm. *Int J Dent*. 2020; 101155.
34. Grover HS, Dadlani H, Bhardwaj A, Yadav A, Sanjay L. Evaluation of patient response and recurrence of pigmentation following gingival depigmentation using laser and scalpel technique: A clinical study. *J Indian Soc Periodontol*. 2014; 18: 586-592.
35. Chandra GB, VinayKumar MB, Walavalkar NN, Vandana KL, Vardhan PK. Evaluation of surgical scalpel versus semiconductor diode laser techniques in the management of gingival melanin hyperpigmentation: A split-mouth randomized clinical comparative study. *J Indian Soc Periodontol*. 2020; 24: 47-53.
36. El-Mofty M, Elkot, S, Ghoneim A, Yossri D, Ezzatt OM. Vitamin C mesotherapy versus topical application for gingival hyperpigmentation: a clinical and histopathological study. *Clin Oral Investig*. 2021: 101007.